National Comprehensive Cancer Network®

NCCN Clinical Practice Guidelines in Oncology (NCCN Guidelines®)

Cervical Cancer

Version 2.2026 — November 10, 2025

NCCN.org

NCCN recognizes the importance of clinical trials and encourages participation when applicable and available. Trials should be designed to maximize inclusiveness and broad representative enrollment.

NCCN Guidelines for Patients® available at www.nccn.org/patients

Version 2.2026, 11/10/25 © 2025 National Comprehensive Cancer Network® (NCCN®), All rights reserved. NCCN Guidelines® and this illustration may not be reproduced in any form without the express written permission of NCCN.

PLEASE NOTE that use of this NCCN Content is governed by the End-User License Agreement, and you MAY NOT distribute this Content or use it with any artificial intelligence model or tool.
Printed by Galya Basol Kochav on 12/29/2025 12:47:39 PM. Copyright © 2025 National Comprehensive Cancer Network, Inc. All Rights Reserved.

***Nadeem R. Abu-Rustum, MD Ω/Chair**
Memorial Sloan Kettering Cancer Center

***Susana M. Campos, MD, MPH, MS †/ Vice Chair**
Dana-Farber/Brigham and Women's Cancer Center

Sudha Amarnath, MD §
Case Comprehensive Cancer Center/ University Hospitals Seidman Cancer Center and Cleveland Clinic Taussig Cancer Institute

Rebecca Arend, MD Ω
O'Neal Comprehensive Cancer Center at UAB

Emma Barber, MD Ω
Robert H. Lurie Comprehensive Cancer Center of Northwestern University

Kristin Bradley, MD §
University of Wisconsin Carbone Cancer Center

Rebecca Brooks, MD Ω
UC Davis Comprehensive Cancer Center

Junzo Chino, MD §
Duke Cancer Institute

Hye Sook Chon, MD Ω
Moffitt Cancer Center

Marta Ann Crispens, MD Ω
Vanderbilt-Ingram Cancer Center

Shari Damast, MD §
Yale Cancer Center/ Smilow Cancer Hospital

Christine M. Fisher, MD, MPH §
University of Colorado Cancer Center

Peter Frederick, MD Ω
Roswell Park Comprehensive Cancer Center

David K. Gaffney, MD, PhD §
Huntsman Cancer Institute at the University of Utah

Stephanie Gaillard, MD, PhD †
Johns Hopkins Kimmel Cancer Center

Robert Giuntoli II, MD Ω
Abramson Cancer Center at the University of Pennsylvania

Scott Glaser, MD §
City of Hope National Medical Center

Brooke E. Howitt, MD ≠
Stanford Cancer Institute

Kari Kendra, MD, PhD †/Liaison
The Ohio State University Comprehensive Cancer Center - James Cancer Hospital and Solove Research Institute

Lisa Landrum, MD, PhD Ω
Indiana University Melvin and Bren Simon Comprehensive Cancer Center

Jayanthi Lea, MD Ω
UT Southwestern Simmons Comprehensive Cancer Center

Nita Lee, MD, MPH Ω
The UChicago Medicine Comprehensive Cancer Center

Gina Mantia-Smaldone, MD Ω
Fox Chase Cancer Center

Andrea Mariani, MD Ω
Mayo Clinic Comprehensive Cancer Center

David Mutch, MD Ω
Siteman Cancer Center at Barnes-Jewish Hospital and Washington University School of Medicine

Christa Nagel, MD Ω
The Ohio State University Comprehensive Cancer Center - James Cancer Hospital and Solove Research Institute

Larissa Nekhlyudov, MD, MPH Þ
Dana-Farber/Brigham and Women's Cancer Center

Chika Nwachukwu, MD, PhD §
UC San Diego Moores Cancer Center

Mirna Podoll, MD ≠
Vanderbilt-Ingram Cancer Center

Kerry Rodabaugh, MD Ω
Fred & Pamela Buffett Cancer Center

Ritu Salani, MD, MBA Ω
UCLA Jonsson Comprehensive Cancer Center

John Schorge, MD Ω
St. Jude Children's Research Hospital/ The University of Tennessee Health Science Center

Scott Schuetze, MD, PhD †
University of Michigan Rogel Cancer Center

Jean Siedel, DO, MS Ω
University of Michigan Rogel Cancer Center

Pamela Soliman, MD, MPH Ω
The University of Texas MD Anderson Cancer Center

Stefanie Ueda, MD Ω
UCSF Helen Diller Family Comprehensive Cancer Center

Renata Urban, MD Ω
Fred Hutchinson Cancer Center

Emily Wyse ¥
Patient Advocate

NCCN
Nicole McMillian, MS
Vaishnavi Sambandam, PhD

Ω Gynecologic oncology	§ Radiotherapy/Radiation oncology
Þ Internal medicine	*Discussion Section Writing Committee
† Medical oncology	
≠ Pathology	
¥ Patient advocacy	

NCCN Guidelines Panel Disclosures

Version 2.2026, 11/10/25 © 2025 National Comprehensive Cancer Network® (NCCN®), All rights reserved. NCCN Guidelines® and this illustration may not be reproduced in any form without the express written permission of NCCN.

PLEASE NOTE that use of this NCCN Content is governed by the End-User License Agreement, and you MAY NOT distribute this Content or use it with any artificial intelligence model or tool.
Printed by Galya Basol Kochav on 12/29/2025 12:47:39 PM. Copyright © 2025 National Comprehensive Cancer Network, Inc. All Rights Reserved.

NCCN Cervical Cancer Panel Members
Summary of the Guidelines Updates

Cervical Cancer
For cervical cancer screening refer to the American Society for Colposcopy and Cervical Pathology (ASCCP) Guidelines for Cervical Cancer Screening (Mobile app available): https://www.asccp.org/clinical-practice/guidelines/screening-guidelines

Workup, Clinical Stage (CERV-1)
Stage IA1 (no LVSI), Stage IA1 (with LVSI), Stage IA2–IB1 (no LVSI), Stage IB1 Not Meeting Conservative Surgery Criteria and Select IB2 (Fertility Sparing) (CERV-2)
Stage IA1 (no LVSI), Stage IA1 (with LVSI Based on Cone/LEEP) (Non-Fertility Sparing) (CERV-3)
Stage IA2–IB1 (Conservative Surgery Criteria Met) (Non-Fertility Sparing) (CERV-4)
Stage IB1 Not Meeting Conservative Surgery Criteria, Stage IB2, and Stage IIA1 (Non-Fertility Sparing) (CERV-5)
Stage IB3 and Stage IIA2 (Non-Fertility Sparing) (CERV-5)
Surgical Findings, Adjuvant Treatment (CERV-6)
Stage IIB–IVA (CERV-7)
Incidental Finding of Invasive Squamous or Usual Type Adenocarcinoma After Simple/Total Hysterectomy (CERV-8) and (CERV-9)
Surveillance (CERV-10)
Locoregional Recurrence (CERV-11)
Stage IVB or Recurrence with Distant Metastases (CERV-12)

Small Cell Neuroendocrine Carcinoma of the Cervix (NECC), Primary Workup (CERV-13)
Small Cell NECC, Locally Advanced Disease (IIA–IVA) (CERV-14)

Principles of Pathology (CERV-A)
Principles of Imaging (CERV-B)
Principles of Evaluation and Surgical Staging (CERV-C)
Principles of Radiation Therapy (CERV-D)
GOG/Sedlis Criteria for External Pelvic Radiation After Radical Hysterectomy In Node-Negative, Margin-Negative, Parametria-Negative Cases (CERV-E)
Systemic Therapy for Cervical Cancer (CERV-F)
Principles of Gynecologic Survivorship (CERV-G)

Staging (ST-1)

Abbreviations (ABBR-1)

The NCCN Guidelines for Cervical Cancer include the management of squamous cell carcinoma, adenosquamous carcinoma, adenocarcinoma of the cervix, and small cell neuroendocrine carcinoma of the cervix.

Find an NCCN Member Institution: https://www.nccn.org/home/member-institutions.

NCCN Categories of Evidence and Consensus: All recommendations are category 2A unless otherwise indicated.

See NCCN Categories of Evidence and Consensus.

NCCN Categories of Preference: All recommendations are considered appropriate.

See NCCN Categories of Preference.

The NCCN Guidelines® are a statement of evidence and consensus of the authors regarding their views of currently accepted approaches to treatment. Any clinician seeking to apply or consult the NCCN Guidelines is expected to use independent medical judgment in the context of individual clinical circumstances to determine any patient's care or treatment. The National Comprehensive Cancer Network® (NCCN®) makes no representations or warranties of any kind regarding their content, use or application and disclaims any responsibility for their application or use in any way. The NCCN Guidelines are copyrighted by National Comprehensive Cancer Network®. All rights reserved. The NCCN Guidelines and the illustrations herein may not be reproduced in any form without the express written permission of NCCN. ©2025.

PLEASE NOTE that use of this NCCN Content is governed by the End-User License Agreement, and you MAY NOT distribute this Content or use it with any artificial intelligence model or tool.
Printed by Galya Basol Kochav on 12/29/2025 12:47:39 PM. Copyright © 2025 National Comprehensive Cancer Network, Inc. All Rights Reserved.

Updates in Version 2.2026 of the NCCN Guidelines for Cervical Cancer from Version 1.2026 include:

Erratum on CERV-3 published 11/19/25
- Stage IA1 no LVSI; Positive margins for dysplasia or carcinoma and medically operable after Cone biopsy: Primary Treatment (Non-Fertility Sparing) option corrected as follows: Type A hysterectomy (if margins positive for dysplasia) ~~+ SLN mapping or pelvic lymphadenectomy.~~

CERV-F 1A of 4
- Footnote g revised: ~~Testing for dihydropyrimidine dehydrogenase (DPYD) genetic variants should be considered prior to fluoropyrimidine therapy. After discussions regarding risk assessment, patients may choose DPYD genetic testing. However, no specific test is recommended at this time and there are insufficient data to inform dose adjustments for many of the DPYD variants. See DPYD Testing and Fluoropyrimidine-Associated Toxicity Discussion section in the NCCN Guidelines for Colon Cancer for more information.~~ *For information regarding dihydropyrimidine dehydrogenase (DPYD) testing, see the NCCN Guidelines for Colon Cancer.*

Updates in Version 1.2026 of the NCCN Guidelines for Cervical Cancer from Version 4.2025 include:

Table of Contents
- New statement added: For cervical cancer screening refer to the American Society for Colposcopy and Cervical Pathology (ASCCP) Guidelines for Cervical Cancer Screening (Mobile app available): https://www.asccp.org/clinical-practice/guidelines/screening-guidelines

CERV-1
- Workup
  - 9th Bullet revised: Consider examination under anesthesia (EUA) cystoscopy/proctoscopy (~~≥ stage IB3~~ *based on symptoms, barrel-shaped lesions, or anterior vaginal involvement*)
  - New bullet added: Assess for distress
  - Footnote d revised to include a link to the NCCN Guidelines for Cancer in People with HIV.
  - Footnote f is new: Refer to the NCCN Distress Thermometer and Problem List, which includes social determinants of health. See NCCN Guidelines for Distress Management (DIS-A).

CERV-2
- Stage IA2–IB1 (based on cone biopsy and all conservative surgery criteria must be met) bullets revised as follows:
  - 1st Bullet: No LVSI *(preferred)* (Also for CERV-4)
  - 2nd Bullet: Negative cone margins *for cancer* (Also for CERV-4)
  - 3rd bullet: Squamous cell (any grade) or usual type adenocarcinoma (grade 1 or 2 only) *(preferred)*
- New pathway added for Stage IA1 with LVSI added
- Pathway for Stage IA1-IA2 with LVSI removed.

CERV-2A
- Footnote g revised: Fertility-sparing surgery for stage IB has been most validated for tumors ~~≤2~~ <2 cm.

CERV-3
- Stage 1A1 no LVSI
  - Biopsy Results; Revised: Positive margins for ~~dysplasia or~~ carcinoma and medically inoperable
  - Primary Treatment (Non-Fertility Sparing)
    - Positive margins for carcinoma and medically inoperable pathway: Revised, *Repeat cone biopsy (preferred) or* Brachytherapy ± pelvic external beam radiation therapy (EBRT) ~~or Consider repeat cone biopsy~~
    - Positive margins for dysplasia or carcinoma and medically operable pathway: Revised, "...or Type A *hysterectomy* (if margins positive for dysplasia) + *SLN mapping or pelvic lymphadenectomy* or Type B radical hysterectomy *(if margins positive for carcinoma)* + SLN mapping or pelvic lymphadenectomy ~~(if margins positive for carcinoma) (category 2B for node dissection)~~
- Stage IA1 with LVSI (based on cone/LEEP)
  - Primary Treatment (Non-Fertility Sparing); Positive margins for dysplasia or carcinoma pathway: Revised, Type B radical hysterectomy *(if margins positive for carcinoma)* + SLN mapping or pelvic lymphadenectomy ~~(if margins positive for carcinoma)~~

Continued

Version 2.2026, 11/10/25 © 2025 National Comprehensive Cancer Network® (NCCN®), All rights reserved. NCCN Guidelines® and this illustration may not be reproduced in any form without the express written permission of NCCN.

PLEASE NOTE that use of this NCCN Content is governed by the End-User License Agreement, and you MAY NOT distribute this Content or use it with any artificial intelligence model or tool.
Printed by Galya Basol Kochav on 12/29/2025 12:47:39 PM. Copyright © 2025 National Comprehensive Cancer Network, Inc. All Rights Reserved.

Updates in Version 1.2026 of the NCCN Guidelines for Cervical Cancer from Version 4.2025 include:

CERV-5
- Stage IB3 and Stage IIA2; Primary Treatment (Non-Fertility Sparing): Revised, "...+ selective completion hysterectomy (category 3 *for completion hysterectomy*)"

CERV-6
- Adjuvant treatment
  - Negative nodes, negative margins, negative parametrium pathway: Revised, "... or Pelvic EBRT if combination of risk factors (ie, primary tumor size, stromal invasion, and/or LVSI that meet *GOG/*Sedlis criteria) (category 1) ~~± concurrent platinum-containing chemotherapy (category 2B for chemotherapy)~~"
  - Positive pelvic nodes and/or Positive surgical margin and/or Positive parametrium pathway: The pathway was extensively revised to include a new bifurcation for "Negative for distant metastases" and "Positive for distant metastases"
  - Para-aortic lymph node positive by surgical staging pathway: Recommendation revised, Extended-field EBRT + concurrent platinum-containing chemotherapy *(category 1)* ± brachytherapy

CERV-7
- IIB–IVA; Negative; Primary Treatment revised: "...+ brachytherapy ± *concurrent and maintenance* Pembrolizumab..."

CERV-8
- Column header revised: "...or Usual type Adenocarcinoma After Simple *Total* Hysterectomy"
- Stage IA1 with LVSI and negative margins: Pelvic lymphadenectomy *(preferred)*
- Stage IA2–IB1 cervical carcinoma (based on total hysterectomy [TH] and all conservative surgery criteria met) bullets revised:
  - 1st Bullet Revised: Negative margins *for cancer*
  - 3rd Bullet revised: Squamous cell (any grade) or usual type adenocarcinoma (grade 1 or 2) (preferred) ~~or adenosquamous carcinoma~~
  - New Bullet added: No LVSI (preferred)
- Any hysterectomy with a positive margin for cancer: This pathway was extensively revised
- Footnote c added: Principles of Imaging (CERV-B).

CERV-9
- This page was extensively revised.

CERV-10
- Surveillance; Last bullet revised: "... (Also see *Principles of Gynecologic Survivorship [CERV-G]*, NCCN Guidelines for Survivorship and..."
- Footnote aa revised: ~~Regular cytology can be considered for detection of lower genital tract dysplasia and for patients who are immunocompromised, although its value in detection of recurrent cervical cancer is limited. The likelihood of picking up asymptomatic recurrences by cytology alone is low.~~ *Regular cytology has limited value in detection of recurrent cervical cancer with low likelihood of picking up asymptomatic recurrences. Consider for certain indications, such in those patients who are immunocompromised.*
- Footnote bb revised: ~~The accuracy of cytology results may be affected in patients who have received pelvic radiation.~~ *Cytology is not recommended in patients with prior radiation, unless there are other indications, given limited accuracy in this setting.*
- Footnote dd revised: "... (including vaginal dilator *use,* ~~and~~ lubricants/moisturizers, *and* local estrogen *and* hormone therapy for menopause)..."

Continued

Version 2.2026, 11/10/25 © 2025 National Comprehensive Cancer Network® (NCCN®), All rights reserved. NCCN Guidelines® and this illustration may not be reproduced in any form without the express written permission of NCCN.

PLEASE NOTE that use of this NCCN Content is governed by the End-User License Agreement, and you MAY NOT distribute this Content or use it with any artificial intelligence model or tool.
Printed by Galya Basol Kochav on 12/29/2025 12:47:39 PM. Copyright © 2025 National Comprehensive Cancer Network, Inc. All Rights Reserved.

Updates in Version 1.2026 of the NCCN Guidelines for Cervical Cancer from Version 4.2025 include:

CERV-10
- Surveillance; Last bullet revised: "... (Also see *Principles of Gynecologic Survivorship [CERV-G]*, NCCN Guidelines for Survivorship and..."
- Footnote aa revised: ~~Regular cytology can be considered for detection of lower genital tract dysplasia and for patients who are immunocompromised, although its value in detection of recurrent cervical cancer is limited. The likelihood of picking up asymptomatic recurrences by cytology alone is low.~~ *Regular cytology has limited value in detection of recurrent cervical cancer with low likelihood of picking up asymptomatic recurrences. Consider for certain indications, such in those patients who are immunocompromised.*
- Footnote bb revised: ~~The accuracy of cytology results may be affected in patients who have received pelvic radiation.~~ *Cytology is not recommended in patients with prior radiation, unless there are other indications, given limited accuracy in this setting.*
- Footnote dd revised: "... (including vaginal dilator *use,* ~~and~~ lubricants/moisturizers, *and* local estrogen *and* hormone therapy for menopause)..."

CERV-11
- Prior RT; Therapy for Relapse
  - Central Disease: Revised, Pelvic exenteration ± intraoperative RT (IORT) ~~(category 3 for IORT)~~
- Noncentral Disease: Revised, Resection ± IORT ~~(category 3 for IORT)~~

Small Cell Neuroendocrine Carcinoma of the Cervix (NECC)

CERV-13
- Stage IA1–1B2 (tumor ≤4 cm); Primary Treatment revised: " Radical hysterectomy + *SLN mapping or pelvic lymphadenectomy* ~~+ pelvic lymphadenectomy~~ (preferred if suitable for primary surgery)..."
- Metastatic disease (Stage IVB); Primary Treatment revised: Link to CERV-12 removed. Recommendations added for "Systemic therapy (preferred) or Best supportive care (See NCCN Guidelines for Palliative Care)."
- Footnote t revised: Systemic Therapy for Cervical Cancer (CERV-F *2 of 3*) (Also for CERV-14)

CERV-14
- Locally advanced disease (IIA–IVA); Adjuvant treatment for Distant metastatic disease: Revised, Link to CERV-12 removed. Recommendations added for "Systemic therapy (preferred) or Best supportive care (See NCCN Guidelines for Palliative Care)."

All Histologies

CERV-A 1 of 7 Squamous Cell Carcinoma, Adenocarcinoma, or Adenosquamous Carcinoma
- 1st bullet; Pathologic assessment
  - 1st arrow sub-bullet; 4th Diamond sub-bullet revised: Histologic type *(HPV-associated vs. HPV-independent)*
- 2nd bullet; Additional molecular testing and biomarkers
  - 3rd arrow sub-bullet; New sub-bullet added: Cervical carcinomas demonstrating HER2 amplification/overexpression have been associated with higher recurrence rates and worse prognosis. Testing advanced, metastatic, or recurrent cervical carcinomas may provide additional targeted anti-HER2 therapy options.
- 4th arrow-sub-bullet revised: In the setting of metastatic or recurrent disease, ~~consider~~ comprehensive molecular profiling by an FDA-approved assay, or a validated test performed in a CLIA-certified laboratory including at least HER2, mismatch repair (MMR)/microsatellite instability (MSI), tumor mutational burden (TMB) testing, *NTRK*, and *RET* for predicting rare pan-tumor targeted therapy opportunities *is preferred."*
  - Footnote a revised: ~~According to the 2018 International Endocervical Adenocarcinoma Criteria and Classification (IECC), morphologic features (luminal mitotic figures and apoptosis) can be used to distinguish between HPV-associated endocervical adenocarcinomas and HPV-independent adenocarcinomas. Tumors can be further subtyped based on morphologic features~~.
    In addition to morphologic features (luminal mitotic figures and apoptosis) as outlined in the 2018 International Endocervical Adenocarcinoma Criteria and Classification (IECC), HPV ISH, molecular testing, or p16 IHC (if HPV testing is not available) should be performed to determine HPV status and the histologic tumor type.

Continued

Version 2.2026, 11/10/25 © 2025 National Comprehensive Cancer Network® (NCCN®), All rights reserved. NCCN Guidelines® and this illustration may not be reproduced in any form without the express written permission of NCCN.

PLEASE NOTE that use of this NCCN Content is governed by the End-User License Agreement, and you MAY NOT distribute this Content or use it with any artificial intelligence model or tool.
Printed by Galya Basol Kochav on 12/29/2025 12:47:39 PM. Copyright © 2025 National Comprehensive Cancer Network, Inc. All Rights Reserved.

Updates in Version 1.2026 of the NCCN Guidelines for Cervical Cancer from Version 4.2025 include:

CERV-A 4 of 7
- Endocervical Adenocarcinoma; Histologic Subtypes
  - 1st Bullet
    - New diamond sub-bullet added: Recent publications suggest combining pattern A and B without LVSI into one group and pattern B with LVSI and pattern C into a second group.
  - 2nd Bullet
    - 1st arrow sub-bullet revised: "...it may show ~~mutated~~ *aberrant* p53 expression in approximately 50% of cases."
    - 3rd arrow sub-bullet revised: "Clear cell carcinomas make up ~~3%–4%~~ *3%* of endocervical adenocarcinomas..."

CERV-A 5 of 7
- Adenosquamous Carcinoma; General Principles; 1st Bullet revised: Epithelial tumor with *malignant* squamous and *malignant* glandular differentiation

CERV-A 6 of 7
- Neuroendocrine Carcinoma of the Cervix (NECC)
  - 1st Bullet; 5th arrow sub-bullet revised: Small cell NECC is a morphologic diagnosis ~~regardless of IHC staining profile~~.
  - 2nd Bullet; Immunohistochemistry
    - 2nd arrow sub-bullet revised: ~~If the tumor demonstrates classic morphologic features of small cell NECC, the diagnosis can be made in the absence of IHC neuroendocrine positivity~~ *While these IHC markers are not always expressed in all tumors, they should be performed in the diagnostic workup of NECC. Even when negative, the diagnosis of NECC can be made if classic morphologic features are present* (this is NOT true for large cell NECC)
    - New sub-bullet added: In the setting of IHC-negative or suspected IHC-negative small cell NECC, expert pathologic review is recommended.
  - Footnote e is new: Given the rarity of small cell NECC, there are currently no well-established management guidelines.

CERV-A 7 of 7
- References were updated

CERV-C 1 of 9
- Types of Resection and Appropriateness for Treatment of Cervical Cancer
  - 2nd Bullet revised: "...In cases of stage IA1 with LVSI *and desire to preserve fertility*, a conization (with negative margins) with pelvic SLN mapping/ lymphadenectomy is a reasonable strategy."
  - 3rd Bullet
    - 1st bullet: Cone biopsy with negative margins *for cancer*
    - 2nd arrow sub-bullet: No LVSI *(preferred)*
    - 3rd arrow sub-bullet: Squamous cell cancer (any grade) or usual type adenocarcinoma (grade 1 or 2) *(preferred)*

CERV-C 2 of 9
- Types of Resection and Appropriateness for Treatment of Cervical Cancer
  - 3rd Bullet
    - 3rd arrow sub-bullet: Negative cone margins *for cancer* (preferred)
    - 4th arrow sub-bullet: Squamous cell (any grade) or usual type adenocarcinoma (grade 1 or 2) (preferred)~~, or adenosquamous carcinoma~~
  - Last bullet revised: "Definitive treatment with a conization or ~~simple~~ Type A hysterectomy has not been studied in the more..."

CERV-C 6 of 9 to CERV-C 9 of 9
- References moved to page CERV-C (9 of 9)

Continued

Version 2.2026, 11/10/25 © 2025 National Comprehensive Cancer Network® (NCCN®), All rights reserved. NCCN Guidelines® and this illustration may not be reproduced in any form without the express written permission of NCCN.

PLEASE NOTE that use of this NCCN Content is governed by the End-User License Agreement, and you MAY NOT distribute this Content or use it with any artificial intelligence model or tool.
Printed by Galya Basol Kochav on 12/29/2025 12:47:39 PM. Copyright © 2025 National Comprehensive Cancer Network, Inc. All Rights Reserved.

Updates in Version 1.2026 of the NCCN Guidelines for Cervical Cancer from Version 4.2025 include:

CERV-D 1 of 9
- General Principles; 1st Bullet revised: "...FDG-PET/*CT* imaging is useful to help define the nodal volume of coverage..."

CERV-D 3 of 9
- Posthysterectomy Adjuvant Radiation Therapy
  - New bullets added
    - Consider vaginal cuff brachytherapy boost for positive or close vaginal margins after radical hysterectomy, or after total/simple hysterectomy if completion upper vaginectomy not performed.
    - Recommended dose regimens include 5–6 Gy x 2–3 fractions to either 0.5 cm depth or vaginal surface. Treatment active length is typically the apical 3–4 cm.
  - Bullet removed: Consider vaginal cuff brachytherapy for positive or close vaginal margins.
- Intraoperative Radiation Therapy: Changed from a category 3 to a category 2A.

CERV-D 4 of 9
- Treatment Information - Brachytherapy; 3rd Bullet revised: "...vaginal cylinder brachytherapy may be used as a boost to EBRT *(regimens described in CERV-D 3 of 9)*."

CERV-D 7 of 9
- The following title was added to the second table: Normal Tissue Dose Constraints Guidelines (With Inguinal Treatment)

CERV-D 9 of 9
- References 16 was updated.

CERV-E
- Page title revised: *GOG*/Sedlis Criteria For External Pelvic Radiation..."
- Footnote b and c: Revised "*GOG*/Sedlis criteria"

CERV-F 1 of 4
- Recurrent or Metastatic Disease; Second-Line or Subsequent Therapy; Other Recommended: Ipilimumab + Nivolumab added.

CERV-F 1A of 4
- Footnote c revised: ~~NCCN Guidelines for the Management of Immunotherapy-Related Toxicities~~. *For immunotherapy regimens, also refer to NCCN Guidelines for the Management of Immune Checkpoint Inhibitor-Related Toxicities*. (Also for CERV-F 2 of 3)
- Footnote g is new: Testing for dihydropyrimidine dehydrogenase (DPYD) genetic variants should be considered prior to fluoropyrimidine therapy. After discussions regarding risk assessment, patients may choose DPYD genetic testing. However, no specific test is recommended at this time and there are insufficient data to inform dose adjustments for many of the DPYD variants. See DPYD Testing and Fluoropyrimidine-Associated Toxicity Discussion section in the NCCN Guidelines for Colon Cancer for more information.
- Footnote k is new: Pembrolizumab and berahyaluronidase alfa-pmph subcutaneous injection may be substituted for IV pembrolizumab. Pembrolizumab and berahyaluronidase alfa-pmph has different dosing and administration instructions compared to IV pembrolizumab.

CERV-F 2 of 4
- Small Cell Neuroendocrine Carcinoma of Cervix (NECC)
  - Recurrent or Metastatic Disease; Second-Line or Subsequent Therapy; Other Recommended: Ipilimumab + Nivolumab added.

Continued

Version 2.2026, 11/10/25 © 2025 National Comprehensive Cancer Network® (NCCN®), All rights reserved. NCCN Guidelines® and this illustration may not be reproduced in any form without the express written permission of NCCN.

PLEASE NOTE that use of this NCCN Content is governed by the End-User License Agreement, and you MAY NOT distribute this Content or use it with any artificial intelligence model or tool.
Printed by Galya Basol Kochav on 12/29/2025 12:47:39 PM. Copyright © 2025 National Comprehensive Cancer Network, Inc. All Rights Reserved.

Updates in Version 1.2026 of the NCCN Guidelines for Cervical Cancer from Version 4.2025 include:

CERV-F 3 of 3
- References added
  - Oaknin A, Moore K, Meyer T, et al. Nivolumab with or without ipilimumab in patients with recurrent or metastatic cervical cancer (CheckMate 358): a phase 1–2, open-label, multicohort trial. Lancet Oncol 2024;25:588-602.
  - Schenker M, Burotto M, Richardet M, et al. Randomized, open-label, phase 2 study of nivolumab plus ipilimumab or nivolumab monotherapy in patients with advanced or metastatic solid tumors of high tumor mutational burden. J Immunother Cancer 2024;12:e008872.
  - Towner M, Novak K, Chae YK, Matei D. Ipilimumab and nivolumab for recurrent neuroendocrine cervical carcinoma. Gynecol Oncol Rep 2022;42:101039.

MS-1
- The Discussion was updated to reflect the changes in the algorithm.

PLEASE NOTE that use of this NCCN Content is governed by the End-User License Agreement, and you MAY NOT distribute this Content or use it with any artificial intelligence model or tool.
Printed by Galya Basol Kochav on 12/29/2025 12:47:39 PM. Copyright © 2025 National Comprehensive Cancer Network, Inc. All Rights Reserved.

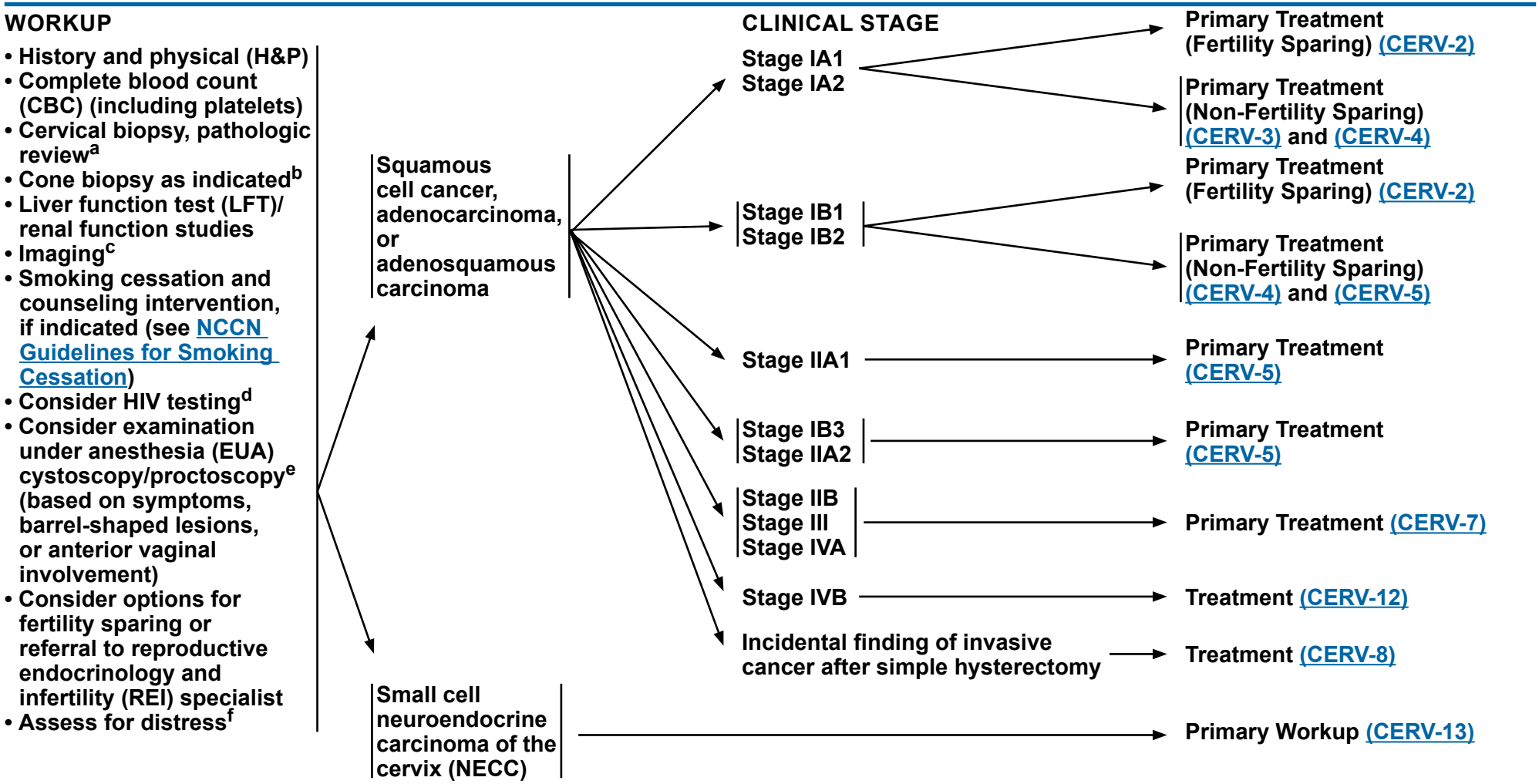

[a] Principles of Pathology (CERV-A).
[b] See Discussion for indications for cone biopsy.
[c] Principles of Imaging (CERV-B).
[d] Consider human immunodeficiency virus (HIV) testing, especially in younger patients. Patients with cervical cancer and HIV should be referred to an HIV specialist and should be treated for cervical cancer as per these guidelines. Modifications to cancer treatment should not be made solely on the basis of HIV status. See NCCN Guidelines for Cancer in People with HIV.
[e] For suspicion of bladder/bowel involvement, cystoscopy/proctoscopy with biopsy is required.
[f] Refer to the NCCN Distress Thermometer and Problem List, which includes social determinants of health. See NCCN Guidelines for Distress Management (DIS-A).

All staging in guidelines is based on updated 2018 FIGO staging. (ST-1)

Note: All recommendations are category 2A unless otherwise indicated.

Version 2.2026, 11/10/25 © 2025 National Comprehensive Cancer Network® (NCCN®), All rights reserved. NCCN Guidelines® and this illustration may not be reproduced in any form without the express written permission of NCCN.

PLEASE NOTE that use of this NCCN Content is governed by the End-User License Agreement, and you MAY NOT distribute this Content or use it with any artificial intelligence model or tool.
Printed by Galya Basol Kochav on 12/29/2025 12:47:39 PM. Copyright © 2025 National Comprehensive Cancer Network, Inc. All Rights Reserved.

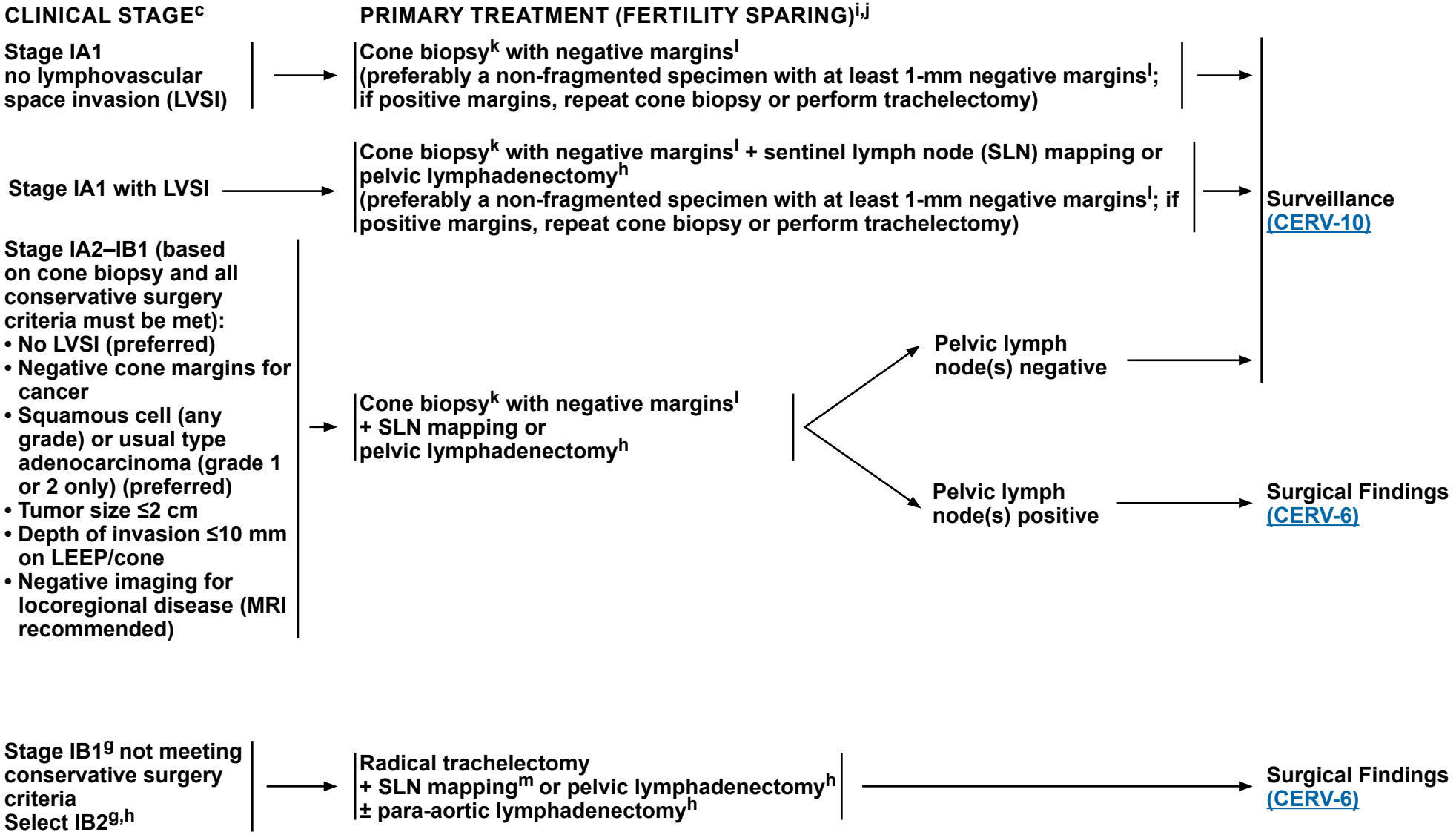

Footnotes on CERV-2A

Note: All recommendations are category 2A unless otherwise indicated.

Version 2.2026, 11/10/25 © 2025 National Comprehensive Cancer Network® (NCCN®), All rights reserved. NCCN Guidelines® and this illustration may not be reproduced in any form without the express written permission of NCCN.

PLEASE NOTE that use of this NCCN Content is governed by the End-User License Agreement, and you MAY NOT distribute this Content or use it with any artificial intelligence model or tool.
Printed by Galya Basol Kochav on 12/29/2025 12:47:39 PM. Copyright © 2025 National Comprehensive Cancer Network, Inc. All Rights Reserved.

FOOTNOTES FOR CERV-2

[c] Principles of Imaging (CERV-B).
[g] Fertility-sparing surgery for stage IB has been most validated for tumors <2 cm. For stage IB2 lesions 2–4 cm, abdominal approach is favored. Small cell neuroendocrine histology and gastric type adenocarcinoma are not considered suitable tumors for this procedure.
[h] Principles of Evaluation and Surgical Staging (CERV-C).
[i] There are no data to support a fertility-sparing approach in small neuroendocrine tumors or gastric type adenocarcinoma. Total hysterectomy after completion of childbearing is at the patient's and surgeon's discretion, but is strongly advised in patients with continued abnormal pap smears or chronic persistent human papillomavirus (HPV) infection.
[j] Consultation with REI experts is suggested.
[k] Cold knife conization (CKC) is the preferred method of diagnostic excision, but loop electrosurgical excision procedure (LEEP) is acceptable, provided adequate margins and proper orientation are obtained. Endocervical curettage (ECC) above the excision should be added except in pregnancy.
[l] Negative for invasive disease or histologic high-grade squamous intraepithelial lesion (HSIL) at margins.
[m] For SLN mapping, the best detection rates and mapping results are in tumors <2 cm.

Note: All recommendations are category 2A unless otherwise indicated.

Version 2.2026, 11/10/25 © 2025 National Comprehensive Cancer Network® (NCCN®), All rights reserved. NCCN Guidelines® and this illustration may not be reproduced in any form without the express written permission of NCCN.

PLEASE NOTE that use of this NCCN Content is governed by the End-User License Agreement, and you MAY NOT distribute this Content or use it with any artificial intelligence model or tool.
Printed by Galya Basol Kochav on 12/29/2025 12:47:39 PM. Copyright © 2025 National Comprehensive Cancer Network, Inc. All Rights Reserved.

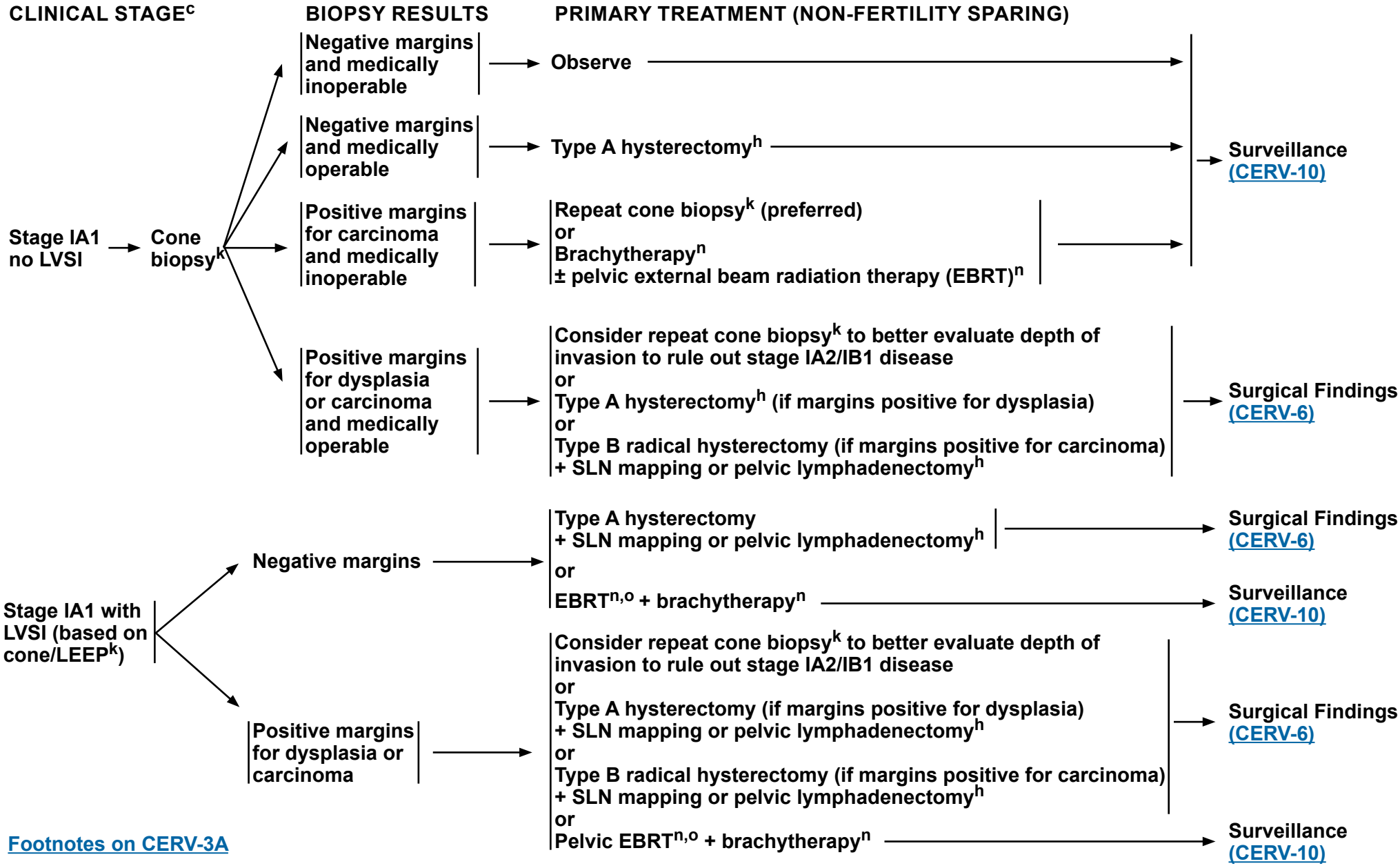

Footnotes on CERV-3A

Note: All recommendations are category 2A unless otherwise indicated.

Version 2.2026, 11/10/25 © 2025 National Comprehensive Cancer Network® (NCCN®), All rights reserved. NCCN Guidelines® and this illustration may not be reproduced in any form without the express written permission of NCCN.

PLEASE NOTE that use of this NCCN Content is governed by the End-User License Agreement, and you MAY NOT distribute this Content or use it with any artificial intelligence model or tool.
Printed by Galya Basol Kochav on 12/29/2025 12:47:39 PM. Copyright © 2025 National Comprehensive Cancer Network, Inc. All Rights Reserved.

FOOTNOTES FOR CERV-3

[c] Principles of Imaging (CERV-B).
[h] Principles of Evaluation and Surgical Staging (CERV-C).
[k] CKC is the preferred method of diagnostic excision, but LEEP is acceptable, provided adequate margins and proper orientation are obtained. ECC above the excision should be added, except in pregnancy.
[n] Principles of Radiation Therapy (CERV-D).
[o] Radiation can be an option for patients who are medically inoperable.

Note: All recommendations are category 2A unless otherwise indicated.

Version 2.2026, 11/10/25 © 2025 National Comprehensive Cancer Network® (NCCN®), All rights reserved. NCCN Guidelines® and this illustration may not be reproduced in any form without the express written permission of NCCN.

PLEASE NOTE that use of this NCCN Content is governed by the End-User License Agreement, and you MAY NOT distribute this Content or use it with any artificial intelligence model or tool.
Printed by Galya Basol Kochav on 12/29/2025 12:47:39 PM. Copyright © 2025 National Comprehensive Cancer Network, Inc. All Rights Reserved.

CLINICAL STAGE[c]

PRIMARY TREATMENT (NON-FERTILITY SPARING)

Stage IA2–IB1 cervical carcinoma
(All conservative surgery criteria met):
- **Cone biopsy[k] (preferred)**
- **No LVSI (preferred)**
- **Negative cone margins for cancer (preferred)**
- **Squamous cell (any grade) or usual type adenocarcinoma (grade 1 or 2) (preferred)**
- **Tumor size ≤2 cm**
- **Depth of invasion <10 mm on cone.[k] If no conization, MRI[c] must show <50% cervical stromal invasion**
- **Negative imaging for metastatic disease (MRI recommended)**

→ **Type A hysterectomy + SLN mapping or pelvic lymphadenectomy[h]** → **Surgical Findings (CERV-6)**

[c] Principles of Imaging (CERV-B).
[h] Principles of Evaluation and Surgical Staging (CERV-C).
[k] CKC is the preferred method of diagnostic excision, but LEEP is acceptable, provided adequate margins and proper orientation are obtained. ECC above the excision should be added, except in pregnancy.

Note: All recommendations are category 2A unless otherwise indicated.

Version 2.2026, 11/10/25 © 2025 National Comprehensive Cancer Network® (NCCN®), All rights reserved. NCCN Guidelines® and this illustration may not be reproduced in any form without the express written permission of NCCN.

PLEASE NOTE that use of this NCCN Content is governed by the End-User License Agreement, and you MAY NOT distribute this Content or use it with any artificial intelligence model or tool.
Printed by Galya Basol Kochav on 12/29/2025 12:47:39 PM. Copyright © 2025 National Comprehensive Cancer Network, Inc. All Rights Reserved.

CLINICAL STAGE[c]	PRIMARY TREATMENT (NON-FERTILITY SPARING)	
Stage IB1 not meeting conservative surgery criteria Stage IB2 Stage IIA1	Type C1 radical hysterectomy + SLN mapping[m] or pelvic lymphadenectomy[h] (category 1) ± para-aortic lymphadenectomy[h] (category 2B)	Surgical Findings (CERV-6)
	or Pelvic EBRT[n,o] + brachytherapy[n] ± concurrent platinum-containing chemotherapy[p]	Surveillance (CERV-10)
Stage IB3 and Stage IIA2	Pelvic EBRT[n,q] + concurrent platinum-containing chemotherapy[p] + brachytherapy[n] (category 1)	Surveillance (CERV-10)
	or Type C1 radical hysterectomy + pelvic lymphadenectomy[h] ± para-aortic lymphadenectomy[h] (category 2B)	Surgical Findings (CERV-6)
	or Pelvic EBRT[n] + concurrent platinum-containing chemotherapy[p] + brachytherapy[n] + selective completion hysterectomy[r] (category 3 for completion hysterectomy)	Surveillance (CERV-10)

[c] Principles of Imaging (CERV-B).
[h] Principles of Evaluation and Surgical Staging (CERV-C).
[m] For SLN mapping, the best detection rates and mapping results are in tumors <2 cm.
[n] Principles of Radiation Therapy (CERV-D).
[o] Radiation can be an option for patients who are medically inoperable.
[p] Concurrent platinum-containing chemotherapy with EBRT utilizes cisplatin as a single agent (or carboplatin if cisplatin intolerant). See Systemic Therapy for Cervical Cancer (CERV-F).
[q] Induction chemotherapy (carboplatin/paclitaxel) followed by single-agent cisplatin (or carboplatin) and radiation given according to the INTERLACE protocol could be considered (McCormack M, et al. Lancet 2024;404:1525-1535). See Systemic Therapy for Cervical Cancer (CERV-F).
[r] This approach should only be considered in the patients whose tumor shows a poor response with evidence of residual disease after chemoradiation + image-guided brachytherapy (IGBT) or in patients for whom IGBT is not feasible.

Note: All recommendations are category 2A unless otherwise indicated.

Version 2.2026, 11/10/25 © 2025 National Comprehensive Cancer Network® (NCCN®), All rights reserved. NCCN Guidelines® and this illustration may not be reproduced in any form without the express written permission of NCCN.

PLEASE NOTE that use of this NCCN Content is governed by the End-User License Agreement, and you MAY NOT distribute this Content or use it with any artificial intelligence model or tool.
Printed by Galya Basol Kochav on 12/29/2025 12:47:39 PM. Copyright © 2025 National Comprehensive Cancer Network, Inc. All Rights Reserved.

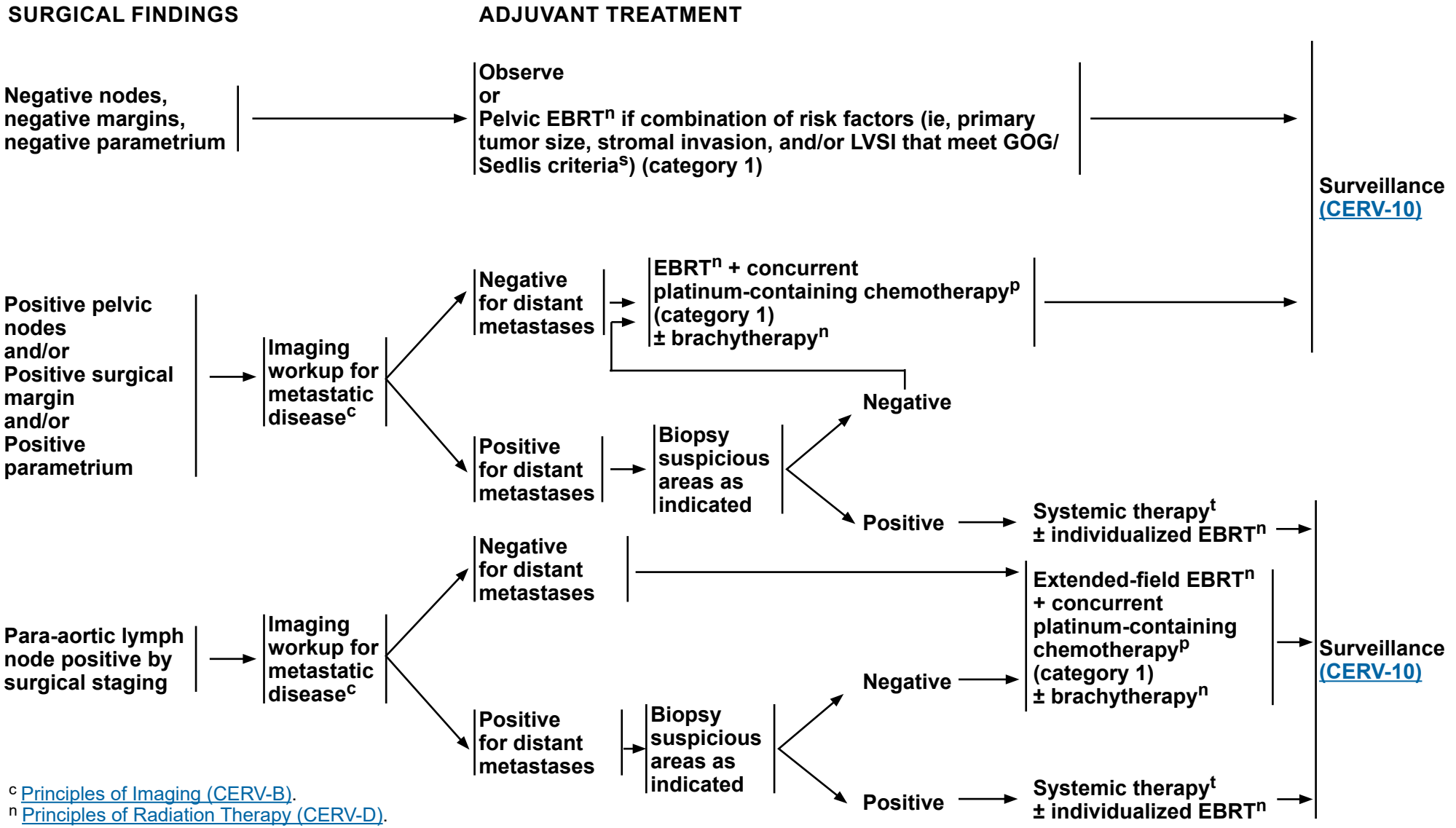

[c] Principles of Imaging (CERV-B).
[n] Principles of Radiation Therapy (CERV-D).
[p] Concurrent platinum-containing chemotherapy with EBRT utilizes cisplatin as a single agent (or carboplatin if cisplatin intolerant). See Systemic Therapy for Cervical Cancer (CERV-F).
[s] Risk factors may not be limited to the GOG/Sedlis criteria. See GOG/Sedlis Criteria (CERV-E).
[t] Systemic Therapy for Cervical Cancer (CERV-F).

Note: All recommendations are category 2A unless otherwise indicated.

Surveillance (CERV-10)

Version 2.2026, 11/10/25 © 2025 National Comprehensive Cancer Network® (NCCN®), All rights reserved. NCCN Guidelines® and this illustration may not be reproduced in any form without the express written permission of NCCN.

PLEASE NOTE that use of this NCCN Content is governed by the End-User License Agreement, and you MAY NOT distribute this Content or use it with any artificial intelligence model or tool.
Printed by Galya Basol Kochav on 12/29/2025 12:47:39 PM. Copyright © 2025 National Comprehensive Cancer Network, Inc. All Rights Reserved.

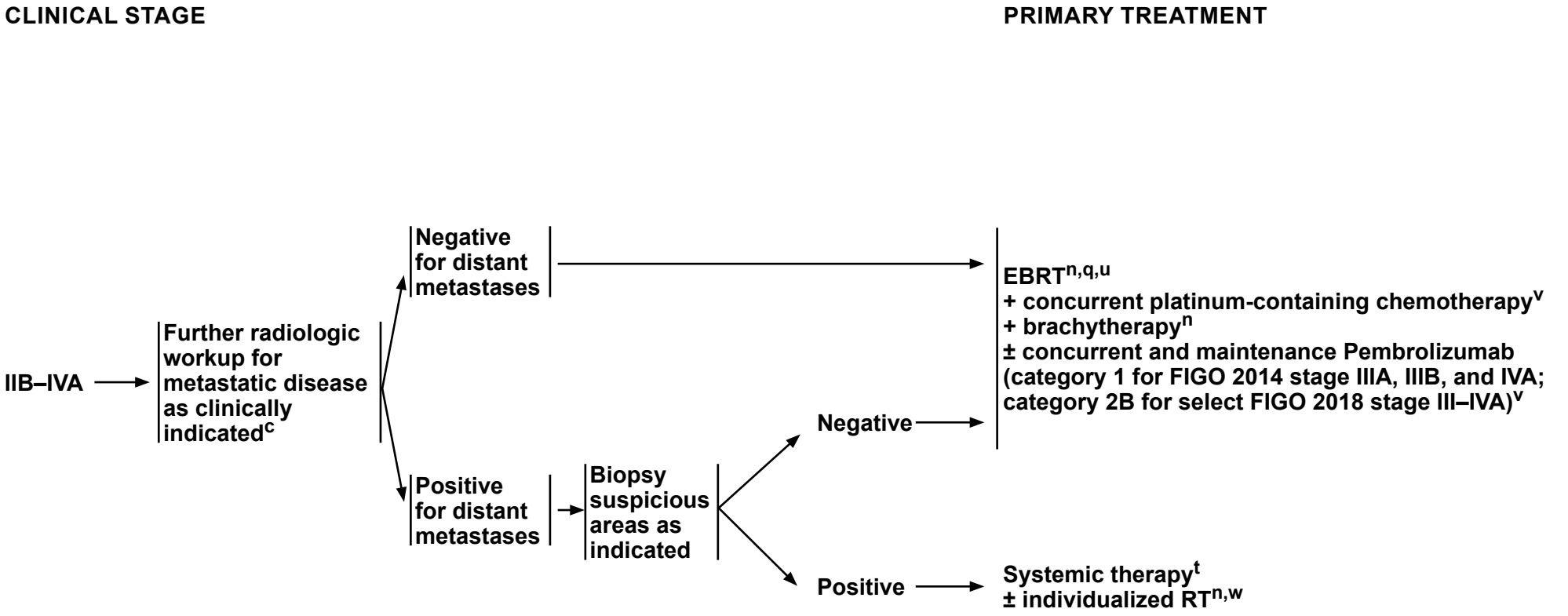

[c] Principles of Imaging (CERV-B).
[n] Principles of Radiation Therapy (CERV-D).
[q] Induction chemotherapy (carboplatin/paclitaxel) followed by single-agent cisplatin (or carboplatin) and radiation given according to the INTERLACE protocol could be considered (McCormack M, et al. Lancet 2024;404:1525-1535). See Systemic Therapy for Cervical Cancer (CERV-F).
[t] Systemic Therapy for Cervical Cancer (CERV-F).
[u] Extended-field RT is recommended when para-aortic nodes are involved by imaging or confirmed on pathology. This may also be added in select patients with positive pelvic nodes such as common iliac metastasis.
[v] Concurrent platinum-containing chemotherapy with EBRT utilizes cisplatin as a single agent (or carboplatin if cisplatin intolerant). Pembrolizumab may be added as follows: cisplatin (or carboplatin)/radiation therapy (RT) and pembrolizumab (for FIGO 2014 stage IIIA, IIIB, and IVA: category 1); cisplatin (or carboplatin)/RT and pembrolizumab (for select FIGO 2018 stage III–IVA: category 2B). Category 2B is for FIGO 2018 stage IIIC purely on nodal metastasis without concomitant tumor characteristics defined in 2014 FIGO stage IIIA–IIIB. If the FIGO 2018 staging of stage III overlaps with FIGO 2014 IIIA/IIIB staging, category 1 can be applied to cisplatin (or carboplatin) + pembrolizumab. See Systemic Therapy for Cervical Cancer (CERV-F).
[w] Consider ablative therapy for 1–5 metastatic lesions (category 2B) if the primary has been controlled (Palma DA, et al. Lancet 2019;393:2051-2058).

Note: All recommendations are category 2A unless otherwise indicated.

Surveillance (CERV-10)

Version 2.2026, 11/10/25 © 2025 National Comprehensive Cancer Network® (NCCN®), All rights reserved. NCCN Guidelines® and this illustration may not be reproduced in any form without the express written permission of NCCN.

PLEASE NOTE that use of this NCCN Content is governed by the End-User License Agreement, and you MAY NOT distribute this Content or use it with any artificial intelligence model or tool.
Printed by Galya Basol Kochav on 12/29/2025 12:47:39 PM. Copyright © 2025 National Comprehensive Cancer Network, Inc. All Rights Reserved.

INCIDENTAL FINDING OF INVASIVE SQUAMOUS OR USUAL TYPE ADENOCARCINOMA AFTER SIMPLE TOTAL HYSTERECTOMY

TREATMENT

Stage IA1 → **Pathologic review** →

- **No LVSI, negative margins** → **Surveillance (CERV-10)**
- **Pelvic lymphadenectomy (preferred)**
  - **If negative node(s)** → **Surveillance (CERV-10)**
  - **If positive node(s)** → **Adjuvant Treatment (CERV-6)**
  - **or**
  - **Pelvic EBRT[n] ± brachytherapy[n] ± concurrent platinum-containing chemotherapy[p] (when specimen integrity unknown)** → **Surveillance (CERV-10)**

Stage IA1 with LVSI and negative margins →

Stage IA2–IB1 cervical carcinoma (based on total hysterectomy [TH] and all conservative surgery criteria met):
- **Negative margins for cancer**
- **No LVSI (preferred)**
- **Squamous cell (any grade) or usual type adenocarcinoma (grade 1 or 2) (preferred)**
- **Tumor size ≤2 cm**
- **Depth of invasion <10 mm**
- **Negative imaging for metastatic disease (MRI recommended)**

→

- **Pelvic lymphadenectomy (preferred)**
  - **If negative node(s)** → **Surveillance (CERV-10)**
  - **If positive node(s)** → **Adjuvant Treatment (CERV-6)**
  - **or**
  - **Pelvic EBRT[n] ± brachytherapy[n] ± concurrent platinum-containing chemotherapy[p] (when specimen integrity unknown)** → **Surveillance (CERV-10)**

Any hysterectomy with a positive margin for cancer[x] → **Imaging workup for metastatic disease[c]**

- **Negative for distant metastases** → **Pelvic EBRT[n] + concurrent platinum-containing chemotherapy[p] + brachytherapy[n]** → **Surveillance (CERV-10)**
- **Positive for distant metastases** → **Adjuvant Treatment (CERV-6)**

[c] Principles of Imaging (CERV-B).
[n] Principles of Radiation Therapy (CERV-D).
[p] Concurrent platinum-containing chemotherapy with EBRT utilizes cisplatin as a single agent (or carboplatin if cisplatin intolerant). See Systemic Therapy for Cervical Cancer (CERV-F).
[x] Invasive cancer at surgical margin.

Note: All recommendations are category 2A unless otherwise indicated.

Version 2.2026, 11/10/25 © 2025 National Comprehensive Cancer Network® (NCCN®), All rights reserved. NCCN Guidelines® and this illustration may not be reproduced in any form without the express written permission of NCCN.

PLEASE NOTE that use of this NCCN Content is governed by the End-User License Agreement, and you MAY NOT distribute this Content or use it with any artificial intelligence model or tool.
Printed by Galya Basol Kochav on 12/29/2025 12:47:39 PM. Copyright © 2025 National Comprehensive Cancer Network, Inc. All Rights Reserved.

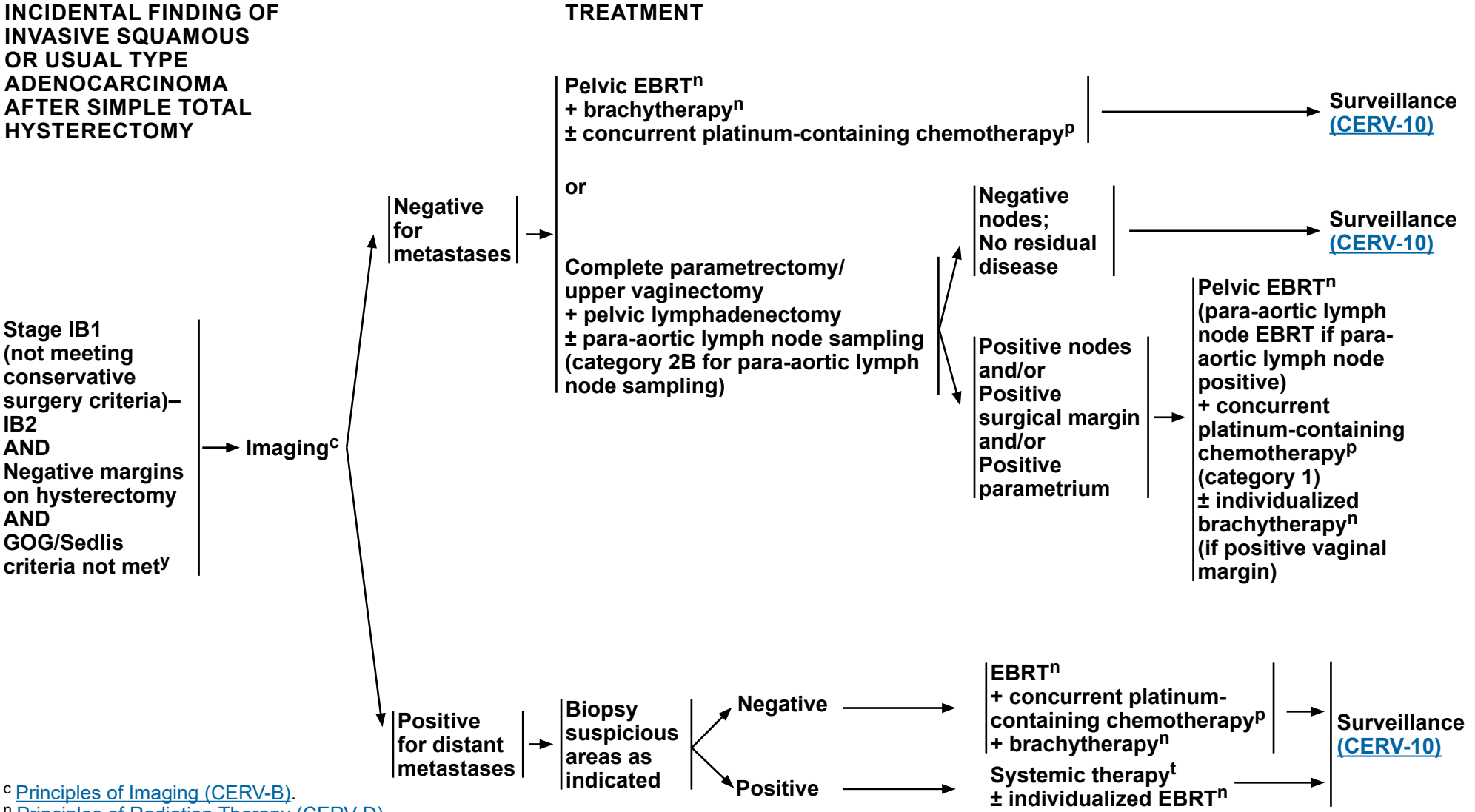

[c] Principles of Imaging (CERV-B).
[n] Principles of Radiation Therapy (CERV-D).
[p] Concurrent platinum-containing chemotherapy with EBRT utilizes cisplatin as a single agent (or carboplatin if cisplatin intolerant). See Systemic Therapy for Cervical Cancer (CERV-F).
[t] Systemic Therapy for Cervical Cancer (CERV-F).
[y] GOG/Sedlis Criteria (CERV-E).

Note: All recommendations are category 2A unless otherwise indicated.

Surveillance (CERV-10)

Version 2.2026, 11/10/25 © 2025 National Comprehensive Cancer Network® (NCCN®), All rights reserved. NCCN Guidelines® and this illustration may not be reproduced in any form without the express written permission of NCCN.

PLEASE NOTE that use of this NCCN Content is governed by the End-User License Agreement, and you MAY NOT distribute this Content or use it with any artificial intelligence model or tool.
Printed by Galya Basol Kochav on 12/29/2025 12:47:39 PM. Copyright © 2025 National Comprehensive Cancer Network, Inc. All Rights Reserved.

SURVEILLANCE[z]

- Interval H&P
  - every 3–6 mo for 2 y,
  - every 6–12 mo for 3–5 y,
  - then annually based on patient's risk of disease recurrence
- Cervical/vaginal cytology screening annually[aa,bb] as indicated for the detection of lower genital tract neoplasia
- Stage-dependent imaging for follow-up[c,cc]
- Laboratory assessment (CBC, blood urea nitrogen [BUN], creatinine) as indicated based on symptoms or examination findings suspicious for recurrence
- Clinical evaluation and management of potential long-term and late effects of treatment[dd] (Also see Principles of Gynecologic Survivorship [CERV-G], NCCN Guidelines for Survivorship and NCCN Guidelines for Smoking Cessation)

→ **Persistent or recurrent disease** →

WORKUP

- Additional imaging as clinically indicated[c]
- Biopsy ± EUA as clinically indicated
- Surgical exploration in selected cases
- Consider comprehensive molecular profiling as determined by an FDA-approved assay, or a validated test performed in a Clinical Laboratory Improvement Amendments (CLIA)-certified laboratory
- If tissue biopsy of metastatic site is not feasible or tissue not available, consider comprehensive genomic profiling (CGP) via a validated plasma circulating tumor DNA (ctDNA) assay

→ **Therapy for Relapse (Locoregional Recurrence)** (CERV-11)

→ **Therapy for Relapse (Distant Metastases)** (CERV-12)

[c] Principles of Imaging (CERV-B).
[z] Salani R, et al. Gynecol Oncol 2017;146:3-10.
[aa] Regular cytology has limited value in detection of recurrent cervical cancer with low likelihood of picking up asymptomatic recurrences. Consider for certain indications, such in those patients who are immunocompromised.
[bb] Cytology is not recommended in patients with prior radiation, unless there are other indications, given limited accuracy in this setting.
[cc] Recurrences should be proven by biopsy before proceeding to treatment planning.
[dd] Patient education should include symptoms of potential recurrence, lifestyle, obesity, exercise, sexual health (including vaginal dilator use, lubricants/moisturizers, and local estrogen and hormone therapy for menopause), smoking cessation, and nutrition counseling.

Note: All recommendations are category 2A unless otherwise indicated.

Version 2.2026, 11/10/25 © 2025 National Comprehensive Cancer Network® (NCCN®), All rights reserved. NCCN Guidelines® and this illustration may not be reproduced in any form without the express written permission of NCCN.

PLEASE NOTE that use of this NCCN Content is governed by the End-User License Agreement, and you MAY NOT distribute this Content or use it with any artificial intelligence model or tool.
Printed by Galya Basol Kochav on 12/29/2025 12:47:39 PM. Copyright © 2025 National Comprehensive Cancer Network, Inc. All Rights Reserved.

THERAPY FOR RELAPSE

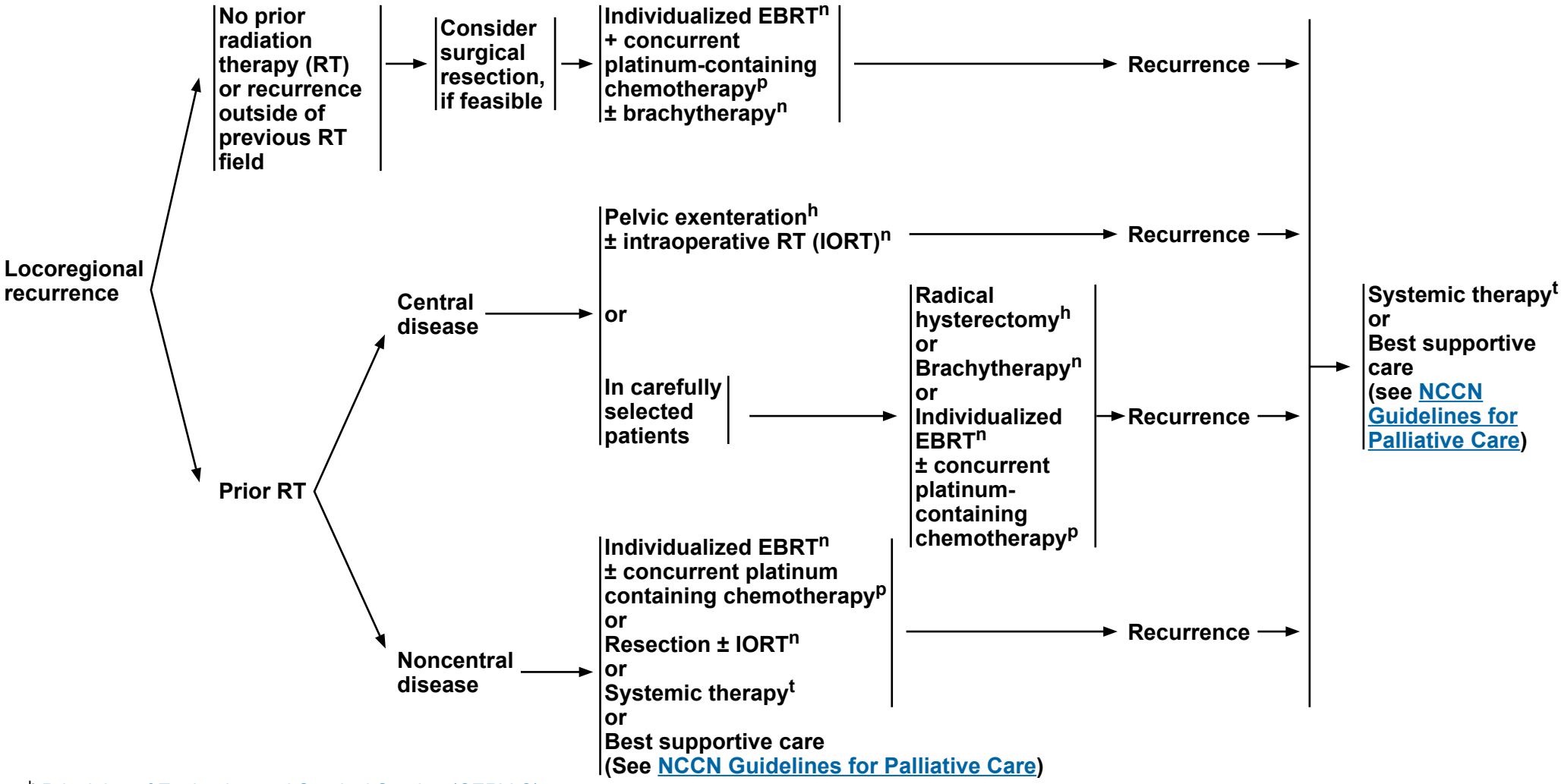

[h] Principles of Evaluation and Surgical Staging (CERV-C).
[n] Principles of Radiation Therapy (CERV-D).
[p] Concurrent platinum-containing chemotherapy with EBRT utilizes cisplatin as a single agent (or carboplatin if cisplatin intolerant). See Systemic Therapy for Cervical Cancer (CERV-F).
[t] Systemic Therapy for Cervical Cancer (CERV-F).

Note: All recommendations are category 2A unless otherwise indicated.

Version 2.2026, 11/10/25 © 2025 National Comprehensive Cancer Network® (NCCN®), All rights reserved. NCCN Guidelines® and this illustration may not be reproduced in any form without the express written permission of NCCN.

PLEASE NOTE that use of this NCCN Content is governed by the End-User License Agreement, and you MAY NOT distribute this Content or use it with any artificial intelligence model or tool.
Printed by Galya Basol Kochav on 12/29/2025 12:47:39 PM. Copyright © 2025 National Comprehensive Cancer Network, Inc. All Rights Reserved.

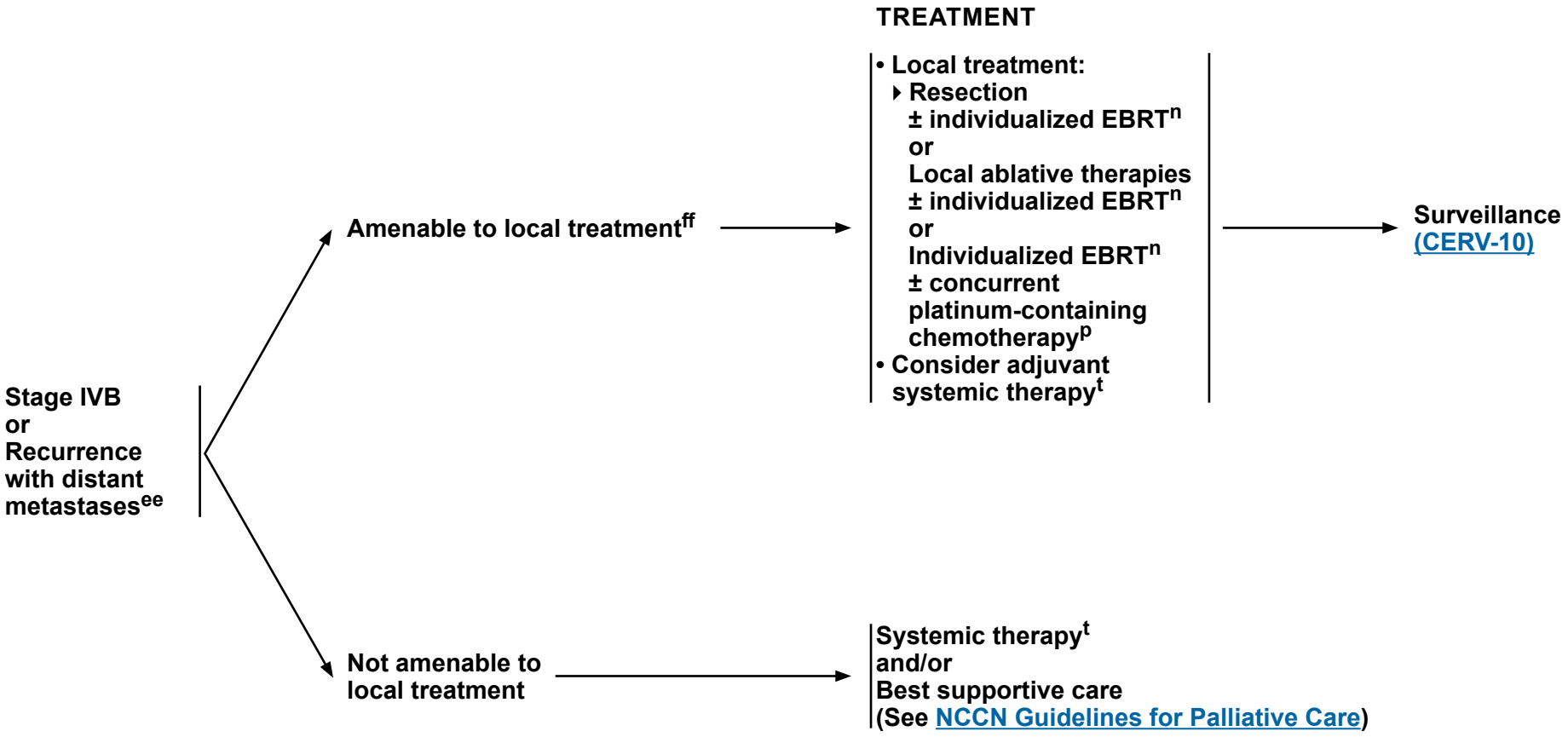

[n] Principles of Radiation Therapy (CERV-D).
[p] Concurrent platinum-containing chemotherapy with EBRT utilizes cisplatin as a single agent (or carboplatin if cisplatin intolerant). See Systemic Therapy for Cervical Cancer (CERV-F).
[t] Systemic Therapy for Cervical Cancer (CERV-F).
[ee] Consider comprehensive molecular profiling as determined by an FDA-approved assay, or a validated test performed in a CLIA-certified laboratory.
[ff] Perkins V, et al. Gynecol Oncol 2020;156:100-106.

Note: All recommendations are category 2A unless otherwise indicated.

Version 2.2026, 11/10/25 © 2025 National Comprehensive Cancer Network® (NCCN®), All rights reserved. NCCN Guidelines® and this illustration may not be reproduced in any form without the express written permission of NCCN.

PLEASE NOTE that use of this NCCN Content is governed by the End-User License Agreement, and you MAY NOT distribute this Content or use it with any artificial intelligence model or tool.
Printed by Galya Basol Kochav on 12/29/2025 12:47:39 PM. Copyright © 2025 National Comprehensive Cancer Network, Inc. All Rights Reserved.

SMALL CELL NEUROENDOCRINE CARCINOMA OF THE CERVIX (NECC)[a]

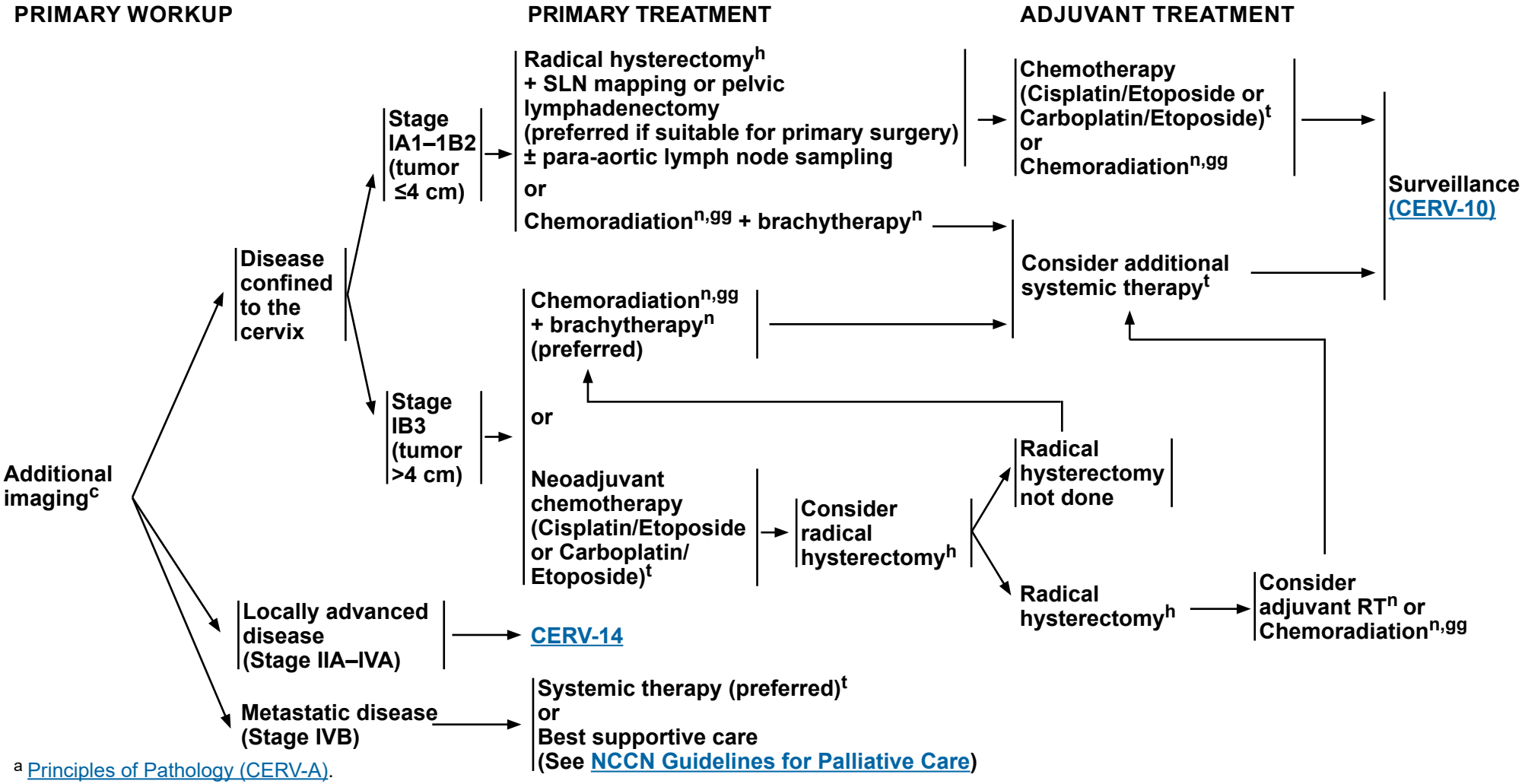

[a] Principles of Pathology (CERV-A).
[c] Principles of Imaging (CERV-B [3 of 4]).
[h] Principles of Evaluation and Surgical Staging (CERV-C).
[n] Principles of Radiation Therapy (CERV-D).
[t] Systemic Therapy for Cervical Cancer (CERV-F 2 of 4).
[gg] Concurrent platinum-containing chemotherapy with EBRT utilizes cisplatin (or carboplatin if cisplatin intolerant) + etoposide. The first two cycles of chemotherapy can be given concurrently with RT (on Days 1 and 22). The subsequent two cycles are given after RT.

Note: All recommendations are category 2A unless otherwise indicated.

Version 2.2026, 11/10/25 © 2025 National Comprehensive Cancer Network® (NCCN®), All rights reserved. NCCN Guidelines® and this illustration may not be reproduced in any form without the express written permission of NCCN.

PLEASE NOTE that use of this NCCN Content is governed by the End-User License Agreement, and you MAY NOT distribute this Content or use it with any artificial intelligence model or tool.
Printed by Galya Basol Kochav on 12/29/2025 12:47:39 PM. Copyright © 2025 National Comprehensive Cancer Network, Inc. All Rights Reserved.

SMALL CELL NEUROENDOCRINE CARCINOMA OF THE CERVIX (NECC)[a]

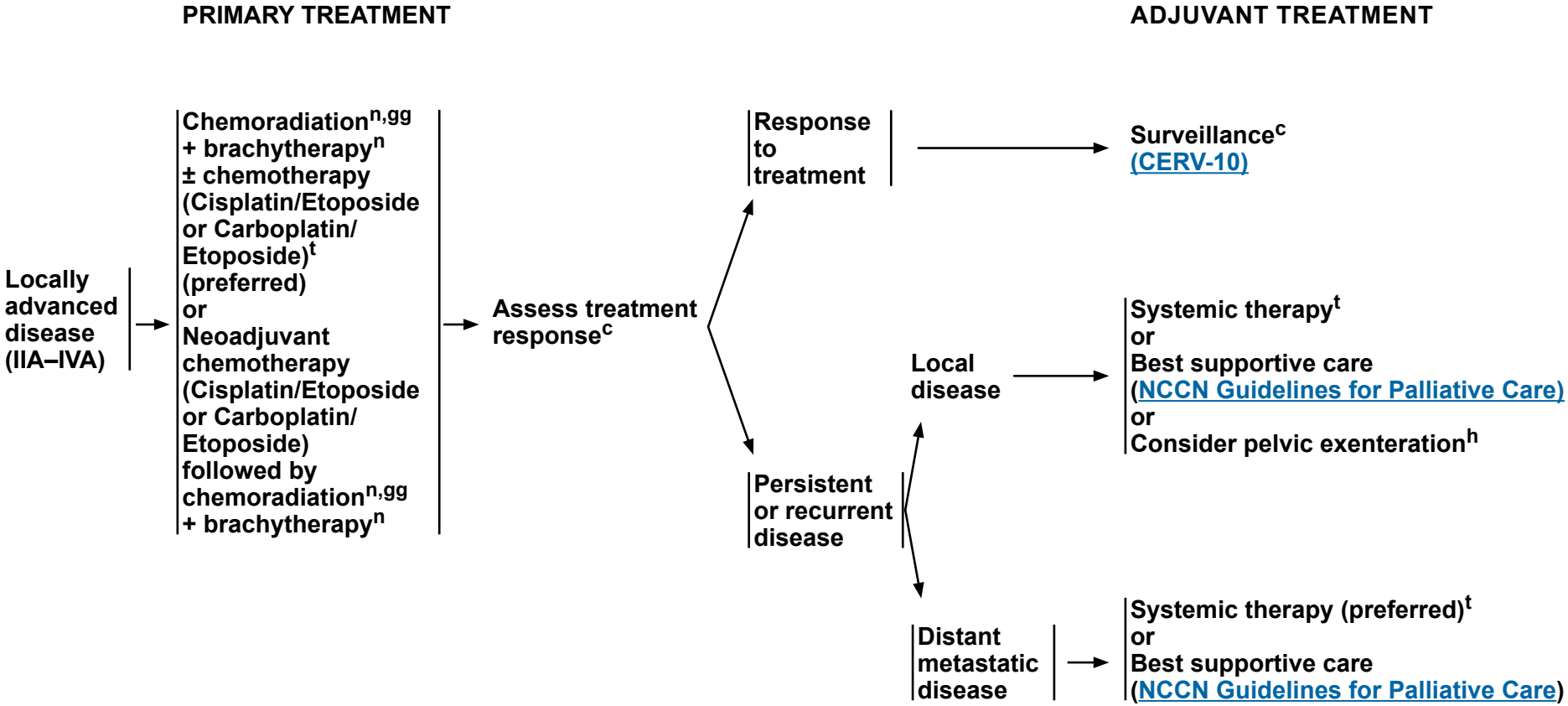

[a] Principles of Pathology (CERV-A).
[c] Principles of Imaging (CERV-B).
[h] Principles of Evaluation and Surgical Staging (CERV-C).
[n] Principles of Radiation Therapy (CERV-D).
[t] Systemic Therapy for Cervical Cancer (CERV-F 2 of 4).
[gg] Concurrent platinum-containing chemotherapy with EBRT utilizes cisplatin (or carboplatin if cisplatin intolerant) + etoposide. The first two cycles of chemotherapy can be given concurrently with RT (on Days 1 and 22). The subsequent two cycles are given after RT.

Note: All recommendations are category 2A unless otherwise indicated.

Version 2.2026, 11/10/25 © 2025 National Comprehensive Cancer Network® (NCCN®), All rights reserved. NCCN Guidelines® and this illustration may not be reproduced in any form without the express written permission of NCCN.

PLEASE NOTE that use of this NCCN Content is governed by the End-User License Agreement, and you MAY NOT distribute this Content or use it with any artificial intelligence model or tool.
Printed by Galya Basol Kochav on 12/29/2025 12:47:39 PM. Copyright © 2025 National Comprehensive Cancer Network, Inc. All Rights Reserved.

PRINCIPLES OF PATHOLOGY[1]

Squamous Cell Carcinoma, Adenocarcinoma, or Adenosquamous Carcinoma

- **Procedure**
  - **Conization, trachelectomy, Type A hysterectomy, and Type B and C radical hysterectomy**
- **Pathologic assessment:**
  - **Uterus**
    - **Hysterectomy type (where applicable)**
    - **Tumor site**
    - **Tumor size, including greatest dimension and additional two dimensions**
    - **Histologic type (HPV-associated vs. HPV-independent)[a]**
    - **Histologic grade**
    - **Stromal invasion (depth of invasion in mm/cervical wall thickness in mm)[b]**
    - **Tumor width extent in mm**
    - **Surgical resection margin status**
      - **If negative, include closest margin and distance to closest margin (in mm)[c]**
      - **If positive, include location of positive margin[c]**
    - **LVSI (does not impact FIGO 2018 staging[2])**
  - **Other tissue/organ involvement (parametrium, vaginal cuff, fallopian tubes, ovaries, peritoneum, omentum, other)**
  - **Lymph nodes (when resected)**
    - **SLNs should undergo ultrastaging for detection of low-volume metastasis[d]**
    - **Non-SLNs do not require ultrastaging and can be processed as per routine protocols**
    - **Include the number of lymph nodes with isolated tumor cells, micrometastasis, and macrometastasis**
    - **Isolated tumor cells are noted as pN0(i+)**
- **Additional molecular testing and biomarkers**
  - **Recommend programmed death ligand 1 (PD-L1) testing for patients with recurrent, progressive, or metastatic disease**
  - **Recommend human papillomavirus (HPV) status on all cervical adenocarcinomas. HPV in situ hybridization (ISH) or molecular testing is preferred, but p16 may be acceptable if HPV testing is not available.**
  - **HER2 immunohistochemistry (IHC) testing (with or without reflex to HER2 fluorescence in situ hybridization [FISH] for equivocal IHC) is recommended for advanced, metastatic, or recurrent cervical carcinoma.**
    - **Cervical carcinomas demonstrating HER2 amplification/overexpression have been associated with higher recurrence rates and worse prognosis. Testing advanced, metastatic, or recurrent cervical carcinomas may provide additional targeted anti-HER2 therapy options.**
  - **In the setting of metastatic or recurrent disease, comprehensive molecular profiling by an FDA-approved assay, or a validated test performed in a CLIA-certified laboratory including at least HER2, mismatch repair (MMR)/microsatellite instability (MSI), tumor mutational burden (TMB) testing, *NTRK*, and *RET* for predicting rare pan-tumor targeted therapy opportunities is preferred.[3,4,5]**

Footnotes for CERV-A 1 of 7

References

Note: All recommendations are category 2A unless otherwise indicated.

Version 2.2026, 11/10/25 © 2025 National Comprehensive Cancer Network® (NCCN®), All rights reserved. NCCN Guidelines® and this illustration may not be reproduced in any form without the express written permission of NCCN.

PLEASE NOTE that use of this NCCN Content is governed by the End-User License Agreement, and you MAY NOT distribute this Content or use it with any artificial intelligence model or tool.
Printed by Galya Basol Kochav on 12/29/2025 12:47:39 PM. Copyright © 2025 National Comprehensive Cancer Network, Inc. All Rights Reserved.

FOOTNOTES

[a] In addition to morphologic features (luminal mitotic figures and apoptosis) as outlined in the 2018 International Endocervical Adenocarcinoma Criteria and Classification (IECC),[6] HPV ISH, molecular testing, or p16 IHC (if HPV testing is not available) should be performed to determine HPV status and the histologic tumor type.

[b] Evaluation of histologic pattern of invasion for endocervical adenocarcinomas is an emerging concept.[7,8,9] Three clinically significant histologic patterns of invasion for endocervical adenocarcinoma have been described. Tumors with so-called pattern A invasion (defined by well-demarcated glands with round contours, an absence of single cells, an absence of desmoplastic stromal response, and no lymphatic vascular invasion) have excellent survival and do not have lymph node metastases or recurrences.[7]

[c] While reporting of this information is not required, knowledge of this information is useful for multidisciplinary treatment planning.

[d] Ultrastaging commonly entails serial sectioning of the SLN and review of multiple hematoxylin and eosin (H&E)-stained sections with or without cytokeratin IHC for all blocks of the SLN. There is not a standard protocol for lymph node ultrastaging.

References

Note: All recommendations are category 2A unless otherwise indicated.

Version 2.2026, 11/10/25 © 2025 National Comprehensive Cancer Network® (NCCN®), All rights reserved. NCCN Guidelines® and this illustration may not be reproduced in any form without the express written permission of NCCN.

PLEASE NOTE that use of this NCCN Content is governed by the End-User License Agreement, and you MAY NOT distribute this Content or use it with any artificial intelligence model or tool.
Printed by Galya Basol Kochav on 12/29/2025 12:47:39 PM. Copyright © 2025 National Comprehensive Cancer Network, Inc. All Rights Reserved.

PRINCIPLES OF PATHOLOGY

Squamous Cell Carcinoma

General Principles

- Cervical squamous cell carcinoma (SCC) is a squamous epithelial tumor with stromal invasion and/or exophytic invasion.
- It accounts for approximately 80%–90% of cervical carcinomas worldwide
- The majority of cervical SCCs (>90%) are HPV-associated, with high-risk HPV 16 and 18 being the most common types.
- HPV-independent SCC of the cervix is a relatively recently described entity, with 5%–7% of cervical SCCs reported to be HPV-negative.
- HPV-independent SCC typically present later in life (7th decade) and at an advanced stage.
- HPV-independent cervical SCCs have been described to demonstrate *TP53*, *KRAS*, *ARID1A*, and *PTEN* mutations.

Histology

- SCCs demonstrate infiltrating and angulated epithelial nests, often showing paradoxical maturation, in a background of inflammation and stromal desmoplastic response.
- Histologic patterns of SCC include keratinizing (presence of keratin pearls), non-keratinizing, basaloid (nests of basal-type squamous cells), warty (condylomatous), and papillary types.
  - Non-keratinizing and basaloid patterns are the most commonly noted with HPV-associated tumors, while HPV-independent SCC are usually of the keratinizing type.
  - Of note, morphology alone is unreliable and utility of p16 IHC and/or molecular HPV typing is recommended for establishing HPV association.
    - ◊ Almost all HPV-associated SCCs show strong and diffuse p16 overexpression in nuclei and cytoplasm by IHC.

Note: All recommendations are category 2A unless otherwise indicated.

Version 2.2026, 11/10/25 © 2025 National Comprehensive Cancer Network® (NCCN®), All rights reserved. NCCN Guidelines® and this illustration may not be reproduced in any form without the express written permission of NCCN.

PLEASE NOTE that use of this NCCN Content is governed by the End-User License Agreement, and you MAY NOT distribute this Content or use it with any artificial intelligence model or tool.
Printed by Galya Basol Kochav on 12/29/2025 12:47:39 PM. Copyright © 2025 National Comprehensive Cancer Network, Inc. All Rights Reserved.

PRINCIPLES OF PATHOLOGY

Endocervical Adenocarcinoma

General Principles

- **Endocervical adenocarcinoma is a gland-forming tumor typically originating in the transformation zone, demonstrating stromal invasion and/or expansile type invasion.**
- **Adenocarcinomas of the cervix can be HPV-associated (high-risk HPV types 18, 16, and 45 most commonly) or HPV-independent.**
- **Determining the HPV status is recommended, as HPV-associated endocervical adenocarcinomas have shown better clinical outcomes compared with HPV-independent adenocarcinomas.**
- **Grossly, endocervical adenocarcinomas may present as ulceration, exophytic masses, or as barrel-shaped cervix when endophytic growth is present.**

Note: All recommendations are category 2A unless otherwise indicated.

Version 2.2026, 11/10/25 © 2025 National Comprehensive Cancer Network® (NCCN®), All rights reserved. NCCN Guidelines® and this illustration may not be reproduced in any form without the express written permission of NCCN.

PLEASE NOTE that use of this NCCN Content is governed by the End-User License Agreement, and you MAY NOT distribute this Content or use it with any artificial intelligence model or tool.
Printed by Galya Basol Kochav on 12/29/2025 12:47:39 PM. Copyright © 2025 National Comprehensive Cancer Network, Inc. All Rights Reserved.

PRINCIPLES OF PATHOLOGY

Endocervical Adenocarcinoma (continued)

Histologic Subtypes

- **HPV-associated adenocarcinoma: Include usual type, which accounts for approximately 75% of cases and includes villoglandular and micropapillary subtypes, and mucinous types, which include intestinal, signet-ring cell, and invasive stratified mucin-producing carcinoma (ISMC).**
  - **95% of HPV-associated carcinomas will demonstrate block-type p16 expression by IHC. Of note, endometrial carcinomas (high-grade endometrioid, serous, and clear cell carcinomas) can also express p16; rarely p16-negative cases can occur from methylation-induced activation, and results of p16 were shown to be not as reproducible when performed on older or poorly preserved tissue blocks.**
  - **When available, high-risk HPV ISH can be utilized, as it is as sensitive and more specific than p16 IHC.**
  - **While polymerase chain reaction (PCR) can confirm HPV infection, it has lower sensitivity and specificity, and does not provide ascertainment that HPV is present within the neoplastic cells.**
  - **The original Silva system is utilized for evaluating patterns of invasion in HPV-associated endocervical adenocarcinoma, subdividing these tumors into three categories:**
    - **Silva Pattern A – non-destructive invasion; well-demarcated rounded glands without solid growth, single stromal cells, desmoplastic stromal response, or LVSI. These tumors have excellent survival, without lymph node metastasis or recurrence.**
    - **Silva Pattern B – localized (early) destructive stroma invasion, arising from well-demarcated glands; may show small glands or individual cells in a focally desmoplastic stroma with or without LVSI, and without solid growth.**
    - **Silva Pattern C – diffuse destructive stromal invasion, solid growth or poorly differentiated component, with or without LVSI.**
    - **Recent publications suggest combining pattern A and B without LVSI into one group and pattern B with LVSI and pattern C into a second group.[10]**
- **HPV-independent endocervical adenocarcinomas: Include gastric, clear cell, mesonephric, and endometrioid types.**
  - **Gastric type makes up approximately 10%–15% of cervical adenocarcinomas (with up to 25% noted in Japan). It is found in association with Peutz-Jeghers syndrome (*STK11* mutation), and while typically negative for p16 block expression, it may show aberrant p53 expression in approximately 50% of cases. These tumors show a high prevalence of invasion, extrauterine spread, and present at an advanced stage.**
  - **Mesonephric type demonstrates mesonephric (Wolffian) differentiation and is associated with mesonephric remnants. It typically is located deep in the lateral wall and histologically demonstrates architectural crowding, haphazard infiltration, atypia, mitotic activity, and necrosis. GATA-3 and CD10 IHC stains will be positive in the tumor and associated mesonephric remnants.**
  - **Clear cell carcinomas make up 3%[10] of endocervical adenocarcinomas, occurring sporadically or in association with in-utero diethylstilbestrol (DES) exposure. These tumors may demonstrate diffuse p16 expression despite the absence of HPV infection. In these instances, high-risk HPV ISH can be utilized.**
  - **Endometrioid carcinoma is quite uncommon, approximating 1% of primary endocervical adenocarcinomas, and may present in the setting of endometriosis; however, a primary endometrial carcinoma must be ruled out.**
    - **Utilizing a panel of IHC stains (vimentin, estrogen receptor [ER], p16, and monoclonal carcinoembryonic antigen [CEA]) may be helpful in differentiating between endocervical and endometrial carcinoma. Typically, endometrioid adenocarcinoma will express vimentin and ER, while endocervical adenocarcinoma is positive for monoclonal CEA and p16 (when HPV-associated).**

Note: All recommendations are category 2A unless otherwise indicated.

Version 2.2026, 11/10/25 © 2025 National Comprehensive Cancer Network® (NCCN®), All rights reserved. NCCN Guidelines® and this illustration may not be reproduced in any form without the express written permission of NCCN.

PLEASE NOTE that use of this NCCN Content is governed by the End-User License Agreement, and you MAY NOT distribute this Content or use it with any artificial intelligence model or tool.
Printed by Galya Basol Kochav on 12/29/2025 12:47:39 PM. Copyright © 2025 National Comprehensive Cancer Network, Inc. All Rights Reserved.

PRINCIPLES OF PATHOLOGY

Adenosquamous Carcinoma

General Principles
- Epithelial tumor with malignant squamous and malignant glandular differentiation
- Accounts for approximately 5%–6% of all cervical carcinomas
- Clinical outcomes are similar to cervical adenocarcinoma

Histology
- The tumor components (squamous and glandular) should be admixed and be able to be discerned on routine histology
- The squamous component typically demonstrates abundant glycogen-rich (clear) cytoplasm, while the gland-forming component is often of usual HPV-associated adenocarcinoma

Immunohistochemistry (IHC)
- IHC for p16 usually shows overexpression in both components
- Additional IHC stains such as CK7, CEA, and PAX8 may be utilized to highlight the glandular component, while p63 and p40 highlight the squamous component

Note: All recommendations are category 2A unless otherwise indicated.

Version 2.2026, 11/10/25 © 2025 National Comprehensive Cancer Network® (NCCN®), All rights reserved. NCCN Guidelines® and this illustration may not be reproduced in any form without the express written permission of NCCN.

PLEASE NOTE that use of this NCCN Content is governed by the End-User License Agreement, and you MAY NOT distribute this Content or use it with any artificial intelligence model or tool.
Printed by Galya Basol Kochav on 12/29/2025 12:47:39 PM. Copyright © 2025 National Comprehensive Cancer Network, Inc. All Rights Reserved.

PRINCIPLES OF PATHOLOGY[11-15]

Neuroendocrine Carcinoma of the Cervix (NECC)

- **Histologic description**
  - **Although rare, comprising <5% of cervical cancers, the cervix is the most common site for neuroendocrine carcinoma (eg, small cell and large cell neuroendocrine carcinoma) in the genital tract.**
  - **NECC is clinically aggressive, with rapid metastasis and a frequently poor clinical outcome.**
  - **NECC is usually HPV-associated; types 16 and 18 are the most common (18 more often than 16).**
  - **This carcinoma type morphologically resembles neuroendocrine carcinomas of the lung.**
  - **Small cell NECC is a morphologic diagnosis.**
  - **The predominant growth pattern is diffuse. Additional growth patterns include insular (solid nests/islands of cells with peripheral palisading and retraction of stroma), as well as perivascular and thick trabeculae with serpiginous (wavy) growth. Pseudoglandular and rosette-like structures are variably present.**
  - **Cytologic features include a uniform population of cells with indistinct cell borders, scant cytoplasm, and hyperchromatic nuclei with fine granular chromatin. Abundant mitotic activity and apoptotic debris is common. Nuclear molding and indistinct nucleoli are additional features. Necrosis is common.**
  - **Associated cervical glandular lesions (pre- or overtly malignant) may be seen. Consider diagnoses such as adenocarcinoma mixed with neuroendocrine carcinoma as appropriate.**
  - **Differentiating between small cell and large cell NECC may be difficult.**

- **Immunohistochemistry (IHC)**
  - **Small cell NECC is variably positive for chromogranin, CD56, and synaptophysin.**
    - ◊ **CD56 and synaptophysin are the most sensitive neuroendocrine markers, but CD56 lacks specificity.**
    - ◊ **Chromogranin is the most specific neuroendocrine marker, but lacks sensitivity with only about 50%–60% of small cell NECC being positive.[16,17]**
    - ◊ **Insulinoma-associated protein 1 (INSM1) and synaptophysin are other neuroendocrine markers, with 80% and 70% positivity, respectively.[16,17]**
  - **While these IHC markers are not always expressed in all tumors, they should be performed in the diagnostic workup of NECC. Even when negative, the diagnosis of NECC can be made if classic morphologic features are present (this is NOT true for large cell NECC).[e]**
    - ◊ **In the setting of IHC-negative or suspected IHC-negative small cell NECC, expert pathologic review is recommended.**
  - **Small cell NECC may be only focally positive (often punctate cytoplasmic staining) or even negative with broad-spectrum cytokeratins.**
  - **A high percentage of primary NECCs are thyroid transcription factor-1 (TTF-1)-positive, including some with diffuse immunoreactivity, and this marker is of no value in distinction from a pulmonary metastasis.**
  - **Most NECCs are diffusely positive for p16 due to the presence of high-risk HPV. However, p16 positivity cannot be used to aid in determining the site of origin; neuroendocrine carcinomas arising at other sites may strongly express p16 due to a non-HPV–related process. Consider HPV ISH or PCR testing.**
  - **Peptide hormones, including adrenocorticotropic hormone (ACTH), serotonin, somatostatin, calcitonin, glucagon, and gastrin, have been demonstrated in some high-grade NECCs.**

[e] Given the rarity of small cell NECC, there are currently no well-established management guidelines.

References

Note: All recommendations are category 2A unless otherwise indicated.

Version 2.2026, 11/10/25 © 2025 National Comprehensive Cancer Network® (NCCN®), All rights reserved. NCCN Guidelines® and this illustration may not be reproduced in any form without the express written permission of NCCN.

PLEASE NOTE that use of this NCCN Content is governed by the End-User License Agreement, and you MAY NOT distribute this Content or use it with any artificial intelligence model or tool.
Printed by Galya Basol Kochav on 12/29/2025 12:47:39 PM. Copyright © 2025 National Comprehensive Cancer Network, Inc. All Rights Reserved.

PRINCIPLES OF PATHOLOGY
REFERENCES

[1] Krishnamurti U, Movahedi-Lankarani S, Bell DA, et al. Protocol for the Examination of Specimens from Patients with Primary Carcinoma of the Uterine Cervix. College of American Pathologists 2018.
[2] Bhatla N, Berek JS, Fredes MC, et al. Revised FIGO Staging for carcinoma of the cervix uteri. Int J Gynecol Obstet 2019;145:129-135 and Corrigendum to "Revised FIGO Staging for carcinoma of the cervix uteri" [Int J Gynecol Obstet 2019;145:129-135] Int J Gynecol Obstet 2019;147:279-280.
[3] Minion LE, Tewari KS. Cervical cancer - State of science: From angiogenesis blockade to checkpoint inhibition. Gynecol Oncol 2018;148:609-621.
[4] Chung HC, Ros W, Delord JP, et al. Efficacy and Safety of Pembrolizumab in Previously Treated Advanced Cervical Cancer: Results From the Phase II KEYNOTE-158 Study. J Clin Oncol 2019;37:1470-1478.
[5] Merino DM, McShane LM, Fabrizio D, et al. Establishing guidelines to harmonize tumor mutational burden (TMB): in silico assessment of variation in TMB quantification across diagnostic platforms: phase I of the Friends of Cancer Research TMB Harmonization Project. J Immunother Cancer 2020;8:e000147.
[6] Stolnicu S, Barsan I, Hoang L, et al. International Endocervical Adenocarcinoma Criteria and Classification (IECC): A new pathogenetic classification for invasive adenocarcinomas of the endocervix. Am J Surg Pathol 2018;42:214-226.
[7] Diaz De Vivar A, Roma AA, Park KJ, et al. Invasive endocervical adenocarcinoma: proposal for a new pattern-based classification system with significant clinical implications: a multi-institutional study. Int J Gynecol Pathol 2013;32:592-601.
[8] Roma AA, Mistretta TA, Diaz De Vivar A, et al. New pattern-based personalized risk stratification system for endocervical adenocarcinoma with important clinical implications and surgical outcome. Gynecol Oncol 2016;141:36-42.
[9] Spaans VM, Scheunhage DA, Barzaghi B, et al. Independent validation of the prognostic significance of invasion patterns in endocervical adenocarcinoma: Pattern A predicts excellent survival. Gynecol Oncol 2018;151:196-201.
[10] Stolnicu S, Hoang L, Almadani N, et al. Clinical correlation of lymphovascular invasion and Silva pattern of invasion in early-stage endocervical adenocarcinoma: proposed binary Silva classification system. Pathology. 2022;54:548-554.
[11] Rindi G, Klimstra DS, Abedi-Ardekani B, et al. A common classification framework for neuroendocrine neoplasms: an International Agency for Research on Cancer (IARC) and World Health Organization (WHO) expert consensus proposal. Mod Pathol 2018;31:1770-1786.
[12] Howitt BE, Kelly P, McCluggage WG. Pathology of neuroendocrine tumours of the female genital tract. Curr Oncol Rep 2017;19:59.
[13] Ganesan R, Hirschowitz L, Dawson P, et al. Neuroendocrine carcinoma of the cervix: Review of a series of cases and correlation with outcome. Int J Surg Pathol 2016;24:490-496.
[14] Perunovic B, Sunassee A. Small cell (neuroendocrine/undifferentiated) carcinoma. PathologyOutlines.com website. Available at: http://www.pathologyoutlines.com/topic/cervixsmallcell.html.
[15] Chao A, Wu RC, Lin CY, Small cell neuroendocrine carcinoma of the cervix: From molecular basis to therapeutic advances. Biomed J 2023;46:100633.
[16] Wang HL, Lu DW. Detection of human papillomavirus DNA and expression of p16, Rb, and p53 proteins in small cell carcinomas of the uterine cervix. Am J Surg Pathol 2004;28:901-908.
[17] Masumoto N, Fujii T, Ishikawa M, et al. P16 overexpression and human papillomavirus infection in small cell carcinoma of the uterine cervix. Hum Pathol 2003;34:778-783.

Note: All recommendations are category 2A unless otherwise indicated.

Version 2.2026, 11/10/25 © 2025 National Comprehensive Cancer Network® (NCCN®), All rights reserved. NCCN Guidelines® and this illustration may not be reproduced in any form without the express written permission of NCCN.

PLEASE NOTE that use of this NCCN Content is governed by the End-User License Agreement, and you MAY NOT distribute this Content or use it with any artificial intelligence model or tool.
Printed by Galya Basol Kochav on 12/29/2025 12:47:39 PM. Copyright © 2025 National Comprehensive Cancer Network, Inc. All Rights Reserved.

PRINCIPLES OF IMAGING[a,1-9]

Initial Workup

- **Stage I**
  - **Non-Fertility Sparing**
    - ◊ **Pelvis MRI recommended if considering definitive treatment with a conization, trachelectomy, or Type A hysterectomy.**
    - ◊ **Consider pelvis MRI to assess local disease extent (preferred for FIGO stage IB1–IB3).**
    - ◊ **Neck/chest/abdomen/pelvis/groin FDG-PET/CT (preferred) or chest/abdomen/pelvis CT or FDG-PET/MRI for FIGO stage IB1–IB3.**
    - ◊ **For patients who underwent TH with incidental finding of cervical cancer, consider neck/chest/abdomen/pelvis/groin FDG-PET/CT or chest/abdomen/pelvis CT to evaluate for metastatic disease and pelvis MRI to assess pelvic residual disease.**
    - ◊ **Other imaging should be based on symptomatology and clinical concern for metastatic disease.[b]**
  - **Fertility Sparing**
    - ◊ **Pelvis MRI (preferred) to assess local disease extent and proximity of tumor to internal cervical os; perform pelvic transvaginal ultrasound if MRI is contraindicated.**
    - ◊ **Neck/chest/abdomen/pelvis/groin FDG-PET/CT (preferred) or chest/abdomen/pelvis CT in FIGO stage IB1–IB3.**
    - ◊ **Consider chest CT with or without contrast.**
    - ◊ **Other imaging should be based on symptomatology and clinical concern for metastatic disease.[b]**

- **Stage II–IVA**
  - **Pelvis MRI to assess local disease extent (preferred).**
  - **Neck/chest/abdomen/pelvis/groin FDG-PET/CT (preferred) or chest/abdomen/pelvis CT to evaluate for metastatic disease.**
  - **Other initial imaging should be based on symptomatology and clinical concern for metastatic disease.[c]**
  - **For patients who underwent TH with incidental finding of cervical cancer, consider neck/chest/abdomen/pelvis/groin FDG-PET/CT or chest/abdomen/pelvis CT to evaluate for metastatic disease and pelvis MRI to assess pelvic residual disease.**
  - **If first post-treatment FDG-PET/CT is indeterminate, then consider repeating in 3 months.**

[a] MRI is performed with and without contrast and CT is performed with contrast unless contraindicated. Although contrast is not required for screening chest CT, it may be performed with or without contrast during initial workup for fertility sparing.
[b] These factors may include abnormal physical exam findings or pelvic, abdominal, or pulmonary symptoms.
[c] These factors may include abnormal physical exam findings, bulky pelvic tumor (>4 cm), delay in presentation or treatment, and pelvic, abdominal, or pulmonary symptoms.

Note: All recommendations are category 2A unless otherwise indicated.

References

Version 2.2026, 11/10/25 © 2025 National Comprehensive Cancer Network® (NCCN®), All rights reserved. NCCN Guidelines® and this illustration may not be reproduced in any form without the express written permission of NCCN.

PLEASE NOTE that use of this NCCN Content is governed by the End-User License Agreement, and you MAY NOT distribute this Content or use it with any artificial intelligence model or tool.
Printed by Galya Basol Kochav on 12/29/2025 12:47:39 PM. Copyright © 2025 National Comprehensive Cancer Network, Inc. All Rights Reserved.

PRINCIPLES OF IMAGING[a,1-9]

Follow-up/Surveillance

- **Stage I**
  - **Non-Fertility Sparing**
    - ◊ **Imaging should be based on symptomatology and clinical concern for recurrent/metastatic disease.[b]**
    - ◊ **For patients with FIGO stage IB3 or patients who required postoperative adjuvant radiation or chemoradiation due to high-risk factors,[d] a neck/chest/abdomen/pelvis/groin FDG-PET/CT may be performed at 3–6 months after completion of treatment.**
  - **Fertility Sparing**
    - ◊ **Consider pelvis MRI 6 months after surgery and then yearly for 2–3 years.**
    - ◊ **Other imaging should be based on symptomatology and clinical concern for recurrent/metastatic disease.[b]**

- **Stage II–IV**
  - **Neck/chest/abdomen/pelvis/groin FDG-PET/CT (preferred) or chest/abdomen/pelvis CT within 3–6 months of completion of therapy.**
  - **Consider pelvis MRI at 3–6 months post completion of therapy.**
  - **Other imaging should be based on symptomatology and clinical concern for recurrent/metastatic disease.[e]**

- **Stage IVB or Recurrence**
  - **Imaging as appropriate (CT, MRI, or FDG-PET/CT) to assess response or determine further therapy.**

- **If first post-treatment FDG-PET/CT is indeterminate, then consider repeating in 3 months.**

Suspected Recurrence or Metastasis

- **Neck/chest/abdomen/pelvis/groin FDG-PET/CT.**
- **Consider pelvis MRI.**

[a] MRI is performed with and without contrast and CT is performed with contrast unless contraindicated. Although contrast is not required for screening chest CT, it may be performed with or without contrast during initial workup for fertility sparing.
[b] These factors may include abnormal physical exam findings or pelvic, abdominal, or pulmonary symptoms.
[d] Risk factors may include positive nodes, positive parametria, positive margins, or local cervical factors (see GOG/Sedlis Criteria [CERV-E]).
[e] These factors may include abnormal physical exam findings such as palpable mass or adenopathy, or new pelvic, abdominal, or pulmonary symptoms.

Note: All recommendations are category 2A unless otherwise indicated.

References

Version 2.2026, 11/10/25 © 2025 National Comprehensive Cancer Network® (NCCN®), All rights reserved. NCCN Guidelines® and this illustration may not be reproduced in any form without the express written permission of NCCN.

PLEASE NOTE that use of this NCCN Content is governed by the End-User License Agreement, and you MAY NOT distribute this Content or use it with any artificial intelligence model or tool.
Printed by Galya Basol Kochav on 12/29/2025 12:47:39 PM. Copyright © 2025 National Comprehensive Cancer Network, Inc. All Rights Reserved.

PRINCIPLES OF IMAGING[a,1-9]

Small Cell NECC

- **Additional Imaging**
  - **Neck/chest/abdomen/pelvis/groin FDG-PET/CT + brain MRI (preferred)**
    or
  - **Chest/abdomen/pelvis CT + brain MRI**

- **Treatment Response Assessment**
  - **If primary treatment is chemoradiation, then neck/chest/abdomen/pelvis/groin FDG-PET/CT ± brain MRI (preferred) or chest/abdomen/pelvis CT ± brain MRI**
  - **If neoadjuvant chemotherapy is used, consider reassessment to rule out metastatic disease prior to chemoradiation and brachytherapy**

- **Surveillance**
  - **Neck/chest/abdomen/pelvis/groin FDG-PET/CT ± brain MRI (preferred)**
    or
  - **Chest/abdomen/pelvis CT ± brain MRI**

[a] MRI is performed with and without contrast and CT is performed with contrast unless contraindicated. Although contrast is not required for screening chest CT, it may be performed with or without contrast during initial workup for fertility sparing.

Note: All recommendations are category 2A unless otherwise indicated.

References

Version 2.2026, 11/10/25 © 2025 National Comprehensive Cancer Network® (NCCN®), All rights reserved. NCCN Guidelines® and this illustration may not be reproduced in any form without the express written permission of NCCN.

PLEASE NOTE that use of this NCCN Content is governed by the End-User License Agreement, and you MAY NOT distribute this Content or use it with any artificial intelligence model or tool.
Printed by Galya Basol Kochav on 12/29/2025 12:47:39 PM. Copyright © 2025 National Comprehensive Cancer Network, Inc. All Rights Reserved.

PRINCIPLES OF IMAGING
REFERENCES

[1] Salani R, Khanna N, Frimer M, et al. An update on post-treatment surveillance and diagnosis of recurrence in women with gynecologic malignancies: Society of Gynecologic Oncology (SGO) recommendations. Gynecol Oncol 2017;146:3-10.
[2] Atri M, Zhang Z, Dehdashti F, et al. Utility of PET-CT to evaluate retroperitoneal lymph node metastasis in advanced cervical cancer: Results of ACRIN6671/GOG0233 trial. Gynecol Oncol 2016;142:413-419.
[3] Rajendran JG, Greer BE. Expanding role of positron emission tomography in cancer of the uterine cervix. J Natl Compr Canc Netw 2006;4:463-469.
[4] Lakhman Y, Akin O, Park KJ, et al. Stage IB1 cervical cancer: role of preoperative MR imaging in selection of patients for fertility-sparing radical trachelectomy. Radiology 2013;269:149-158.
[5] Elit L, Reade CJ. Recommendations for follow-up care for gynecologic cancer survivors. Obstet Gynecol 2015;126:1207-1214.
[6] Sala E, Rockall AG, Freeman SJ, et al. The added role of MR imaging in treatment stratification of patients with gynecologic malignancies: what the radiologist needs to know. Radiology 2013;266:717-740.
[7] Balleyguier C, Sala E, Da Cunha T, et al. Staging of uterine cervical cancer with MRI: guidelines of the European Society of Urogenital Radiology. Eur Radiol 2011;21:1102-1110.
[8] Sala E, Micco M, Burger IA, et al. Complementary prognostic value of pelvic MRI and whole-body FDG PET/CT in the pretreatment assessment of patients with cervical cancer. Int J Gynecol Cancer 2015;25:1461-1467.
[9] Bhatla N, Berek JS, Fredes MC, et al. Revised FIGO Staging for carcinoma of the cervix uteri. Int J Gynecol Obstet 2019;145:129-135 and Corrigendum to "Revised FIGO Staging for carcinoma of the cervix uteri" [Int J Gynecol Obstet 2019;145:129-135] Int J Gynecol Obstet 2019;147:279-280.

Note: All recommendations are category 2A unless otherwise indicated.

Version 2.2026, 11/10/25 © 2025 National Comprehensive Cancer Network® (NCCN®), All rights reserved. NCCN Guidelines® and this illustration may not be reproduced in any form without the express written permission of NCCN.

PLEASE NOTE that use of this NCCN Content is governed by the End-User License Agreement, and you MAY NOT distribute this Content or use it with any artificial intelligence model or tool.
Printed by Galya Basol Kochav on 12/29/2025 12:47:39 PM. Copyright © 2025 National Comprehensive Cancer Network, Inc. All Rights Reserved.

PRINCIPLES OF EVALUATION AND SURGICAL STAGING[a]

Types of Resection and Appropriateness for Treatment of Cervical Cancer

- **Treatment of cervical cancer is stratified by stage as delineated in the Guidelines.**
- **Microinvasive disease, defined as FIGO stage IA1 with no LVSI, has a <1% chance of lymphatic metastasis and may be managed conservatively with cone biopsy for preservation of fertility (with negative margins) or with simple hysterectomy when preservation of fertility is not desired or relevant. The intent of a cone biopsy is to remove the ectocervix and endocervical canal en bloc using a scalpel. This provides the pathologist with an intact, non-fragmented specimen without electrosurgical artifact, which facilitates margin status evaluation. If a loop electrosurgical excision procedure (LEEP) is chosen for treatment, the specimen should not be fragmented, and care must be undertaken to minimize electrosurgical artifact at the margins. The shape and depth of the cone biopsy may be tailored to the size, type, and location of the neoplastic lesion. For example, if there is concern for invasive adenocarcinoma versus adenocarcinoma in situ in the cervical canal, the cone biopsy would be designed as a narrow, long cone extending to the internal os in order not to miss possible invasion in the endocervical canal. Length of the cold cone of at least 10 mm is preferred and can be increased to 18–20 mm in patients who have completed childbearing.[1] Endocervical sampling above the cone apex to evaluate for residual disease is recommended, except during pregnancy. Cone biopsy is indicated for triage and treatment of small cancers where there is no likelihood of cutting across gross neoplasm. In cases of stage IA1 with LVSI and desire to preserve fertility, a conization (with negative margins) with pelvic SLN mapping/ lymphadenectomy is a reasonable strategy.**
- **For select patients with stage IA2–IB1 who desire fertility preservation, a conization with negative margins with negative bilateral pelvic SLN or lymphadenectomy is a reasonable strategy if the patient meets all the following conservative surgery criteria[2]:**
  - **Cone biopsy with negative margins for cancer**
  - **No LVSI (preferred)**
  - **Squamous cell cancer (any grade) or usual type adenocarcinoma (grade 1 or 2) (preferred)**
  - **Tumor size ≤2 cm**
  - **Depth of invasion ≤10 mm on LEEP/cone**
  - **Negative imaging for locoregional disease (MRI recommended)**
- **The radical vaginal trachelectomy with laparoscopic SLN mapping or lymphadenectomy offers a fertility-sparing option for carefully selected individuals with stage IA2 or stage IB1 lesions (<2 cm diameter). The cervix, 1–2 cm upper vagina, and supporting ligaments are removed as with a Type B radical hysterectomy, but the uterine corpus is preserved. In >300 subsequent pregnancies currently reported, there is a 10% likelihood of second trimester loss, but 72% of patients carry their gestation to ≥37 weeks.[3] The abdominal radical trachelectomy is a reasonable fertility-sparing strategy. It provides larger resection of parametria than the vaginal approach,[4] is suitable for select stage IB1–IB2 cases, and has been utilized in lesions between 2–4 cm in diameter. The operation mimics a Type C1 radical hysterectomy.[b,4-10]**

[a] Recommendations by stage are based on the revised 2018 FIGO staging (Bhatla N, Berek JS, Fredes MC, et al. Revised FIGO Staging for carcinoma of the cervix uteri. Int J Gynecol Obstet 2019;145:129-135 and Corrigendum to "Revised FIGO Staging for carcinoma of the cervix uteri" [Int J Gynecol Obstet 2019;145:129-135] Int J Gynecol Obstet 2019;147:279-280). However, trial data cited within this section utilized the 2009 FIGO staging system.
[b] For a description of a Type C1 radical hysterectomy, see Table 1 (CERV-C 6 of 9).

Note: All recommendations are category 2A unless otherwise indicated.

References

Version 2.2026, 11/10/25 © 2025 National Comprehensive Cancer Network® (NCCN®), All rights reserved. NCCN Guidelines® and this illustration may not be reproduced in any form without the express written permission of NCCN.

PLEASE NOTE that use of this NCCN Content is governed by the End-User License Agreement, and you MAY NOT distribute this Content or use it with any artificial intelligence model or tool.
Printed by Galya Basol Kochav on 12/29/2025 12:47:39 PM. Copyright © 2025 National Comprehensive Cancer Network, Inc. All Rights Reserved.

PRINCIPLES OF EVALUATION AND SURGICAL STAGING[a]

Types of Resection and Appropriateness for Treatment of Cervical Cancer

- **Radical hysterectomy with bilateral pelvic SLN mapping or lymphadenectomy is a treatment option for FIGO stage IA2, IB1, IB2, and select IB3–IIA1 lesions when fertility preservation is not desired. Radical hysterectomy (Type B or C) results in resection of much wider margins compared with a simple Type A hysterectomy, including removal of parts of the paracervix and uterosacral ligaments and the upper 1–2 cm of the vagina; in addition, pelvic and sometimes para-aortic nodes are removed. The Querleu and Morrow classification system[5] is a modern surgical classification that describes degree of resection and nerve preservation in three-dimensional (3D) planes of resection.[6] Procedural details for the most commonly used types of hysterectomy are described in Table 1 (CERV-C 6 of 9).**
- **The standard and recommended approach for radical hysterectomy is with an open abdominal approach (category 1). A prospective randomized trial[10] demonstrated that minimally invasive radical hysterectomy was associated with lower rates of disease-free survival (DFS) and overall survival than open abdominal radical hysterectomy. Moreover, two recent epidemiologic studies also demonstrated that minimally invasive radical hysterectomy was associated with shorter overall survival than open surgery among patients with stage IA2–IB1 cervical cancer.[11] See Discussion for additional details. Studies comparing robotic versus open approach are ongoing.**
- **Based on a randomized trial comparing simple to radical hysterectomy,[12] select patients with stage IA2–IB1 disease who meet all the conservative surgery criteria listed below may be treated with a simple Type A hysterectomy with SLN mapping or bilateral pelvic lymphadenectomy:**
  - **Cone biopsy (preferred)**
  - **No LVSI (preferred)**
  - **Negative cone margins for cancer (preferred)**
  - **Squamous cell (any grade) or usual type adenocarcinoma (grade 1 or 2) (preferred)**
  - **Tumor size ≤2 cm**
  - **Depth of invasion <10 mm on cone. If no conization, MRI must show <50% cervical stromal invasion**
  - **Negative imaging for metastatic disease (MRI recommended)**
- **Definitive treatment with a conization or Type A hysterectomy has not been studied in the more aggressive histologies such as gastric type adenocarcinoma, clear cell, and small cell neuroendocrine carcinoma.**

[a] Recommendations by stage are based on the revised 2018 FIGO staging (Bhatla N, Berek JS, Fredes MC, et al. Revised FIGO Staging for carcinoma of the cervix uteri. Int J Gynecol Obstet 2019;145:129-135 and Corrigendum to "Revised FIGO Staging for carcinoma of the cervix uteri" [Int J Gynecol Obstet 2019;145:129-135] Int J Gynecol Obstet 2019;147:279-280). However, trial data cited within this section utilized the 2009 FIGO staging system.

Note: All recommendations are category 2A unless otherwise indicated.

References

Version 2.2026, 11/10/25 © 2025 National Comprehensive Cancer Network® (NCCN®), All rights reserved. NCCN Guidelines® and this illustration may not be reproduced in any form without the express written permission of NCCN.

PLEASE NOTE that use of this NCCN Content is governed by the End-User License Agreement, and you MAY NOT distribute this Content or use it with any artificial intelligence model or tool.
Printed by Galya Basol Kochav on 12/29/2025 12:47:39 PM. Copyright © 2025 National Comprehensive Cancer Network, Inc. All Rights Reserved.

PRINCIPLES OF EVALUATION AND SURGICAL STAGING[a]

Types of Resection and Appropriateness for Treatment of Cervical Cancer — continued

- **Para-aortic lymphadenectomy for staging is typically done to the level of the inferior mesenteric artery (IMA). The cephalad extent of dissection can be modified based on clinical and radiologic findings.**
- **Ovarian preservation or ovarian transposition outside of pelvic radiation boundaries should be considered when feasible to avoid surgical or radiation-induced menopause.**
- **Advanced-stage disease, including FIGO stage IIB and above, is not usually treated with hysterectomy, as delineated in the Guidelines. The majority of advanced-stage disease in the United States is treated with definitive chemoradiation. In some countries, select cases of stage IIB may be treated with upfront radical hysterectomy or neoadjuvant chemotherapy followed by radical hysterectomy.**
- **Recurrent or persistent disease in the central pelvis following RT may potentially be cured with the pelvic exenteration procedure. Preoperative assessment for exenteration is designed to identify or rule out distant metastasis. If the recurrence is confined to the pelvis (preferable central pelvic), then surgical exploration is carried out. If intraoperative margin and node assessment appear negative, then resection of pelvic viscera is completed. Depending on the location of the tumor, resection may include anterior exenteration, posterior exenteration, or total pelvic exenteration. In cases where the location of tumor allows for adequate margins, the pelvic floor and anal sphincter may be preserved as a supralevator exenteration. Table 2 summarizes the tissues typically removed with differing types of pelvic exenteration (CERV-C 8 of 9). These are highly complex procedures and should be performed at centers with a high level of expertise for exenteration procedures. Primary pelvic exenteration (without prior pelvic radiation) is restricted to the rare case where pelvic radiation is contraindicated or to patients who received prior pelvic radiation for another indication and then developed a metachronous, locally advanced cervical carcinoma and further RT is not feasible.**
- **In very select cases where there is documented evidence of persistent or recurrent small volume cervical disease (<2 cm) after radiation/chemoradiation and no metastatic disease, a radical hysterectomy instead of pelvic exenteration may be considered. The operation that is most likely to obtain a negative margin should be prioritized.**

[a] Recommendations by stage are based on the revised 2018 FIGO staging (Bhatla N, Berek JS, Fredes MC, et al. Revised FIGO Staging for carcinoma of the cervix uteri. Int J Gynecol Obstet 2019;145:129-135 and Corrigendum to "Revised FIGO Staging for carcinoma of the cervix uteri" [Int J Gynecol Obstet 2019;145:129-135] Int J Gynecol Obstet 2019;147:279-280). However, trial data cited within this section utilized the 2009 FIGO staging system.

Note: All recommendations are category 2A unless otherwise indicated.

Version 2.2026, 11/10/25 © 2025 National Comprehensive Cancer Network® (NCCN®), All rights reserved. NCCN Guidelines® and this illustration may not be reproduced in any form without the express written permission of NCCN.

PLEASE NOTE that use of this NCCN Content is governed by the End-User License Agreement, and you MAY NOT distribute this Content or use it with any artificial intelligence model or tool.
Printed by Galya Basol Kochav on 12/29/2025 12:47:39 PM. Copyright © 2025 National Comprehensive Cancer Network, Inc. All Rights Reserved.

PRINCIPLES OF EVALUATION AND SURGICAL STAGING[a,c]

Sentinel Lymph Node Mapping for Cervical Cancer:

- **SLN mapping as part of the surgical management of select stage I cervical cancer is considered in gynecologic oncology practices worldwide. While this technique has been used in tumors ≤4 cm in size, the best detection rates and mapping results are in tumors <2 cm.[13-17] This simple technique utilizes a direct cervical injection with dye[d] or radiocolloid technetium-99m (99mTc) into the cervix, usually at 2 or 4 points as shown in Figure 1 (below). The SLNs are identified at the time of surgery with direct visualization of colored dye; a fluorescent camera is used if indocyanine green (ICG)[18] was used, and a gamma probe is used if 99mTc was used. SLNs following a cervical injection are commonly located medial to the external iliac vessels, ventral to the hypogastric vessels, or in the superior part of the obturator space (Figure 2). SLNs usually undergo ultrastaging by pathologists, which allows for higher detection of micrometastasis that may alter postoperative management.[10,19]**

Figure 1: Options of SLN Cervical Injection Sites[d]

Figure 2: SLNs (blue, arrow) After Cervical Injection Are Commonly Located Medial to the External Iliac, Ventral to the Hypogastric, or in the Superior Part of the Obturator Space[d]

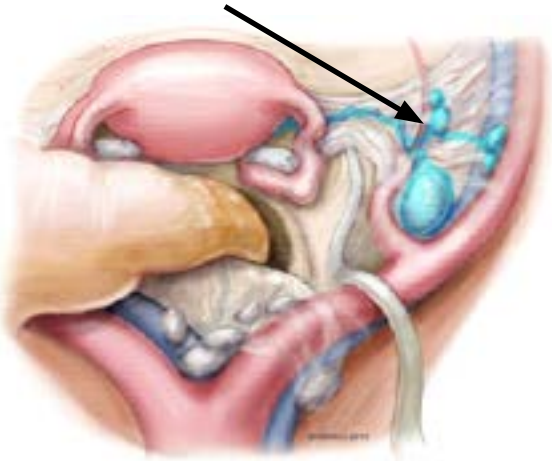

[a] Recommendations by stage are based on the revised 2018 FIGO staging (Bhatla N, Berek JS, Fredes MC, et al. Revised FIGO Staging for carcinoma of the cervix uteri. Int J Gynecol Obstet 2019;145:129-135 and Corrigendum to "Revised FIGO Staging for carcinoma of the cervix uteri" [Int J Gynecol Obstet 2019;145:129-135] Int J Gynecol Obstet 2019;147:279-280). However, trial data cited within this section utilized the 2009 FIGO staging system.
[c] Figures 1 and 2 are reproduced with permission from Memorial Sloan Kettering Cancer Center. © 2013 Memorial Sloan Kettering Cancer Center.
[d] In the phase III randomized FILM trial, ICG was shown to be superior to isosulfan blue dye [Frumovitz M, Plante M, Lee PS, et al. Near-infrared fluorescence for detection of sentinel lymph nodes in women with cervical and uterine cancers (FILM): a randomised, phase 3, multicentre, non-inferiority trial. Lancet Oncol 2018;19:1394-1403].

Note: All recommendations are category 2A unless otherwise indicated.

References

Version 2.2026, 11/10/25 © 2025 National Comprehensive Cancer Network® (NCCN®), All rights reserved. NCCN Guidelines® and this illustration may not be reproduced in any form without the express written permission of NCCN.

PLEASE NOTE that use of this NCCN Content is governed by the End-User License Agreement, and you MAY NOT distribute this Content or use it with any artificial intelligence model or tool.
Printed by Galya Basol Kochav on 12/29/2025 12:47:39 PM. Copyright © 2025 National Comprehensive Cancer Network, Inc. All Rights Reserved.

PRINCIPLES OF EVALUATION AND SURGICAL STAGING WHEN SLN MAPPING IS USED

The key to a successful SLN mapping is adherence to the SLN algorithm, which requires the performance of a side-specific lymphadenectomy in cases of failed mapping and removal of any suspicious or grossly enlarged nodes regardless of mapping (Figure 3).

Figure 3: Surgical/SLN Mapping Algorithm for Early-Stage Cervical Cancer[e]

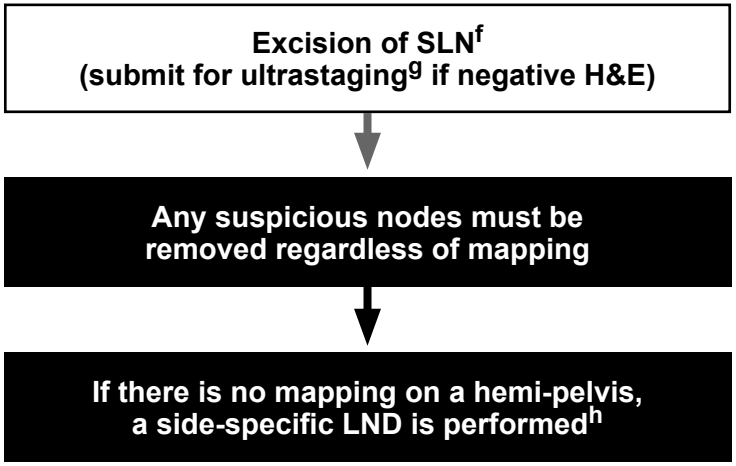

[e] Adapted with permission from Cormier B, Diaz JP, Shih K, et al. Establishing a sentinel lymph node mapping algorithm for the treatment of early cervical cancer. Gynecol Oncol 2011;122:275-280.
[f] Intracervical injection with dye, 99mTc, or both.
[g] There is no standard protocol for ultrastaging. Ultrastaging typically includes serial sectioning of the gross lymph node with review of H&E with or without cytokeratin IHC staining. See Principles of Pathology (CERV-A).
[h] Including interiliac/subaortic nodes.

Note: All recommendations are category 2A unless otherwise indicated.

Version 2.2026, 11/10/25 © 2025 National Comprehensive Cancer Network® (NCCN®), All rights reserved. NCCN Guidelines® and this illustration may not be reproduced in any form without the express written permission of NCCN.

PLEASE NOTE that use of this NCCN Content is governed by the End-User License Agreement, and you MAY NOT distribute this Content or use it with any artificial intelligence model or tool.
Printed by Galya Basol Kochav on 12/29/2025 12:47:39 PM. Copyright © 2025 National Comprehensive Cancer Network, Inc. All Rights Reserved.

PRINCIPLES OF EVALUATION AND SURGICAL STAGING

TABLE 1: Resection of Cervical Cancer as Primary Therapy[6]

Comparison of Hysterectomy Types			
	Simple Hysterectomy (Type A)[i]	Modified Radical Hysterectomy (Type B)[i]	Radical Hysterectomy (Type C1)[i]
Indication	Stage IA1–IB1 meeting conservative surgery criteria	Select IA1 with LVSI–IB1	Local disease without obvious metastasis, including: Select stage IB1–IIA1
Intent	Curative	Curative for small lesions	Curative for larger lesions
Uterus	Removed	Removed	Removed
Ovaries	Optional removal	Optional removal	Optional removal
Cervix	Completely removed	Completely removed	Completely removed
Vaginal margin	Minimal	1–2 cm margin	Upper 1/4 to 1/3 of vagina
Ureteral dissection	Not mobilized	Ureters unroofed and dissected from cervix	Ureters unroofed and dissected from cervix and from lateral parametria
Paracervix/Parametrial resection	None	Resection at the level of ureter bed (horizontal resection 1–2 cm)	Divided at medial aspect of internal iliac vessels. The deep margin is the deep uterine vein
Recto-uterine (Uterosacral ligaments)	Divided at cervical border	1–2 cm dorsal from cervix (preserves hypogastric nerve plexus)	Type C1 is nerve preserving, divided at least 2 cm dorsal from cervix
Bladder	Mobilized caudal to cervix	Mobilized to upper vagina	Mobilized to middle vagina
Rectum	Not mobilized	Mobilized below cervix	Mobilized below middle vagina
Surgical approach	Vaginal or laparotomy or minimally invasive	Laparotomy	Laparotomy

[i] The Querleu and Morrow surgical classification system describes the degree of resection and nerve preservation for radical hysterectomy in 3D planes and updates the previously used Piver-Rutledge-Smith classifications (Querleu D, Morrow CP. Classification of radical hysterectomy. Lancet Oncol 2008;9:297-303).

Note: All recommendations are category 2A unless otherwise indicated.

References

Version 2.2026, 11/10/25 © 2025 National Comprehensive Cancer Network® (NCCN®), All rights reserved. NCCN Guidelines® and this illustration may not be reproduced in any form without the express written permission of NCCN.

PLEASE NOTE that use of this NCCN Content is governed by the End-User License Agreement, and you MAY NOT distribute this Content or use it with any artificial intelligence model or tool.
Printed by Galya Basol Kochav on 12/29/2025 12:47:39 PM. Copyright © 2025 National Comprehensive Cancer Network, Inc. All Rights Reserved.

PRINCIPLES OF EVALUATION AND SURGICAL STAGING

TABLE 1: Resection of Cervical Cancer as Primary Therapy[6]

	Comparison of Fertility-Sparing Procedure Types		
	Conization	Simple Trachelectomy	Radical Trachelectomy[j]
Indication	IA1–IB1 meeting conservative surgery criteria	Stage IA1–IB1 meeting conservative surgery criteria	Stage IB1 not meeting conservative surgery criteria Select IB2
Intent	Curative and fertility preserving	Curative and fertility preserving	Curative and fertility preserving
Uterus	Spared	Spared	Spared
Ovaries	Spared	Spared	Spared
Cervix	Reduced, but spared	Majority removed (approximately 5 mm of the cranial aspect of the cervix typically left for cerclage)	Majority removed (approximately 5 mm of the cranial aspect of the cervix typically left for cerclage)
Vaginal margin	None	Minimal	1–2 cm margin
Ureteral dissection	None	Not mobilized	Ureters unroofed and dissected from cervix
Paracervix/Parametrial resection	None	Resected at cervical border	Resection at the level of ureter bed (horizontal resection 1–2 cm)
Recto-uterine (Uterosacral ligaments)	None	Divided at cervical border	1–2 cm dorsal from cervix (preserves hypogastric nerve plexus)
Bladder	None	Mobilized to peritoneal reflection	Mobilized to upper vagina
Rectum	None	Mobilized to peritoneal reflection	Mobilized below cervix
Surgical approach	Vaginal	Vaginal or laparotomy or minimally invasive[k]	Vaginal or laparotomy or minimally invasive (category 2B for MIS)[k]

[j] Fertility-sparing radical trachelectomy is most validated for lesions ≤2 cm in diameter. Small cell neuroendocrine histology and gastric type adenocarcinoma are not considered suitable tumors for this procedure.
[k] There is a lack of data on oncologic outcomes for minimally invasive surgical approaches to trachelectomy.

Note: All recommendations are category 2A unless otherwise indicated.

References

Version 2.2026, 11/10/25 © 2025 National Comprehensive Cancer Network® (NCCN®), All rights reserved. NCCN Guidelines® and this illustration may not be reproduced in any form without the express written permission of NCCN.

PLEASE NOTE that use of this NCCN Content is governed by the End-User License Agreement, and you MAY NOT distribute this Content or use it with any artificial intelligence model or tool.
Printed by Galya Basol Kochav on 12/29/2025 12:47:39 PM. Copyright © 2025 National Comprehensive Cancer Network, Inc. All Rights Reserved.

PRINCIPLES OF EVALUATION AND SURGICAL STAGING

TABLE 2: Resection of Locally Recurrent Cervical Cancer with No Distant Metastasis[6]

	Comparison of Infralevator Exenteration Types			Comparison of Supralevator Exenteration Types	
	Anterior	Posterior	Total	Posterior	Total
Indication	Central pelvic recurrence Primary therapy for select FIGO stage IVA when primary radiation not feasible				
Intent	Curative				
Uterus, tubes, ovaries	Removed if still present	Removed if still present	Removed if still present	Removed if still present	Removed if still present
Vagina	Removed	Removed	Removed	Removed	Removed
Bladder and urethra	Removed	Preserved	Removed	Preserved	Removed
Rectum	Preserved	Removed	Removed	Removed	Removed
Anal sphincter	Preserved	Removed	Removed	Preserved, colonic anastomosis possible	Preserved, colonic anastomosis possible
Reconstruction options Urinary system	Ileal conduit or Continent diversion	N/A	Double barrel wet colostomy,[20] ileal conduit, or continent diversion	N/A	Double barrel wet colostomy,[20] ileal conduit, or continent diversion
Reconstruction options GI system	N/A	End colostomy	Double barrel wet colostomy[20] or end colostomy	End colostomy or anastomosis with temporary ileostomy	Double barrel wet colostomy,[20] end colostomy, or anastomosis with temporary ileostomy
Neovaginal reconstruction options	Myocutaneous flap (rectus, gracilis, etc.), or split-thickness skin graft with omental J-flap				

Note: All recommendations are category 2A unless otherwise indicated.

References

Version 2.2026, 11/10/25 © 2025 National Comprehensive Cancer Network® (NCCN®), All rights reserved. NCCN Guidelines® and this illustration may not be reproduced in any form without the express written permission of NCCN.

PLEASE NOTE that use of this NCCN Content is governed by the End-User License Agreement, and you MAY NOT distribute this Content or use it with any artificial intelligence model or tool.
Printed by Galya Basol Kochav on 12/29/2025 12:47:39 PM. Copyright © 2025 National Comprehensive Cancer Network, Inc. All Rights Reserved.

PRINCIPLES OF EVALUATION AND SURGICAL STAGING
REFERENCES

[1] Teoh D, Musa F, Salani R, et al. Diagnosis and management of adenocarcinoma in situ: A Society of Gynecologic Oncology evidence-based review and recommendations. Obstet Gynecol 2020;135:869-878.
[2] Schmeler KM, Pareja R, Lopez Blanco A, et al. ConCerv: a prospective trial of conservative surgery for low-risk early-stage cervical cancer. Int J Gynecol Cancer 2021;31:1317-1325.
[3] Plante M, Gregoire J, Renaud MC, Roy M. The vaginal radical trachelectomy: an update of a series of 125 cases and 106 pregnancies. Gynecol Oncol 2011;121:290-297.
[4] Einstein MH, Park KJ, Sonoda Y, et al. Radical vaginal versus abdominal trachelectomy for stage IB1 cervical cancer: a comparison of surgical and pathologic outcomes. Gynecol Oncol 2009;112:73-77.
[5] Querleu D, Morrow CP. Classification of radical hysterectomy. Lancet Oncol 2008;9:297-303.
[6] Cibula D, Abu-Rustum NR, Benedetti-Panici P, et al. New classification system of radical hysterectomy: Emphasis on a three-dimensional anatomic template for parametrial resection. Gynecol Oncol 2011;122:264-268.
[7] Piver MS, Rutledge F, Smith JP. Five classes of extended hysterectomy for women with cervical cancer. Obstet Gynecol 1974;44:265-272.
[8] Wethington SL, Sonoda Y, Park KJ, et al. Expanding the indications for radical trachelectomy: a report on 29 patients with stage IB1 tumors measuring 2 to 4 centimeters. Int J Gynecol Cancer 2013;23:1092-1098.
[9] Wethington SL, Cibula D, Duska LR, et al. An international series on abdominal radical trachelectomy: 101 patients and 28 pregnancies. Int J Gynecol Cancer 2012;22:1251-1257.
[10] Ramirez PT, Frumovitz M, Pareja R, et al. Minimally invasive versus abdominal radical hysterectomy for cervical cancer. N Engl J Med 2018;379:1895-1904.
[11] Melamed A, Margul DJ, Chen L, et al. Survival after minimally invasive radical hysterectomy for early-stage cervical cancer. N Engl J Med 2018;379:1905-1914.
[12] Plante M, Kwon JS, Ferguson S, et al. Simple versus radical hysterectomy in women with low-risk cervical cancer. N Engl J Med 2024;390:819-829.
[13] Lintner B, Saso S, Tarnai L, et al. Use of abdominal radical trachelectomy to treat cervical cancer greater than 2 cm in diameter. Int J Gynecol Cancer 2013;23:1065-1070.
[14] Bats AS, Mathevet P, Buenerd A, et al. The sentinel node technique detects unexpected drainage pathways and allows nodal ultrastaging in early cervical cancer: insights from the multicenter prospective SENTICOL study. Ann Surg Oncol 2013;20:413-422.
[15] Eiriksson LR, Covens A. Sentinel lymph node mapping in cervical cancer: the future? BJOG 2012;119:129-133.
[16] Cormier B, Diaz JP, Shih K, et al. Establishing a sentinel lymph node mapping algorithm for the treatment of early cervical cancer. Gynecol Oncol 2011;122:275-280.
[17] Altgassen C, Hertel H, Brandstädt A, et al. Multicenter validation study of the sentinel lymph node concept in cervical cancer: AGO Study Group. J Clin Oncol 2008;26:2943-2951.
[18] Frumovitz M, Plante M, Lee PS, et al. Near-infrared fluorescence for detection of sentinel lymph nodes in women with cervical and uterine cancers (FILM): a randomised, phase 3, multicentre, non-inferiority trial. Lancet Oncol 2018;19:1394-1403.
[19] Cibula D, Abu-Rustum NR, Dusek L, et al. Prognostic significance of low volume sentinel lymph node disease in early-stage cervical cancer. Gynecol Oncol 2012;124:496-501.
[20] Backes FJ, Tierney BJ, Eisenhauer EL, et al. Complications after double-barreled wet colostomy compared to separate urinary and fecal diversion during pelvic exenteration: time to change back? Gynecol Oncol 2013;128:60-64.

Note: All recommendations are category 2A unless otherwise indicated.

Version 2.2026, 11/10/25 © 2025 National Comprehensive Cancer Network® (NCCN®), All rights reserved. NCCN Guidelines® and this illustration may not be reproduced in any form without the express written permission of NCCN.

PLEASE NOTE that use of this NCCN Content is governed by the End-User License Agreement, and you MAY NOT distribute this Content or use it with any artificial intelligence model or tool.
Printed by Galya Basol Kochav on 12/29/2025 12:47:39 PM. Copyright © 2025 National Comprehensive Cancer Network, Inc. All Rights Reserved.

PRINCIPLES OF RADIATION THERAPY[1]

General Principles

- The use of CT-based treatment planning and conformal blocking is considered the standard of care for EBRT. MRI is the best imaging modality for determining soft tissue and parametrial involvement in patients with advanced tumors. In patients who are not surgically staged, FDG-PET/CT imaging is useful to help define the nodal volume of coverage, and may be useful postoperatively to confirm removal of abnormal nodes.
- RT is directed at sites of known or suspected tumor involvement. EBRT is directed to the pelvis with or without the para-aortic region.
- IMRT technique is preferred to minimize toxicities in definitive treatment of the pelvis with or without para-aortic treatment. Regular use of image-guided RT (IGRT) with orthogonal imaging and/or routine volumetric imaging (such as cone-beam CT [CBCT]) at the time of treatment delivery is essential to ensure appropriate coverage of targets and sparing of normal tissues.
- Brachytherapy is a critical component of definitive RT for all patients with primary cervical cancer. This is performed using an intracavitary and/or an interstitial approach.
- For the majority of patients who receive EBRT for cervical cancer, concurrent platinum-containing chemotherapy with or without immunotherapy is given during the time of EBRT (CERV-F 1 of 4).
- Optimal results are achieved when treatment is completed within 8 weeks.

General Treatment Information

- Target Volumes
  - Concepts regarding the gross tumor volume (GTV), clinical target volume (CTV), planning target volume (PTV), organs at risk (OARs), internal organ motion, and dose-volume histogram (DVH) have been defined for use in conformal radiotherapy, especially for intensity-modulated RT (IMRT).
  - Very careful attention to detail and reproducibility (including consideration of target and normal tissue definitions, patient and internal organ motion, soft tissue deformation, and rigorous dosimetric and physics quality assurance) is required for proper delivery of IMRT and related highly conformal technologies. Routine image guidance, such as CBCT, should be used for defining daily internal soft tissue positioning.
  - The volume of EBRT should cover the gross disease (if present), parametria, uterosacral ligaments, sufficient vaginal margin from the gross disease (at least 3 cm), presacral nodes, and other nodal volumes at risk. For patients with negative nodes on surgical or radiologic imaging, the radiation volume should include the entirety of the external iliac, internal iliac, obturator, and presacral nodal basins. For patients deemed at higher risk of lymph node involvement (eg, bulkier tumors; suspected or confirmed nodes confined to the low true pelvis), the radiation volume should be increased to cover the common iliacs as well. In patients with documented common iliac and/or para-aortic nodal involvement, extended-field pelvic and para-aortic radiotherapy is recommended, up to the level of the renal vessels (or even more cephalad as directed by involved nodal distribution).
  - For patients with lower one-third vaginal involvement, the bilateral groins should be covered as well. Inguinofemoral node borders for distal vaginal cases: superior border = acetabular roof, lateral border = inguinofemoral vessels to medial sartorius/rectus femoris, posterior = posterior border of vessels, medial = pectineus muscle or 2.5–3 cm from vessels, anterior = anterior border of sartorius, caudal = top of lesser trochanter of femur.

Continued
References

Note: All recommendations are category 2A unless otherwise indicated.

Version 2.2026, 11/10/25 © 2025 National Comprehensive Cancer Network® (NCCN®), All rights reserved. NCCN Guidelines® and this illustration may not be reproduced in any form without the express written permission of NCCN.

PLEASE NOTE that use of this NCCN Content is governed by the End-User License Agreement, and you MAY NOT distribute this Content or use it with any artificial intelligence model or tool.
Printed by Galya Basol Kochav on 12/29/2025 12:47:39 PM. Copyright © 2025 National Comprehensive Cancer Network, Inc. All Rights Reserved.

PRINCIPLES OF RADIATION THERAPY[1]

General Treatment Information—Continued

Treatment Information - External Beam

- EBRT is delivered using multiple conformal fields or intensity-modulated volumetric techniques, such as IMRT/volumetric modulated arc therapy (VMAT)/tomotherapy.
- IMRT is preferred to minimize the dose to the bowel and other critical structures in the post-hysterectomy setting[2] and in treating the para-aortic nodes when necessary. These techniques can also be useful when high doses are required to treat gross disease in regional lymph nodes. However, conformal external beam therapies (such as IMRT or stereotactic body RT [SBRT]) should not be used as routine alternatives to brachytherapy for treatment of central disease in patients with an intact cervix.
- IMRT technique can reduce acute and chronic gastrointestinal (GI) and hematologic toxicity.
- A parametrial boost of 5 to 10 Gy can be considered in select cases with bulky parametrial/pelvic sidewall disease after completion of initial whole pelvic radiation.
- IMRT can be planned to deliver a higher dose to gross disease in the lymph nodes, while simultaneously delivering a lower dose to control microscopic disease to the other targets, termed a simultaneous integrated boost (SIB). Using a combination of IMRT with SIB can deliver higher doses to grossly positive nodal disease in a shorter time frame, while sparing normal tissues. In general, an SIB target may be boosted up to approximately 2.10 to 2.3 Gy/fraction, depending on target and OAR volumes. At times, additional external boosts may be necessary. Target doses for nodes can range from 54 to 63 Gy, with strict attention to the contribution from brachytherapy, and respecting normal tissue doses while paying attention to adjacent normal tissue doses. Consider bladder full and empty CT scans to generate utero-cervical-vaginal internal organ motion (internal target volume [ITV]).
- SBRT is an approach that allows for delivery of very high doses of focused EBRT in 1–5 fractions and may be applied to isolated metastatic sites; consideration can be given for limited disease in the reirradiation setting.[3,4]

Dosing Prescription Regimen - External Beam

- Coverage of microscopic nodal disease requires an EBRT dose of approximately 40–45 Gy (in conventional fractionation of 1.8–2.0 Gy daily possibly with an SIB if IMRT is used), and highly conformal boosts of an additional 10–20 Gy may be considered for limited volumes of gross unresected adenopathy, with consideration of the dose given by brachytherapy. For the majority of patients who receive EBRT for cervical cancer, concurrent platinum-containing chemotherapy is given during the time of EBRT.

Continued
References

Note: All recommendations are category 2A unless otherwise indicated.

Version 2.2026, 11/10/25 © 2025 National Comprehensive Cancer Network® (NCCN®), All rights reserved. NCCN Guidelines® and this illustration may not be reproduced in any form without the express written permission of NCCN.

PLEASE NOTE that use of this NCCN Content is governed by the End-User License Agreement, and you MAY NOT distribute this Content or use it with any artificial intelligence model or tool.
Printed by Galya Basol Kochav on 12/29/2025 12:47:39 PM. Copyright © 2025 National Comprehensive Cancer Network, Inc. All Rights Reserved.

PRINCIPLES OF RADIATION THERAPY[1]

General Treatment Information—Continued

Definitive RT for an Intact Cervix[a]

- In patients with an intact cervix (ie, those who do not have surgery), the primary tumor and regional lymphatics at risk are typically treated with definitive EBRT to a dose of approximately 45 Gy (40–50 Gy). The volume of the EBRT would depend on the nodal status as determined surgically or radiographically (as previously described). The primary cervical tumor is then boosted, using brachytherapy, with an additional 28 to 40 Gy using either image guidance (preferred) or to point A (in low-dose-rate [LDR] equivalent dose), total dose (EBRT + brachytherapy) to high-risk CTV (HR-CTV) D90 (preferred) of ≥85 Gy (EQD2), or point A. For very small tumors (medically inoperable IA1 or IA2) EQD2 D90 doses of 75–80 Gy may be considered. Grossly involved unresected nodes may be evaluated for boosting with an additional 10–15 Gy of highly conformal (and reduced-volume) EBRT. When using image guidance for EBRT, care must be taken to exclude or severely limit the volume of normal tissue included in the high-dose region(s) (see Discussion). Consider bladder full and empty CT scans to generate utero-cervical-vaginal internal organ motion (ITV).

Posthysterectomy Adjuvant Radiation Therapy[a]

- Following primary hysterectomy, the presence of one or more pathologic risk factors may warrant the use of adjuvant radiotherapy. At a minimum, the following should be covered: upper 3–4 cm of the vaginal cuff, the parametria, and immediately adjacent nodal basins (such as the external and internal iliac, obturator, and presacral nodes). For documented nodal metastasis, the superior border of the radiation field should be appropriately increased (as previously described). A dose of 45–50 Gy in standard fractionation with IMRT is generally recommended.[5] Grossly involved unresected nodes may be evaluated for boosting with an additional 10–20 Gy of highly conformal (and reduced-volume) EBRT. With higher doses, especially of EBRT, care must be taken to exclude or severely limit the volume of normal tissue included in the high-dose region(s) (see Discussion). Consider bladder full and empty CT scans to generate vaginal internal organ motion (ITV).
- Consider vaginal cuff brachytherapy boost for positive or close vaginal margins after radical hysterectomy, or after total/simple hysterectomy if completion upper vaginectomy not performed.
- Recommended dose regimens include 5–6 Gy x 2–3 fractions to either 0.5 cm depth or vaginal surface. Treatment active length is typically the apical 3–4 cm.

Intraoperative Radiation Therapy

- IORT is a specialized technique that delivers a single, highly focused dose of radiation to an at-risk tumor bed or isolated unresectable residual disease during an open surgical procedure.[6] It is particularly useful in patients with recurrent disease within a previously radiated volume. During IORT, overlying normal tissue (such as bowel or other viscera) can be manually displaced from the region at risk. IORT is typically delivered with electrons, brachytherapy, or miniaturized x-ray sources using preformed applicators of variable sizes matched to the surgically defined region at risk, which further constrains the area and depth of radiation exposure to avoid surrounding normal structures.

Reirradiation

- Techniques for reirradiation may include IORT, intracavitary or interstitial brachytherapy, SBRT, IMRT, or proton therapy. Such cases are highly customized and depend on the target, proximity to critical organs, previous RT dose, extent of overlap, and time intervals since prior RT. The appropriate dose for each case needs to be individualized.

[a] Normal Tissue Cumulative Dose Constraints (CERV-D 6 of 9).

Note: All recommendations are category 2A unless otherwise indicated.

Continued
References

Version 2.2026, 11/10/25 © 2025 National Comprehensive Cancer Network® (NCCN®), All rights reserved. NCCN Guidelines® and this illustration may not be reproduced in any form without the express written permission of NCCN.

PLEASE NOTE that use of this NCCN Content is governed by the End-User License Agreement, and you MAY NOT distribute this Content or use it with any artificial intelligence model or tool.
Printed by Galya Basol Kochav on 12/29/2025 12:47:39 PM. Copyright © 2025 National Comprehensive Cancer Network, Inc. All Rights Reserved.

PRINCIPLES OF RADIATION THERAPY[1]

General Treatment Information—Continued
Treatment Information - Brachytherapy[a]

- **Brachytherapy is a critical component of definitive RT for patients with primary cervical cancer. This is usually performed using an intracavitary approach, with an intrauterine tandem and vaginal colpostats. Depending on the patient and tumor anatomy, the vaginal component of brachytherapy in patients with an intact cervix may be delivered using ovoids, ring, or cylinder brachytherapy (combined with the intrauterine tandem). For more advanced disease, or without sufficient regression, interstitial needles may allow increased dose to the target, while minimizing dose to the normal tissues. MRI immediately preceding or during brachytherapy may be helpful in delineating residual tumor geometry. When combined with EBRT, brachytherapy is often initiated towards the latter part of treatment, when sufficient primary tumor regression has been noted to permit satisfactory brachytherapy apparatus geometry. In highly selected, very early disease (ie, stage IA2), brachytherapy alone (without EBRT) may be an option.**
- **In rare cases, patients whose anatomy or tumor geometry renders intracavitary brachytherapy infeasible may be best treated using an interstitial approach; however, such interstitial brachytherapy should only be performed by individuals and at institutions with appropriate experience and expertise, and early referral for timely use of their expertise is critical.**
- **In selected patients who receive post-hysterectomy (especially those with positive or close vaginal mucosal surgical margins), vaginal cylinder brachytherapy may be used as a boost to EBRT (regimens described in CERV-D 3 of 9). The prescription is typically to the vaginal surface or at 5 mm below the surface. Typical fractionation schemes include 5.5 Gy x 2 fractions dosed at 5 mm or 6 Gy x 3 fractions dosed at the vaginal surface to upper 3–4 cm of the vagina.**
- **SBRT is not considered an appropriate routine alternative to brachytherapy.**
- **Consider the use of intraprocedural imaging when placing brachytherapy applicators for intact cervical cancer.**

[a] Normal Tissue Cumulative Dose Constraints (CERV-D 6 of 9).

Note: All recommendations are category 2A unless otherwise indicated.

Continued
References

Version 2.2026, 11/10/25 © 2025 National Comprehensive Cancer Network® (NCCN®), All rights reserved. NCCN Guidelines® and this illustration may not be reproduced in any form without the express written permission of NCCN.

PLEASE NOTE that use of this NCCN Content is governed by the End-User License Agreement, and you MAY NOT distribute this Content or use it with any artificial intelligence model or tool.
Printed by Galya Basol Kochav on 12/29/2025 12:47:39 PM. Copyright © 2025 National Comprehensive Cancer Network, Inc. All Rights Reserved.

PRINCIPLES OF RADIATION THERAPY[1]

Dosing Prescription Regimen - Brachytherapy[a]

- **Point A, representing a paracervical reference point, has been the most widely used dosing parameter to date. However, limitations of the point A dosing system include the fact that it does not take into account the 3D shape of tumors, nor individual tumor to normal tissue structure correlations. Traditionally point A doses were based on widely validated dose fractionation for brachytherapy with LDR. The dose at point A assumes an LDR delivery of 40–70 cGy/h. The traditional LDR point A prescription dose was 70–80 Gy. Typical point A prescription doses are 5.5 Gy x 5 fractions for early disease and 6 Gy x 5 fractions for large tumors or those demonstrating a poor response. Another reasonable choice that has been well-studied in European trials for intracavity dosing to the HR-CTV is 28 Gy in 4 fractions.**
- **Interstitial brachytherapy is an advanced technique where multiple needles/catheters are inserted in the gross disease/target. Interstitial brachytherapy may be preferred to maximize dose to the target and minimize dose to the OARs for cases where intracavitary brachytherapy is not possible, or anatomy favors interstitial. 3D treatment planning allows for volumetric delineation of targets and OARs on CT and/or MRI with DVHs. Dose and fractionation depend on prior RT dose, target volume, and OAR doses.**
- **There is evidence that image-guided brachytherapy (IGBT) improves outcomes and decreases toxicity.[7] MRI gives the best soft tissue imaging for residual disease and while it is best to have an MRI with the instruments in place, an MRI prior to brachytherapy can help guide therapy. In the absence of MRI, CT can be used but is inferior for determination of residual disease and contouring is less accurate. The goals of care would include an equivalent dose at 2 Gy (EQD2) to the HR-CTV with a D90 of 80–85 Gy; however, with large disease or poor response dose goals should be HR-CTV D90 ≥87 Gy. Normal tissues should be limited according to published guidelines with 2-cc rectal dose ≤65 to 75 Gy, sigmoid 2-cc dose ≤70 to 75 Gy, and 2-cc bladder dose ≤80 to 90 Gy. If those parameters cannot be achieved, supplemental dosing with interstitial needles should be considered.[8-11]**
- **For brachytherapy in combination with EBRT, the external dose is delivered at 1.8–2.0 Gy per daily fraction. Clinicians using high-dose-rate (HDR) brachytherapy use dosing based on the linear-quadratic model equation to convert nominal HDR dose to a biologically equivalent LDR dose (https://www.americanbrachytherapy.org/guidelines). The HDR fractionation schedule of 5 fractions delivering 6 Gy nominal dose results in a nominal HDR dose of 30 Gy in 5 fractions, which is generally accepted to be the equivalent to 40 Gy to point A (tumor surrogate dose) using LDR brachytherapy to point A or HR-CTV.**

[a] Normal Tissue Cumulative Dose Constraints (CERV-D 6 of 9).

Note: All recommendations are category 2A unless otherwise indicated.

Continued
References

Version 2.2026, 11/10/25 © 2025 National Comprehensive Cancer Network® (NCCN®), All rights reserved. NCCN Guidelines® and this illustration may not be reproduced in any form without the express written permission of NCCN.

PLEASE NOTE that use of this NCCN Content is governed by the End-User License Agreement, and you MAY NOT distribute this Content or use it with any artificial intelligence model or tool.
Printed by Galya Basol Kochav on 12/29/2025 12:47:39 PM. Copyright © 2025 National Comprehensive Cancer Network, Inc. All Rights Reserved.

PRINCIPLES OF RADIATION THERAPY

NORMAL TISSUE CUMULATIVE DOSE CONSTRAINT GUIDELINES FOR CERVICAL CANCER[12-16]

Organs at Risk	Dose Recommendation	
Intact Cervix	*Soft Constraint*	*Hard Constraint*
Bowel	Up to 30% receives 40 Gy	No more than 70% receives 40 Gy
	V45 ≤200 cc	V45 <250 cc
	For nodal boost: V55 <5 cc	For nodal boost: V55 <15 cc
Bladder	V45 <50%	Dmax <57.5 Gy
Rectum	V45 <50% V30 <60%	Dmax <57.5 Gy
Femoral Heads	V30 <15%	Dmax <55 Gy
Bone Marrow (optional)	V10 <80% V20 <66%	V10 <90% V20 <75%
Spinal Cord	Dmax 45 Gy	—
Kidney	Dmean <10 Gy	Dmean <15 Gy
Duodenum	V55 <5 cc	V55 <15 cc

Note: All recommendations are category 2A unless otherwise indicated.

Continued
References

Version 2.2026, 11/10/25 © 2025 National Comprehensive Cancer Network® (NCCN®), All rights reserved. NCCN Guidelines® and this illustration may not be reproduced in any form without the express written permission of NCCN.

PLEASE NOTE that use of this NCCN Content is governed by the End-User License Agreement, and you MAY NOT distribute this Content or use it with any artificial intelligence model or tool.
Printed by Galya Basol Kochav on 12/29/2025 12:47:39 PM. Copyright © 2025 National Comprehensive Cancer Network, Inc. All Rights Reserved.

PRINCIPLES OF RADIATION THERAPY

NORMAL TISSUE DOSE CONSTRAINT GUIDELINES FOR CERVICAL CANCER[12-16]

Organs at Risk	Dose Recommendation	
Post-op Cervix	*Soft Constraint*	*Hard Constraint*
Bowel	Up to 30% receives 40 Gy	No more than 70% receives 40 Gy
Bladder	Up to 35% receives 45 Gy	No more than 70% receives 45 Gy
Rectum	Up to 80% receives 40 Gy	< 100% receives 40 Gy
Femoral Heads	Up to 15% receives ≥30 Gy	Up to 20% receives ≥30 Gy
Bone Marrow (optional)	Up to 90% receives 10 Gy	90% does not receive greater than 25 Gy
Bone Marrow (optional)	Up to 37% receives 40 Gy	No more than 60% receives 40 Gy
Spinal Cord	Dmax 45 Gy	—
Kidney	Dmean <10 Gy	Dmean <15 Gy
Duodenum	V55 <5 cc	V55 <15 cc

NORMAL TISSUE DOSE CONSTRAINTS GUIDELINES (WITH INGUINAL TREATMENT)

Organs at Risk	Dose Recommendation	
	Soft Constraint	*Hard Constraint*
Anorectum	Dmax <65 Gy	—
Femoral Heads	Dmax <55 Gy	—
Bladder	Dmax <65 Gy	—

Clinicians must balance the risks of normal tissue toxicity with tumor control but suggested dose constraints are provided. Studies indicate that 20%–30% of cases may not meet every constraint.

Continued
References

Note: All recommendations are category 2A unless otherwise indicated.

Version 2.2026, 11/10/25 © 2025 National Comprehensive Cancer Network® (NCCN®), All rights reserved. NCCN Guidelines® and this illustration may not be reproduced in any form without the express written permission of NCCN.

PLEASE NOTE that use of this NCCN Content is governed by the End-User License Agreement, and you MAY NOT distribute this Content or use it with any artificial intelligence model or tool.
Printed by Galya Basol Kochav on 12/29/2025 12:47:39 PM. Copyright © 2025 National Comprehensive Cancer Network, Inc. All Rights Reserved.

PRINCIPLES OF RADIATION THERAPY

NORMAL TISSUE DOSE CONSTRAINT GUIDELINES FOR CERVICAL CANCER[12-16]

Brachytherapy (Cumulative with EBRT)			
Organs at Risk	**Ideal Dose Constraint (Gy) ($EQD2_3$)**	**Maximum Dose Constraint (Gy) ($EQD2_3$)**	**ICRU Point (Gy) ($EQD2_3$)**
Rectum	<65 D2 cc	<75 D2 cc	<65 point dose
Bladder	75–80 D2 cc	<90 D2 cc	<75 point dose
Vagina (recto-vaginal point)	<65 point dose	<75 point dose	—
Sigmoid	<70 D2 cc	<75 D2 cc	—
Bowel	<70 D2 cc	<75 D2 cc	—

Note: All recommendations are category 2A unless otherwise indicated.

References

Version 2.2026, 11/10/25 © 2025 National Comprehensive Cancer Network® (NCCN®), All rights reserved. NCCN Guidelines® and this illustration may not be reproduced in any form without the express written permission of NCCN.

PLEASE NOTE that use of this NCCN Content is governed by the End-User License Agreement, and you MAY NOT distribute this Content or use it with any artificial intelligence model or tool.
Printed by Galya Basol Kochav on 12/29/2025 12:47:39 PM. Copyright © 2025 National Comprehensive Cancer Network, Inc. All Rights Reserved.

PRINCIPLES OF RADIATION THERAPY
REFERENCES

[1] Chino J, Annunziata CM, Beriwal S, et al. Radiation therapy for cervical cancer: Executive summary of an American Society for Radiation Oncology Clinical Practice Guideline. Pract Radiat Oncol 2020;10:220-234.
[2] Klopp, AH, Yeung AR, Deshmukh S, et al. A phase III randomized trial comparing patient-reported toxicity and quality of life (QOL) during pelvic intensity modulated radiation therapy as compared to conventional radiation therapy. Int J Radiat Oncol Biol Phys 2016;96:S3.
[3] Choi CW, Cho CK, Yoo SY, et al. Image-guided stereotactic body radiation therapy in patients with isolated para-aortic lymph node metastases from uterine cervical and corpus cancer. Int J Radiat Oncol Biol Phys 2009;74:147-153.
[4] Higginson DS, Morris DE, Jones EL, et al. Stereotactic body radiotherapy (SBRT): Technological innovation and application in gynecologic oncology. Gynecol Oncol 2011;120:404-412.
[5] Klopp AH, Yeung AR, Deshmukh SW, et al. Patient-reported toxicity during pelvic intensity-modulated radiation therapy: NRG Oncology-RTOG 1203. J Clin Oncol 2018;36:2538-2544.
[6] del Carmen MG, McIntyre JF, Goodman A. The role of radiation therapy (IORT) in the treatment of locally advanced gynecologic malignancies. Oncologist 2000;5:18-25.
[7] Pötter R, Tanderup K, Schmid MP, et al; EMBRACE Collaborative Group. MRI-guided adaptive brachytherapy in locally advanced cervical cancer (EMBRACE-I): a multicentre prospective cohort study. Lancet Oncol 2021;22:538-547.
[8] Haie-Meder C, Potter R, Van Limbergen E, et al. Recommendations from Gynaecological (GYN) GEC-ESTRO Working Group (I): concepts and terms in 3D image based 3D treatment planning in cervix cancer brachytherapy with emphasis on MRI assessment of GTV and CTV. Radiother Oncol 2005;74:235-245.
[9] Pötter R, Georg P, Dimopoulos JC, et al. Clinical outcome of protocol based image (MRI) guided adaptive brachytherapy combined with 3D conformal radiotherapy with or without chemotherapy in patients with locally advanced cervical cancer. Radiother Oncol 2011;100:116-123.
[10] Pötter R, Haie-Meder C, Van Limbergen E, et al. Recommendations from gynaecological (GYN) GEC ESTRO working group (II): concepts and terms in 3D image-based treatment planning in cervix cancer brachytherapy-3D dose volume parameters and aspects of 3D image-based anatomy, radiation physics, radiobiology. Radiother Oncol 2006;78:67-77.
[11] Lakomy DS, Wu J, Chapman BV, et al. Use of specific duodenal dose constraints during treatment planning reduces toxicity after definitive paraaortic radiation therapy for cervical cancer. Pract Radiat Oncol 2022;12:e207-e215.
[12] Klopp AH, Yeung AR, Deshmukh S, et al. Patient-reported toxicity during pelvic intensity-modulated radiation therapy: NRG Oncology-RTOG 1203. J Clin Oncol 2018;36:2538-2544. Erratum in: J Clin Oncol 2019;37:761. Erratum in: J Clin Oncol 2020;38:1118.
[13] Mell LK, Sirák I, Wei L, et al; INTERTECC Study Group. Bone marrow-sparing intensity modulated radiation therapy with concurrent cisplatin for stage IB-IVA cervical cancer: An international multicenter phase II clinical trial (INTERTECC-2). Int J Radiat Oncol Biol Phys 2017;97:536-545.
[14] Pötter R, Tanderup K, Kirisits C, et al; EMBRACE Collaborative Group. The EMBRACE II study: The outcome and prospect of two decades of evolution within the GEC-ESTRO GYN working group and the EMBRACE studies. Clin Transl Radiat Oncol 2018;9:48-60.
[15] Verma J, Sulman EP, Jhingran A, et al. Dosimetric predictors of duodenal toxicity after intensity modulated radiation therapy for treatment of the para-aortic nodes in gynecologic cancer. Int J Radiat Oncol Biol Phys 2014;88:357-362.
[16] Radiation Therapy, Gemcitabine Hydrochloride, and Cisplatin in Treating Patients With Locally Advanced Squamous Cell Cancer of the Vulva. ClinicalTrials.gov identifier: NCT01595061. ClinicalTrials.gov website. Available at: https://classic.clinicaltrials.gov/ct2/show/NCT01595061. Accessed September 12, 2023.

Note: All recommendations are category 2A unless otherwise indicated.

Version 2.2026, 11/10/25 © 2025 National Comprehensive Cancer Network® (NCCN®), All rights reserved. NCCN Guidelines® and this illustration may not be reproduced in any form without the express written permission of NCCN.

PLEASE NOTE that use of this NCCN Content is governed by the End-User License Agreement, and you MAY NOT distribute this Content or use it with any artificial intelligence model or tool.
Printed by Galya Basol Kochav on 12/29/2025 12:47:39 PM. Copyright © 2025 National Comprehensive Cancer Network, Inc. All Rights Reserved.

GOG/SEDLIS CRITERIA FOR EXTERNAL PELVIC RADIATION AFTER RADICAL HYSTERECTOMY IN NODE-NEGATIVE, MARGIN-NEGATIVE, PARAMETRIA-NEGATIVE CASES[a-c,1,2]

LVSI	Stromal Invasion	Tumor Size (cm) (determined by clinical palpation)
+	Deep 1/3	Any
+	Middle 1/3	≥2
+	Superficial 1/3	≥5
-	Middle or deep 1/3	≥4

LVSI: Lymphovascular space invasion

Footnotes

[a] Modified with permission from Sedlis A, Bundy BN, Rotman MZ, et al. A randomized trial of pelvic radiation therapy versus no further therapy in selected patients with stage IB carcinoma of the cervix after radical hysterectomy and pelvic lymphadenectomy: a gynecologic oncology study group. Gynecol Oncol 1999;73:177-183.
[b] Risk factors may not be limited to the GOG/Sedlis criteria.
[c] GOG/Sedlis criteria were developed primarily for SCC. Histology-specific nomograms for squamous and adenocarcinoma lesions may provide a more contemporary tool to model the risk of recurrence and base adjuvant recommendations. Depth of invasion is an important risk factor of recurrence for squamous lesions. Tumor size is an important risk factor for cervical adenocarcinoma, and this risk becomes more pronounced with the presence of LVSI.[3]

References

[1] Delgado G, Bundy B, Zaino R, et al. Prospective surgical-pathological study of disease-free interval in patients with stage IB squamous cell carcinoma of the cervix: a Gynecologic Oncology Group study. Gynecol Oncol 1990;38:352-357.
[2] Rotman M, Sedlis A, Piedmont MR, et al. A phase III randomized trial of postoperative pelvic irradiation in stage IB cervical carcinoma with poor prognostic features: follow-up of a gynecologic oncology group study. Int J Radiat Oncol Biol Phys 2006;65:169-176.
[3] Levinson K, Beavis AL, Purdy C, et al. Beyond sedlis-a novel histology-specific nomogram for predicting cervical cancer recurrence risk: an NRG/GOG ancillary analysis. Gynecol Oncol 2021;162:532-538.

Note: All recommendations are category 2A unless otherwise indicated.

Version 2.2026, 11/10/25 © 2025 National Comprehensive Cancer Network® (NCCN®), All rights reserved. NCCN Guidelines® and this illustration may not be reproduced in any form without the express written permission of NCCN.

PLEASE NOTE that use of this NCCN Content is governed by the End-User License Agreement, and you MAY NOT distribute this Content or use it with any artificial intelligence model or tool.
Printed by Galya Basol Kochav on 12/29/2025 12:47:39 PM. Copyright © 2025 National Comprehensive Cancer Network, Inc. All Rights Reserved.

SYSTEMIC THERAPY FOR CERVICAL CANCER[a,b,c]

Squamous Cell Carcinoma, Adenocarcinoma, or Adenosquamous Carcinoma		
Chemoradiation[d]	**Recurrent or Metastatic Disease**	
	First-Line Therapy[d,i]	**Second-Line or Subsequent Therapy[i,m]**
Preferred • Cisplatin + Pembrolizumab[e,f,k,1] ▸ Category 1: FIGO 2014 stage IIIA, IIIB, and IVA ▸ Category 2B: select FIGO 2018 stage III–IVA • Carboplatin + Pembrolizumab[e,f,k,1] if cisplatin intolerant ▸ Category 1: FIGO 2014 stage IIIA, IIIB, and IVA ▸ Category 2B: select FIGO 2018 stage III–IVA • Cisplatin • Carboplatin if cisplatin intolerant **Other Recommended** • If single-agent Cisplatin and Carboplatin are unavailable ▸ Capecitabine[g]/Mitomycin[2] ▸ Gemcitabine[3] ▸ Paclitaxel[4,5] • Induction chemotherapy (followed by chemoradiation) ▸ Carboplatin/Paclitaxel[h,6]	**Preferred** • PD-L1–positive tumors ▸ Cisplatin/Paclitaxel + Pembrolizumab ± Bevacizumab (category 1)[f,j,k,7] ▸ Carboplatin/Paclitaxel + Pembrolizumab ± Bevacizumab (category 1)[f,j,k,7] • Cisplatin/Paclitaxel + Bevacizumab[f,8] (category 1) • Carboplatin/Paclitaxel + Bevacizumab[f] • Cisplatin/Paclitaxel + Atezolizumab + Bevacizumab (category 1)[f,l,9] • Carboplatin/Paclitaxel + Atezolizumab + Bevacizumab (category 1)[f,l,9] **Other Recommended** • Cisplatin/Paclitaxel (category 1)[10,11] • Carboplatin/Paclitaxel[12,13] (category 1 for patients who have received prior Cisplatin therapy) • Paclitaxel/Topotecan + Bevacizumab[f,8,14] (category 1) • Paclitaxel/Topotecan[14] • Cisplatin/Topotecan[14] • Cisplatin[10] • Carboplatin[15,16]	**Preferred** • TMB-H tumors:[n] Pembrolizumab[k] • PD-L1–positive: Pembrolizumab[j,k] • MSI-H/dMMR tumors: Pembrolizumab[k,17] • Tisotumab vedotin-tftv (category 1)[18,19] **Other Recommended** • Bevacizumab • Paclitaxel[16,20] • Albumin-bound Paclitaxel • Docetaxel • Fluorouracil[g] • Gemcitabine • Pemetrexed • Topotecan • Vinorelbine • Irinotecan • Cemiplimab[21] • Ipilimumab + Nivolumab[22,23,24] **Useful in Certain Circumstances** • PD-L1–positive tumors ▸ Nivolumab[j,o,22] ▸ Pembrolizumab + Tisotumab vedotin-tftv[j,k,p,25] • HER2-positive tumors (IHC 3+ or 2+) ▸ Fam-trastuzumab deruxtecan-nxki[26] • HER2-mutant ▸ Neratinib[27] • *RET* gene fusion-positive tumors ▸ Selpercatinib • *NTRK* gene fusion-positive tumors ▸ Larotrectinib ▸ Entrectinib ▸ Repotrectinib[q,28]	

Note: All recommendations are category 2A unless otherwise indicated.

Footnotes on CERV-F 1A of 4

Version 2.2026, 11/10/25 © 2025 National Comprehensive Cancer Network® (NCCN®), All rights reserved. NCCN Guidelines® and this illustration may not be reproduced in any form without the express written permission of NCCN.

PLEASE NOTE that use of this NCCN Content is governed by the End-User License Agreement, and you MAY NOT distribute this Content or use it with any artificial intelligence model or tool.
Printed by Galya Basol Kochav on 12/29/2025 12:47:39 PM. Copyright © 2025 National Comprehensive Cancer Network, Inc. All Rights Reserved.

SYSTEMIC THERAPY FOR CERVICAL CANCER[a]
FOONOTES

[a] An FDA-approved biosimilar is an appropriate substitute for any recommended systemic biologic therapy in the NCCN Guidelines.
[b] Cisplatin, carboplatin, docetaxel, and paclitaxel may cause drug reactions (see NCCN Guidelines for Ovarian Cancer–Management of Drug Reactions [OV-D]).
[c] For immunotherapy regimens, also refer to NCCN Guidelines for the Management of Immune Checkpoint Inhibitor-Related Toxicities.
[d] Cost and toxicity, especially when using extended-field RT, should be carefully considered when selecting an appropriate regimen for treatment.
[e] Concurrent platinum-containing chemotherapy with EBRT utilizes cisplatin as a single agent (or carboplatin if cisplatin intolerant). Pembrolizumab may be added with CRT as follows: cisplatin (or carboplatin)/RT and pembrolizumab (FIGO 2014 stage IIIA, IIIB, and IVA: category 1); cisplatin (or carboplatin)/RT and pembrolizumab (select FIGO 2018 stage III–IVA: category 2B). Category 2B is for FIGO 2018 stage IIIC purely on nodal metastasis without concomitant tumor characteristics defined in 2014 FIGO stage IIIA–IIIB. If the FIGO 2018 staging of stage III overlaps with FIGO 2014 IIIA/IIIB staging, category 1 can be applied to cisplatin (or carboplatin) + pembrolizumab. Prescribing information: https://www.accessdata.fda.gov/drugsatfda_docs/label/2024/125514s147lbl.pdf
[f] Checkpoint inhibitors and/or monoclonal antibodies included in this regimen may be continued as maintenance therapy. Refer to the original study protocol for maintenance therapy dosing schedules.
[g] For information regarding dihydropyrimidine dehydrogenase (DPYD) testing, see the NCCN Guidelines for Colon Cancer.
[h] Induction chemotherapy (carboplatin/paclitaxel) followed by single-agent cisplatin (or carboplatin) and radiation given according to the INTERLACE protocol could be considered (McCormack M, et al. Lancet 2024;404:1525-1535).
[i] If not used previously, these agents can be used as second-line or subsequent therapy as clinically appropriate.
[j] Recommended in patients whose tumors express PD-L1 (combined positive score [CPS] ≥1).
[k] Pembrolizumab and berahyaluronidase alfa-pmph subcutaneous injection may be substituted for IV pembrolizumab. Pembrolizumab and berahyaluronidase alfa-pmph has different dosing and administration instructions compared to IV pembrolizumab.
[l] Atezolizumab and hyaluronidase-tqjs injection for subcutaneous injection may be substituted for IV atezolizumab. Atezolizumab and hyaluronidase-tqjs has different dosing and administration instructions compared to atezolizumab for intravenous infusion.
[m] Additional references for second-line therapy are provided in the Discussion.
[n] For the treatment of patients with unresectable or metastatic tumor mutational burden-high (TMB-H) (≥10 mutations/megabase [mut/Mb]) tumors that have progressed following prior treatment and who have no satisfactory alternative treatment options.
[o] Nivolumab and hyaluronidase-nvhy subcutaneous injection may be substituted for IV nivolumab. Nivolumab and hyaluronidase-nvhy has different dosing and administration instructions compared to IV nivolumab.
[p] For patients who are PD-L1–positive and have not received prior immuno-oncology (IO) therapy.
[q] *NTRK*-positive tumors that are naïve to prior *NTRK*-targeted therapy or have progressed on prior *NTRK* therapy.

Note: All recommendations are category 2A unless otherwise indicated.

Version 2.2026, 11/10/25 © 2025 National Comprehensive Cancer Network® (NCCN®), All rights reserved. NCCN Guidelines® and this illustration may not be reproduced in any form without the express written permission of NCCN.

PLEASE NOTE that use of this NCCN Content is governed by the End-User License Agreement, and you MAY NOT distribute this Content or use it with any artificial intelligence model or tool.
Printed by Galya Basol Kochav on 12/29/2025 12:47:39 PM. Copyright © 2025 National Comprehensive Cancer Network, Inc. All Rights Reserved.

SYSTEMIC THERAPY FOR CERVICAL CANCER[a,b,c]

Small Cell NECC[r]		
Chemoradiation[s]	**Recurrent or Metastatic Disease**	
	First-Line Therapy[i]	**Second-Line or Subsequent Therapy[i]**
Preferred • Cisplatin/Etoposide[29,30] **Other Recommended** • Carboplatin/Etoposide if patient is Cisplatin intolerant	**Preferred** • Cisplatin/Etoposide • Carboplatin/Etoposide **Other Recommended** • Cisplatin/Etoposide + Atezolizumab (or Durvalumab)[f,l,31,32] • Carboplatin/Etoposide + Atezolizumab (or Durvalumab)[f,l,31,32] • Paclitaxel/Topotecan + Bevacizumab[f,33] • Cisplatin/Paclitaxel • Carboplatin/Paclitaxel (for patients who have received prior Cisplatin therapy)	**Other Recommended** • Bevacizumab • Albumin-bound Paclitaxel • Docetaxel • Topotecan • Paclitaxel/Topotecan • Cisplatin/Topotecan • Cisplatin • Carboplatin • Paclitaxel • Irinotecan • Ipilimumab + Nivolumab[34]

[a] An FDA-approved biosimilar is an appropriate substitute for any recommended systemic biologic therapy in the NCCN Guidelines.
[b] Cisplatin, carboplatin, docetaxel, and paclitaxel may cause drug reactions (see NCCN Guidelines for Ovarian Cancer–Management of Drug Reactions [OV-D]).
[c] For immunotherapy regimens, also refer to NCCN Guidelines for the Management of Immune Checkpoint Inhibitor-Related Toxicities.
[f] Checkpoint inhibitors and/or monoclonal antibodies included in this regimen may be continued as maintenance therapy. Refer to the original study protocol for maintenance therapy dosing schedules.
[i] If not used previously, these agents can be used as second-line or subsequent therapy as clinically appropriate.
[l] Atezolizumab and hyaluronidase-tqjs injection for subcutaneous injection may be substituted for IV atezolizumab. Atezolizumab and hyaluronidase-tqjs has different dosing and administration instructions compared to atezolizumab for intravenous infusion.
[r] For dosing and schedules, see Principles of Systemic Therapy (SCL-E) in the NCCN Guidelines for Small Cell Lung Cancer.
[s] To be followed by systemic therapy.

Note: All recommendations are category 2A unless otherwise indicated.

References

Version 2.2026, 11/10/25 © 2025 National Comprehensive Cancer Network® (NCCN®), All rights reserved. NCCN Guidelines® and this illustration may not be reproduced in any form without the express written permission of NCCN.

PLEASE NOTE that use of this NCCN Content is governed by the End-User License Agreement, and you MAY NOT distribute this Content or use it with any artificial intelligence model or tool.
Printed by Galya Basol Kochav on 12/29/2025 12:47:39 PM. Copyright © 2025 National Comprehensive Cancer Network, Inc. All Rights Reserved.

SYSTEMIC THERAPY FOR CERVICAL CANCER REFERENCES

[1] Lorusso D, Xiang Y, Hasegawa K, et al. Pembrolizumab or placebo with chemoradiotherapy followed by pembrolizumab or placebo for newly diagnosed, high-risk, locally advanced cervical cancer (ENGOT-cx11/GOG-3047/KEYNOTE-A18): a randomised, double-blind, phase 3 clinical trial. Lancet 2024;403:1341-1350.
[2] Lorvidhaya V, Chitapanaarux I, Sangruchi S, et al. Concurrent mitomycin C, 5-fluorouracil, and radiotherapy in the treatment of locally advanced carcinoma of the cervix: a randomized trial. Int J Radiat Oncol Biol Phys 2003;55:1226-1232.
[3] Pattaranutaporn P, Thirapakawong C, Chansilpa Y, et al. Phase II study of concurrent gemcitabine and radiotherapy in locally advanced stage IIIB cervical carcinoma. Gynecol Oncol 2001;81:404-407.
[4] Candelaria M, Garcia-Aria A, Cetina L, et al. Radiosensitizers in cervical cancer. Cisplatin and beyond. Radiat Oncol 2006;1:15.
[5] Cerrotta A. Gardan G, Raspagliesi F, et al. Concurrent radiotherapy and weekly paclitaxel for locally advanced or recurrent squamous cell carcinoma of the uterine cervix. A pilot study with intensification of dose. Eur J Gynaecol Oncol 2002;23:115-119.
[6] McCormack M, Eminowicz G, Gallardo D, et al. INTERLACE investigators. Induction chemotherapy followed by standard chemoradiotherapy versus standard chemoradiotherapy alone in patients with locally advanced cervical cancer (GCIG INTERLACE): an international, multicentre, randomised phase 3 trial. Lancet 2024;19;404:1525-1535.
[7] Colombo N, Dubot C, Lorusso D, et al. Pembrolizumab for persistent, recurrent, or metastatic cervical cancer. N Engl J Med 2021;385:1856-1867.
[8] Tewari KS, Sill MW, Long HJ 3rd, et al. Improved survival with bevacizumab in advanced cervical cancer. N Engl J Med 2014;370:734-743.
[9] Oaknin A, Gladieff L, Martínez-García J, et al. ENGOT-Cx10–GEICO 68-C–JGOG1084–GOG-3030 Investigators. Atezolizumab plus bevacizumab and chemotherapy for metastatic, persistent, or recurrent cervical cancer (BEATcc): a randomised, open-label, phase 3 trial. Lancet 2024;403:31-43.
[10] Monk BJ, Sill MW, McMeekin DS, et al. Phase III trial of four cisplatin-containing doublet combinations in stage IVB, recurrent, or persistent cervical carcinoma: a Gynecologic Oncology Group study. J Clin Oncol 2009;27:4649-4655.
[11] Moore DH, Blessing JA, McQuellon RP, et al. Phase III study of cisplatin with or without paclitaxel in stage IVB, recurrent, or persistent squamous cell carcinoma of the cervix: a gynecologic oncology group study. J Clin Oncol 2004;22:3113-3119.
[12] Moore KN, Herzog TJ, Lewin S, et al. A comparison of cisplatin/paclitaxel and carboplatin/paclitaxel in stage IVB, recurrent or persistent cervical cancer. Gynecol Oncol 2007;105:299-303.
[13] Kitagawa R, Katsumata N, Shibata T, et al. Paclitaxel plus carboplatin versus paclitaxel plus cisplatin in metastatic or recurrent cervical cancer: the open-label randomized phase III trial JCOG0505. J Clin Oncol 2015;33:2129-2135.
[14] Long HJ 3rd, Bundy BN, Grendys EC Jr, et al. Randomized phase III trial of cisplatin with or without topotecan in carcinoma of the uterine cervix: a Gynecologic Oncology Group Study. J Clin Oncol 2005;23:4626-4633.
[15] Weiss GR, Green S, Hannigan EV, et al. A phase II trial of carboplatin for recurrent or metastatic squamous carcinoma of the uterine cervix: a Southwest Oncology Group study. Gynecol Oncol 1990;39:332-336.
[16] Tinker AV, Bhagat K, Swenerton KD, Hoskins PJ. Carboplatin and paclitaxel for advanced and recurrent cervical carcinoma: the British Columbia Cancer Agency experience. Gynecol Oncol 2005;98:54-58.
[17] Marabelle A, Le DT, Ascierto PA, et al. Efficacy of pembrolizumab in patients with noncolorectal high microsatellite instability/mismatch repair-deficient cancer: results from the phase 2 KEYNOTE-158 study. J Clin Oncol 2020;38:1-10.
[18] Coleman RL, Lorusso D, Gennigens C, et al. Efficacy and safety of tisotumab vedotin in previously treated recurrent or metastatic cervical cancer (innovaTV 204/GOG-3023/ENGOT-cx6): a multicentre, open-label, single-arm, phase 2 study. Lancet Oncol 2021;22:609-619.
[19] Vergote I, Gonzalez-Martin A, Fujiwara K, et al. Tisotumab vedotin as second- or third-line therapy for recurrent cervical cancer. N Engl J Med 2024; 391:44-55.
[20] McGuire WP, Blessing JA, Moore D, et al. Paclitaxel has moderate activity in squamous cervix cancer. A Gynecologic Oncology Group study. J Clin Oncol 1996;14:792-795.
[21] Tewari KS, Monk BJ, Vergote I, et al. Survival with cemiplimab in recurrent cervical cancer. N Engl J Med 2022;386:544-555.
[22] Naumann RW, Hollebecque A, Meyer T, et al. Safety and efficacy of nivolumab monotherapy in recurrent or metastatic cervical, vaginal, or vulvar carcinoma: Results from the phase I/II CheckMate 358 trial. J Clin Oncol 2019;37:2825-2834.
[23] Oaknin A, Moore K, Meyer T, et al. Nivolumab with or without ipilimumab in patients with recurrent or metastatic cervical cancer (CheckMate 358): a phase 1–2, open-label, multicohort trial. Lancet Oncol 2024;25:588-602.
[24] Schenker M, Burotto M, Richardet M, et al. Randomized, open-label, phase 2 study of nivolumab plus ipilimumab or nivolumab monotherapy in patients with advanced or metastatic solid tumors of high tumor mutational burden. J Immunother Cancer 2024;12:e008872.

Note: All recommendations are category 2A unless otherwise indicated.

Continued

Version 2.2026, 11/10/25 © 2025 National Comprehensive Cancer Network® (NCCN®), All rights reserved. NCCN Guidelines® and this illustration may not be reproduced in any form without the express written permission of NCCN.

PLEASE NOTE that use of this NCCN Content is governed by the End-User License Agreement, and you MAY NOT distribute this Content or use it with any artificial intelligence model or tool.
Printed by Galya Basol Kochav on 12/29/2025 12:47:39 PM. Copyright © 2025 National Comprehensive Cancer Network, Inc. All Rights Reserved.

SYSTEMIC THERAPY FOR CERVICAL CANCER
REFERENCES (CONTINUED)

[25] Vergote I, Van Nieuwenhuysen E, O'Cearbhaill RE, et al. Tisotumab vedotin in combination with carboplatin, pembrolizumab, or bevacizumab in recurrent or metastatic cervical cancer: Results from the innovaTV 205/GOG-3024/ENGOT-cx8 study. J Clin Oncol 2023;41:5536-5549.
[26] Meric-Bernstam F, Makker V, Oaknin A, et al. Efficacy and safety of trastuzumab deruxtecan in patients with HER2-expressing solid tumors: DESTINYPanTumor02 Phase II trial. J Clin Oncol 2024;42:47-58.
[27] Friedman CF, D'Souza A, Bello Roufai D, et al. Targeting HER2-mutant metastatic cervical cancer with neratinib: Final results from the phase 2 SUMMIT basket trial. Gynecol Oncol 2024;181:162-169.
[28] Solomon B, Drilon A, Lin JJ, et al. Repotrectinib in patients with NTRK fusion-positive advanced solid tumors, including non-small cell lung cancer: update from the phase 1/2 TRIDENT-1 trial. Poster presented at the European Society for Medical Oncology Congress, Madrid, Spain, October 20-24, 2023.
[29] Zivanovic O, Leitao Jr MM, Park KJ, et al. Small cell neuroendocrine carcinoma of the cervix: Analysis of outcome, recurrence pattern and the impact of platinum-based combination chemotherapy. Gynecol Oncol 2009;112:590-593.
[30] Gordhandas S, Schlappe BA, Zhou Q, et al. Small cell neuroendocrine carcinoma of the cervix: Analysis of prognostic factors and patterns of metastasis. Gynecol Oncol Rep 2022;43:101058.
[31] Horn L, Mansfield AS, Szczęsna A, et al. First-line atezolizumab plus chemotherapy in extensive-stage small-cell lung cancer. N Engl J Med 2018;379:2220-2229.
[32] Paz-Ares L, Dvorkin M, Chen Y, et al. Durvalumab plus platinum–etoposide versus platinum–etoposide in first-line treatment of extensive-stage small-cell lung cancer (CASPIAN): a randomised, controlled, open-label, phase 3 trial. Lancet 2019;394:1929-1939.
[33] Frumovitz M, Munsell MF, Burzawa JK, et al. Combination therapy with topotecan, paclitaxel, and bevacizumab improves progression-free survival in recurrent small cell neuroendocrine carcinoma of the cervix. Gynecol Oncol 2017;144:46-50.
[34] Towner M, Novak K, Chae YK, Matei D. Ipilimumab and nivolumab for recurrent neuroendocrine cervical carcinoma. Gynecol Oncol Rep 2022;42:101039.

Note: All recommendations are category 2A unless otherwise indicated.

Version 2.2026, 11/10/25 © 2025 National Comprehensive Cancer Network® (NCCN®), All rights reserved. NCCN Guidelines® and this illustration may not be reproduced in any form without the express written permission of NCCN.

PLEASE NOTE that use of this NCCN Content is governed by the End-User License Agreement, and you MAY NOT distribute this Content or use it with any artificial intelligence model or tool.
Printed by Galya Basol Kochav on 12/29/2025 12:47:39 PM. Copyright © 2025 National Comprehensive Cancer Network, Inc. All Rights Reserved.

PRINCIPLES OF GYNECOLOGIC SURVIVORSHIP

Physical Effects

- Gynecologic cancer treatment typically involves surgery, chemotherapy, hormone therapy, RT, and/or immunotherapy. These treatments cause acute, short-term, and long-term toxicities.
- Surgical approaches may be extensive and pose risks such as adhesion formation, which may cause pain and may contribute to small bowel obstruction, urinary or GI complications (eg, incontinence, diarrhea), pelvic floor dysfunction (manifested by a variety of urinary, bowel, and/or sexual effects), and lymphedema.
- Chemotherapy agents vary, though commonly used regimens may pose a significant risk of neurotoxicity, cardiac toxicity, development of hematologic cancers, and cognitive dysfunction.
- Long-term estrogen deprivation may cause symptoms such as hot flashes, vaginal dryness, and bone loss.
- RT may cause long-term complications (eg, fibrosis, vulvovaginal atrophy) and may predispose patients to secondary cancers of the subcutaneous tissue, and/or underlying organs that are proximal to the radiation field.
- Prior pelvic RT may contribute to bone loss and increase the risk of pelvic fractures. Consider bone density testing and prophylactic use of bisphosphonates, particularly in patients with osteoporosis.

Immunotherapy use is emerging, and to date, long-term effects of these treatments are unknown.

Psychosocial Effects

- Psychosocial effects after cancer may be psychological (eg, depression, anxiety, fear of recurrence, altered body image), financial (eg, return to work, insurance concerns), and/or interpersonal (eg, relationships, sexuality, intimacy) in nature.

Clinical Approach

- All gynecologic cancer survivors should receive regular general medical care that focuses on managing chronic disease, monitoring cardiovascular risk factors, providing recommended vaccinations, and encouraging adoption of a healthy lifestyle.
- In order to assess the late and long-term effects of gynecologic cancers, clinicians should comprehensively document the patient's history, conduct a thorough physical examination, and provide any necessary imaging and/or laboratory testing. All patients, whether sexually active or not, should be asked about genitourinary symptoms, including vulvovaginal dryness. Referral to appropriate specialty providers (eg, physical therapy, pelvic floor therapy, sexual therapy, psychotherapy) is recommended. As most treatments for gynecologic cancers will cause sexual dysfunction, early menopause, and infertility, special attention to the resultant medical and psychosocial implications is needed.
- Post-radiation use of vaginal dilators and moisturizers is recommended.
- For treatment-related menopause, hormone therapy should be considered.
- Communication and coordination with all clinicians involved in the care of survivors, including primary care clinicians, is critical. Providing cancer survivors with a summary of their treatment and recommendations for follow-up is recommended.

Additional Guidance

- NCCN Guidelines for Distress Management
- NCCN Guidelines for Smoking Cessation
- NCCN Guidelines for Survivorship

Note: All recommendations are category 2A unless otherwise indicated.

Version 2.2026, 11/10/25 © 2025 National Comprehensive Cancer Network® (NCCN®), All rights reserved. NCCN Guidelines® and this illustration may not be reproduced in any form without the express written permission of NCCN.

PLEASE NOTE that use of this NCCN Content is governed by the End-User License Agreement, and you MAY NOT distribute this Content or use it with any artificial intelligence model or tool.
Printed by Galya Basol Kochav on 12/29/2025 12:47:39 PM. Copyright © 2025 National Comprehensive Cancer Network, Inc. All Rights Reserved.

Table 1: International Federation of Gynecology and Obstetrics (FIGO) Staging of Cancer of the Cervix Uteri (2018)

Stage			Description
I			The carcinoma is strictly confined to the cervix (extension to the corpus should be disregarded).
	IA		Invasive carcinoma that can be diagnosed only by microscopy with maximum depth of invasion ≤5 mm[a]
		IA1	Measured stromal invasion ≤3 mm in depth
		IA2	Measured stromal invasion >3 mm and ≤5 mm in depth
	IB		Invasive carcinoma with measured deepest invasion >5 mm (greater than stage IA); lesion limited to the cervix uteri with size measured by maximum tumor diameter[b]
		IB1	Invasive carcinoma >5 mm depth of stromal invasion and ≤2 cm in greatest dimension
		IB2	Invasive carcinoma >2 cm and ≤4 cm in greatest dimension
		IB3	Invasive carcinoma >4 cm in greatest dimension
II			The cervical carcinoma invades beyond the uterus, but has not extended onto the lower third of the vagina or to the pelvic wall
	IIA		Involvement limited to the upper two-thirds of the vagina without parametrial invasion
		IIA1	IIA1 Invasive carcinoma ≤4 cm in greatest dimension
		IIA2	Invasive carcinoma >4 cm in greatest dimension
	IIB		With parametrial invasion but not up to the pelvic wall
III			The carcinoma involves the lower third of the vagina and/or extends to the pelvic wall and/or causes hydronephrosis or non-functioning kidney and/or involves pelvic and/or paraaortic lymph nodes
	IIIA		Carcinoma involves lower third of the vagina, with no extension to the pelvic wall
	IIIB		Extension to the pelvic wall and/or hydronephrosis or non-functioning kidney (unless known to be due to another cause)
	IIIC		Involvement of pelvic and/or paraaortic lymph nodes (including micrometastases),[c] irrespective of tumor size and extent (with r and p notations).
		IIIC1	Pelvic lymph node metastasis only
		IIIC2	Paraaortic lymph node metastasis
IV			The carcinoma has extended beyond the true pelvis or has involved (biopsy proven) the mucosa of the bladder or rectum. A bullous edema, as such, does not permit a case to be allotted to stage IV
	IVA		Spread of the growth to adjacent organs
	IVB		Spread to distant organs

[a] Imaging and pathology can be used, when available, to supplement clinical findings with respect to tumor size and extent, in all stages. Pathological findings supersede imaging and clinical findings.
[b] The involvement of vascular/lymphatic spaces should not change the staging. The lateral extent of the lesion is no longer considered.
[c] Isolated tumor cells do not change the stage but their presence should be recorded.
[d] Adding notation of r (imaging) and p (pathology) to indicate the findings that are used to allocate the case to Stage IIIC. Example: If imaging indicates pelvic lymph node metastasis, the stage allocation would be Stage IIIC1r, and if confirmed by pathologic findings, it would be Stage IIIC1p. The type of imaging modality or pathology technique used should always be documented.

Reprinted from: Bhatla N, Berek JS, Fredes MC, et al. Revised FIGO Staging for carcinoma of the cervix uteri. Int J Gynecol Obstet 2019;145:129-135 and Corrigendum to "Revised FIGO Staging for carcinoma of the cervix uteri" [Int J Gynecol Obstet 2019;145:129-135] Int J Gynecol Obstet 2019;147:279-280. Copyright 2019, with permission from International Federation of Gynecology and Obstetrics.

Version 2.2026, 11/10/25 © 2025 National Comprehensive Cancer Network® (NCCN®), All rights reserved. NCCN Guidelines® and this illustration may not be reproduced in any form without the express written permission of NCCN.

PLEASE NOTE that use of this NCCN Content is governed by the End-User License Agreement, and you MAY NOT distribute this Content or use it with any artificial intelligence model or tool.
Printed by Galya Basol Kochav on 12/29/2025 12:47:39 PM. Copyright © 2025 National Comprehensive Cancer Network, Inc. All Rights Reserved.

ABBREVIATIONS

3D	three-dimensional
99mTc	radiocolloid technetium-99m
ACTH	adrenocorticotropic hormone
BUN	blood urea nitrogen
CBC	complete blood count
CBCT	cone-beam CT
CEA	carcinoembryonic antigen
CGP	comprehensive genomic profiling
CKC	cold knife conization
CLIA	Clinical Laboratory Improvement Amendments
CPS	combined positive score
ctDNA	circulating tumor DNA
CTV	clinical target volume
DES	diethylstilbestrol
DFS	disease-free survival
dMMR	mismatch repair deficient
DVH	dose-volume histogram
EBRT	external beam radiation therapy
ECC	endocervical curettage
EQD2	equivalent dose at 2 Gy
ER	estrogen receptor
EUA	examination under anesthesia
FDG	fluorodeoxyglucose
FIGO	International Federation of Gynecology and Obstetrics
FISH	fluorescence in situ hybridization
GTV	gross tumor volume
H&E	hematoxylin and eosin
H&P	history and physical
HDR	high dose rate
HIV	human immunodeficiency virus
HPV	human papillomavirus
HR-CTV	high-risk clinical target volume
HSIL	high-grade squamous intraepithelial lesion
ICG	indocyanine green
ICRU	International Commission on Radiation Units and Measurements
IECC	International Endocervical Adenocarcinoma Criteria and Classification
IGBT	image-guided brachytherapy
IGRT	image-guided radiation therapy
IHC	immunohistochemistry
IMA	inferior mesenteric artery
IMRT	intensity-modulated radiation therapy
INSM1	insulinoma-associated protein 1
IO	immuno-oncology
IORT	intraoperative radiation therapy
ISH	in situ hybridization
ISMC	invasive stratified mucin-producing carcinoma
ITV	internal target volume
LDR	low dose rate
LEEP	loop electrosurgical excision procedure
LFT	liver function test
LND	lymphadenectomy
LVSI	lymphovascular space invasion
MIS	minimally invasive surgery
MMR	mismatch repair
MSI	microsatellite instability
MSI-H	microsatellite instability-high
mut/Mb	mutations per megabase
NECC	neuroendocrine carcinoma of the cervix

Continued

Version 2.2026, 11/10/25 © 2025 National Comprehensive Cancer Network® (NCCN®), All rights reserved. NCCN Guidelines® and this illustration may not be reproduced in any form without the express written permission of NCCN.

PLEASE NOTE that use of this NCCN Content is governed by the End-User License Agreement, and you MAY NOT distribute this Content or use it with any artificial intelligence model or tool.
Printed by Galya Basol Kochav on 12/29/2025 12:47:39 PM. Copyright © 2025 National Comprehensive Cancer Network, Inc. All Rights Reserved.

ABBREVIATIONS

OAR	organ at risk
PCR	polymerase chain reaction
PD-L1	programmed death ligand 1
PTV	planning target volume
REI	reproductive endocrinology and infertility
SBRT	stereotactic body radiation therapy
SCC	squamous cell carcinoma
SIB	simultaneous integrated boost
SLN	sentinel lymph node
TH	total hysterectomy
TMB	tumor mutational burden
TMB-H	tumor mutational burden-high
TTF-1	thyroid transcription factor-1
VMAT	volumetric modulated arc therapy

Version 2.2026, 11/10/25 © 2025 National Comprehensive Cancer Network® (NCCN®), All rights reserved. NCCN Guidelines® and this illustration may not be reproduced in any form without the express written permission of NCCN.

PLEASE NOTE that use of this NCCN Content is governed by the End-User License Agreement, and you MAY NOT distribute this Content or use it with any artificial intelligence model or tool.
Printed by Galya Basol Kochav on 12/29/2025 12:47:39 PM. Copyright © 2025 National Comprehensive Cancer Network, Inc. All Rights Reserved.

NCCN Categories of Evidence and Consensus	
Category 1	Based upon high-level evidence (≥1 randomized phase 3 trials or high-quality, robust meta-analyses), there is uniform NCCN consensus (≥85% support of the Panel) that the intervention is appropriate.
Category 2A	Based upon lower-level evidence, there is uniform NCCN consensus (≥85% support of the Panel) that the intervention is appropriate.
Category 2B	Based upon lower-level evidence, there is NCCN consensus (≥50%, but <85% support of the Panel) that the intervention is appropriate.
Category 3	Based upon any level of evidence, there is major NCCN disagreement that the intervention is appropriate.

All recommendations are category 2A unless otherwise indicated.

NCCN Categories of Preference	
Preferred	Interventions that are based on superior efficacy, safety, and evidence; and, when appropriate, affordability.
Other recommended	Other interventions that may be somewhat less efficacious, more toxic, or based on less mature data; or significantly less affordable for similar outcomes.
Useful in certain circumstances	Other interventions that may be used for selected patient populations (defined with recommendation).

All recommendations are considered appropriate.

Version 2.2026, 11/10/25 © 2025 National Comprehensive Cancer Network® (NCCN®), All rights reserved. NCCN Guidelines® and this illustration may not be reproduced in any form without the express written permission of NCCN.

PLEASE NOTE that use of this NCCN Content is governed by the End-User License Agreement, and you MAY NOT distribute this Content or use it with any artificial intelligence model or tool.
Printed by Galya Basol Kochav on 12/29/2025 12:47:39 PM. Copyright © 2025 National Comprehensive Cancer Network, Inc. All Rights Reserved.

Discussion

This discussion corresponds to the NCCN Guidelines for Cervical Cancer (2.2026). Last updated on November 10, 2025

Table of Contents

Overview 2
Guidelines Update Methodology 3
Literature Search Criteria 3
Sensitive/Inclusive Language Usage 3
Diagnosis and Workup 3
Principles of Staging and Surgery 4
- Clinical Staging 4
- Surgical Staging 5
- Lymph Node Mapping and Dissection 7
- Minimally Invasive Surgical Approaches 9

Principles of Pathology 10
- Pathologic Assessment 10
- Prognostic and Predictive Biomarkers 13

Primary Treatment 18
- Early-Stage Disease 18
- Advanced Disease 23
- Metastatic Disease 24

Surveillance 24
Therapy for Relapse 25
- Locoregional Recurrence 25
- Therapy for Metastatic Disease 26

Incidental Cervical Cancer 26
Systemic Therapy Recommendations 27
- Chemoradiation for Locally Advanced Cervical Cancer 27
- Systemic Therapy for Recurrent or Metastatic Cervical Cancer 29

Principles of Radiation Therapy 35
- Radiation Treatment Planning 36
- Normal Tissue Considerations 39

Small Cell Neuroendocrine Carcinoma of the Cervix 40
- Overview 40
- Primary Workup 40
- Principles of Pathology 40
- Systemic Therapy 41

Cervical Cancer and Pregnancy 42
Drug Reactions 43
Gynecologic Survivorship 43
Best Supportive Care 44
Summary 44
References 45

Version 2.2026 © 2025 National Comprehensive Cancer Network® (NCCN®), All rights reserved. NCCN Guidelines®, and this illustration may not be reproduced in any form without the express written permission of NCCN.

PLEASE NOTE that use of this NCCN Content is governed by the End-User License Agreement, and you MAY NOT distribute this Content or use it with any artificial intelligence model or tool.
Printed by Galya Basol Kochav on 12/29/2025 12:47:39 PM. Copyright © 2025 National Comprehensive Cancer Network, Inc. All Rights Reserved.

Overview

An estimated 13,360 new cases of carcinoma of the uterine cervix (ie, cervical cancer) will be diagnosed in the United States in 2025, and 4320 people are estimated to die of the disease.[1,2] Although cervical cancer rates are decreasing in the United States following the introduction of screening, incidence remains high among Hispanic/Latino, Black, and Asian populations.[3-6] The incidence rates of cervical squamous cell carcinoma (SCC) are highest in Black and Hispanic individuals assigned female at birth (AFAB), while incidence rates of cervical adenocarcinoma are highest among Hispanic and white AFAB individuals.[7,8] Overall, cervical cancer is a major world health problem for AFAB individuals. Globally in 2022, there were an estimated 661,021 cervical cancer cases and 348,189 deaths associated with cervical cancer.[9,10] It is the fourth most common cancer in AFAB individuals worldwide with 85% of cases occurring in developing countries—where cervical cancer is a leading cause of cancer death in AFAB individuals.[1,10-12] It is the most diagnosed cancer in 23 countries and the leading cause of cancer death in 36 countries.[13]

SCC, adenocarcinoma (AC), adenosquamous carcinoma (ASC) are the three common histologies of cervical cancer. SCC accounts for approximately 80% and AC accounts for approximately 20% of all cervical cancers. In developed countries, the substantial decline in incidence and mortality of SCC of the cervix is presumed to be the result of effective screening and higher human papillomavirus (HPV)-vaccination coverage, although racial, ethnic, and geographic disparities exist.[3,4,11-14]

However, AC/ASC of the cervix have increased over the past 3 decades, probably because cervical cytologic screening methods are less effective for AC/ASC as the lesions are located deeper than the ectocervix.[15-19] The ASC subtype is rare and accounts for approximately 5% to 6% of all cervical carcinomas. Presently, there is no difference in treatment between SCC and AC/ASC cervical cancer subtypes although the clinical features and prognosis of disease varies considerably between these subtypes.

Persistent HPV infection is the most important factor in the development of cervical cancer.[20,21] The incidence of cervical cancer appears to be related to the prevalence of HPV in the population. In countries with a high incidence of cervical cancer, the prevalence of chronic HPV is approximately 10% to 20%, whereas the prevalence in low-incidence countries is 5% to 10%.[15] Screening methods using HPV testing may increase detection of adenocarcinoma. Immunization against HPV prevents infection with the types of HPV against which the vaccine is designed and, thus, is expected to prevent specific HPV cancer.[22-29] HPV vaccines may also decrease the incidence of both squamous cell carcinoma and adenocarcinoma.[17,30] Although a majority of studies report that most cervical cancers are caused by HPV, around 5% of the tumors are reported as HPV-independent tumors.[31,32] Other epidemiologic risk factors associated with cervical cancer are a history of smoking, parity, oral contraceptive use, early age of onset of coitus, larger number of sexual partners, history of sexually transmitted disease, certain autoimmune diseases, and chronic immunosuppression.[33-35] Smoking cessation should be advised in current smokers, and former smokers should continue to avoid smoking (see the NCCN Guidelines for Smoking Cessation, available at www.NCCN.org, and http://smokefree.gov/).

In 2020, the World Health Organization (WHO) updated the Female Genital Tumors classification of cervical cancer by subdividing the cervical cancer lesions into HPV-associated and HPV-independent tumors based on the new pathological findings.[36] Among these, the HPV-associated SCC is the most prevalent subtype, with very rare occurrences of the HPV-independent SCC. The HPV-independent AC has a less favorable prognosis as compared to the HPV-associated tumors. The NCCN Cervical Cancer Guidelines Panel acknowledges that while the prior

Version 2.2026 © 2025 National Comprehensive Cancer Network® (NCCN®), All rights reserved. NCCN Guidelines®, and this illustration may not be reproduced in any form without the express written permission of NCCN.

PLEASE NOTE that use of this NCCN Content is governed by the End-User License Agreement, and you MAY NOT distribute this Content or use it with any artificial intelligence model or tool.
Printed by Galya Basol Kochav on 12/29/2025 12:47:39 PM. Copyright © 2025 National Comprehensive Cancer Network, Inc. All Rights Reserved.

versions of the WHO classification discussed these tumors based on morphologic features, the integration of the immunohistochemical and molecular profiles has led to a better classification system that is now adapted in the 2020 WHO Classification of Female Genital Tumors for cervical cancer.[36] Regardless of cancer subtype and HPV infection status, primary treatment with curative intent for patients with cervical cancer typically consists of surgery, chemoradiation, or a combination of these treatments; options vary by cancer stage. By definition, the NCCN Guidelines cannot incorporate all possible clinical variations and are not intended to replace good clinical judgment or individualization of treatments. Many exceptions were discussed among the members of the Cervical Cancer Panel during the process of developing these guidelines.

Guidelines Update Methodology

The complete details of the Development and Update of the NCCN Guidelines are available at www.NCCN.org.

Literature Search Criteria

Prior to the update of this version of the NCCN Clinical Practice Guidelines in Oncology (NCCN Guidelines®) for Cervical Cancer, an electronic search of the PubMed database was performed to obtain key literature in cervical cancer published since the previous Guidelines update, using the following search terms: cervical cancer or cervical carcinoma or carcinoma of the cervix. The PubMed database was chosen as it remains the most widely used resource for medical literature and indexes only peer-reviewed biomedical literature.

The search results were narrowed by selecting studies in humans published in English. Results were confined to the following article types: Clinical Trial, Phase II; Clinical Trial, Phase III; Clinical Trial, Phase IV; Guideline; Randomized Controlled Trial; Meta-Analysis; Systematic Reviews; and Validation Studies.

The data from key PubMed articles as well as articles from additional sources deemed as relevant to these Guidelines as discussed by the Panel during the Guidelines update have been included in this version of the Discussion section. Recommendations for which high-level evidence is lacking are based on the Panel's review of lower-level evidence and expert opinion.

Sensitive/Inclusive Language Usage

NCCN Guidelines strive to use language that advances the goals of equity, inclusion, and representation. NCCN Guidelines endeavor to use language that is person-first; not stigmatizing; anti-racist, anti-classist, anti-misogynist, anti-ageist, anti-ableist, and anti-weight-biased; and inclusive of individuals of all sexual orientations and gender identities. NCCN Guidelines incorporate non-gendered language, instead focusing on organ-specific recommendations. This language is both more accurate and more inclusive and can help fully address the needs of individuals of all sexual orientations and gender identities. NCCN Guidelines will continue to use the terms men, women, female, and male when citing statistics, recommendations, or data from organizations or sources that do not use inclusive terms. Most studies do not report how sex and gender data are collected and use these terms interchangeably or inconsistently. If sources do not differentiate gender from sex assigned at birth or organs present, the information is presumed to predominantly represent cisgender individuals. NCCN encourages researchers to collect more specific data in future studies and organizations to use more inclusive and accurate language in their future analyses.

Diagnosis and Workup

These NCCN Guidelines discuss squamous cell carcinoma, adenosquamous carcinoma, and adenocarcinoma of the cervix. The primary workup for small cell neuroendocrine carcinoma is discussed in *Small Cell Neuroendocrine Carcinoma of the Cervix (NECC)* section.

Version 2.2026 © 2025 National Comprehensive Cancer Network® (NCCN®), All rights reserved. NCCN Guidelines®, and this illustration may not be reproduced in any form without the express written permission of NCCN.

PLEASE NOTE that use of this NCCN Content is governed by the End-User License Agreement, and you MAY NOT distribute this Content or use it with any artificial intelligence model or tool.
Printed by Galya Basol Kochav on 12/29/2025 12:47:39 PM. Copyright © 2025 National Comprehensive Cancer Network, Inc. All Rights Reserved.

Glassy-cell carcinomas, sarcomas, and other histologic types are not within the scope of these Guidelines.

The earliest stages of cervical carcinoma may be asymptomatic or associated with a watery vaginal discharge and postcoital bleeding or intermittent spotting. Often these early symptoms are not recognized by the patient. Because of the accessibility of the uterine cervix, cervical cytology, or Papanicolaou (Pap) tests and cervical biopsies can usually result in an accurate diagnosis. Cone biopsy (ie, conization) is recommended if the cervical biopsy is inadequate to define invasiveness or if accurate assessment of microinvasive disease is required. The shape and depth of the cone biopsy may be tailored to the size, type, and location of the neoplastic lesion. For example, if there is concern for invasive adenocarcinoma versus adenocarcinoma in situ in the cervical canal, the cone biopsy would be designed as a narrow, long cone extending to the internal os in order not to miss possible invasion in the endocervical canal. Length of the cold cone of at least 10 mm is preferred and can be increased to 18 to 20 mm in patients who have completed childbearing.[37] However, cervical cytologic screening methods are less useful for diagnosing adenocarcinoma, because adenocarcinoma in situ affects areas of the cervix that are harder to sample (ie, endocervical canal).[18,38]

Workup for these patients with suspicious symptoms includes history and physical examination, complete blood count (CBC, including platelets), and liver and renal function tests. Recommended radiologic imaging includes pelvic MRI, neck/chest/abdomen/pelvis/groin FDG-PET/CT, chest radiograph, CT, or combined PET/CT, and MRI as indicated (eg, to rule out disease high in the endocervix). For detailed imaging recommendations by stage and planned treatment approach, see *Principles of Imaging* in the NCCN Guidelines® for Cervical Cancer. Smoking cessation and counseling, as well as human immunodeficiency virus (HIV) testing (especially in younger patients), are recommended. Cystoscopy and proctoscopy are only recommended if bladder or rectal extension is suspected (ie, for ≥ stage IB3). Options for fertility sparing should be considered, or referral to reproductive endocrinology and infertility (REI) specialist.

Principles of Staging and Surgery

Clinical Staging

The Panel has updated the Guidelines for Cervical Cancer according to the revised 2018 International Federation of Gynecology and Obstetrics (FIGO) staging system.[39,40] The definitions for lesion size and microinvasion for stage I have been revised. For stage IA, the lateral extent of the lesion no longer affects staging. Stage IB is now divided into 3 subgroups as follows: IB1 includes invasive carcinomas >5 mm and ≤2 cm in greatest diameter; IB2 includes tumors >2 cm and ≤4 cm; and IB3 designates tumors >4 cm. Consideration of nodal metastasis has also been revised; radiology (r) or pathology (p) findings may be used to assess retroperitoneal nodal involvement and are indicated for stage IIIC. Nodal involvement is now designated as stage IIIC, which is subdivided into IIIC1 for pelvic nodes only, and IIIC2 for para-aortic node involvement. Importantly, lymphovascular space invasion (LVSI) does not alter the FIGO classification. FIGO did not include LVSI because pathologists do not always agree on whether LVSI is present in tissue samples. Some Panel members believe that patients with stage IA1 who have extensive LVSI should be treated using stage IB1 guidelines.[39] The staging and treatment recommendations by stage have been revised according to FIGO 2018 in the algorithm, and some of the data cited within this section utilized the previous 2009 FIGO staging system.[41,42] All staging guidelines are based on 2018 FIGO staging, unless otherwise noted.

Version 2.2026 © 2025 National Comprehensive Cancer Network® (NCCN®), All rights reserved. NCCN Guidelines®, and this illustration may not be reproduced in any form without the express written permission of NCCN.

PLEASE NOTE that use of this NCCN Content is governed by the End-User License Agreement, and you MAY NOT distribute this Content or use it with any artificial intelligence model or tool.
Printed by Galya Basol Kochav on 12/29/2025 12:47:39 PM. Copyright © 2025 National Comprehensive Cancer Network, Inc. All Rights Reserved.

Surgical Staging

Pathologic Assessment

Surgicopathologic factors may be used to guide the extent of surgical staging and treatment decisions. Findings from pathologic assessment of the surgical specimen should be carefully documented according to College of American Pathologists (CAP) protocol for cervical carcinoma. The CAP protocol for cervical carcinoma is a useful guide for the examination of resection specimens from patients with primary cervical cancer (https://documents.cap.org/protocols/Cervix_5.0.1.3.REL_CAPCP.pdf). This CAP protocol was revised in March 2022 and reflects recent updates in AJCC staging (ie, AJCC Cancer Staging Manual, 9th edition) and FIGO cancer report 2018.[43] Important elements of primary tumor evaluation include tumor site; primary tumor volume (in multiple dimensions); histologic type and grade; stromal invasion including pattern of invasion; surgical margin status; and the presence of LVSI. When evaluating patterns of stromal invasion in endocervical adenocarcinoma, the Silva system is utilized, which subdivides these tumors into three categories (see *Principles of Pathology* section).[44] When evaluating histologic type, according to the 2018 International Endocervical Adenocarcinoma Criteria and Classification (IECC),[45] morphologic features (luminal mitotic figures and apoptosis) can be used to distinguish between HPV-associated endocervical adenocarcinomas and HPV-independent adenocarcinomas. Tumors can be further subtyped based on morphologic features. When resected, the number of lymph nodes with isolated tumor cells, micrometastases, and macrometastases should be recorded. When sentinel lymph node (SLN) mapping is performed, SLNs should undergo ultra staging for detection of low-volume metastasis; non-sentinel nodes do not require ultra staging. Other important factors include tumor involvement of tissues/organs such as the parametrium, vaginal cuff, fallopian tubes, ovaries, peritoneum, omentum, and others.

Uterus-11 was a prospective international multicenter study aimed to evaluate the impact of pre-treatment surgical staging, including removal of bulky lymph nodes, on disease-free survival in patients with locally advanced cervical cancer. A total of 255 patients (surgical arm, n = 130; clinical arm, n = 125) with locally advanced cervical cancer were randomized 1:1 to surgical staging (experimental arm) or clinical staging (control arm) followed by primary platinum-based chemoradiation. After a median follow-up of 90 months (range, 1–123) in both arms, there was no difference in disease-free survival (DFS) between the groups (P = .084). The study did not show a difference in DFS between surgical and clinical staging in patients with locally advanced cervical cancer.[46]

Conservative/Fertility-Sparing Approaches

Fertility-sparing approaches may be considered in highly selected patients who have been thoroughly counseled regarding disease risk as well as prenatal and perinatal issues.[47] Consultation with REI experts are suggested.

Microinvasive disease (FIGO stage IA1 with no LVSI) is associated with an extremely low incidence of lymphatic metastasis,[48-51] and conservative treatment with conization is an option for individuals with no evidence of LVSI. The goal of conization is *en bloc* removal of the ectocervix and endocervical canal; the Panel recommends cold knife conization as the preferred approach to conization. However, loop electrosurgical excision procedure (LEEP) is acceptable if adequate margins, proper orientation, and a non-fragmented specimen without electrosurgical artifact can be obtained.[52-57] Endocervical curettage should be added as clinically indicated except in pregnancy.

Based on ConCerv trial, select patients with stage IA2 and IB1, especially for those with tumors ≤2 cm in diameter and who meet all the conservative surgery criteria with no evidence of LVSI, may be eligible for conservative surgery with SLN mapping or pelvic lymphadenectomy.[42,58,59]

Version 2.2026 © 2025 National Comprehensive Cancer Network® (NCCN®), All rights reserved. NCCN Guidelines®, and this illustration may not be reproduced in any form without the express written permission of NCCN.

The objective of the ConCerv Trial was to prospectively evaluate the feasibility of conservative surgery in women with early-stage, low-risk cervical cancer. The eligibility criteria included: (1) FIGO 2009 stage IA2–IB1 cervical carcinoma; (2) squamous cell (any grade) or adenocarcinoma (grade 1 or 2 only) histology; (3) tumor size ≤2 cm; (4) no LVSI; (5) depth of invasion ≤10 mm; (6) negative imaging for locoregional disease; and (7) negative conization margins.

One hundred evaluable patients were enrolled, and the surgery included conization followed by lymph node assessment in 44 individuals, conization followed by simple hysterectomy with lymph node assessment in 40 women, and inadvertent simple hysterectomy followed by lymphadenectomy in 16 individuals. Positive lymph nodes were noted in 5 patients. Residual disease in the post-conization hysterectomy specimen was noted in 1 out of 40 patients—that is, an immediate failure rate of 2.5%. The study concluded that select patients with early-stage, low-risk cervical carcinoma may be offered conservative surgery, and the Panel updated the selection options for patients with early-stage, low-risk, stage IA2 and IB1 cancer. Applying Concerv selection criteria to stage IA2–IB1 eliminates the need for parametrectomy and upper vaginectomy.

The GOG-0278 trial supports the use of cone biopsy and pelvic lymphadenectomy for early-stage cervical cancer.[60] This trial enrolled 224 patients (32% underwent cone biopsy and 68% underwent simple hysterectomy) to evaluate the efficacy and perioperative morbidity of non-radical surgery—either simple hysterectomy or cone biopsy plus pelvic lymphadenectomy—and to report pregnancy outcomes after cone biopsy. The trial population included 14% with stage IA1, 28% with stage IA2, and 58% with stage IB1 disease. Histologic subtypes were 65% squamous cell carcinoma, 32% adenocarcinoma, and 3% adenosquamous carcinoma. Among patients in the cone biopsy group, 31 expressed a desire for pregnancy during the study period, resulting in 16 pregnancies. Of these, 4 ended in spontaneous abortion, 3 resulted in preterm delivery, and 9 in full-term delivery. After a median follow-up of 37 months (range, 0.2–93 months), 3 patients in the cone biopsy group experienced recurrence (3-year recurrence-free survival, 94.8%) and subsequently underwent hysterectomy, compared with no recurrences in the simple hysterectomy group. Since GOG-0278 trial also included patients with stage IA1 disease with LVSI, cone biopsy with negative margins with SLN mapping or pelvic lymphadenectomy are also recommended for this group.

Radical vaginal trachelectomy (RVT) with SLN mapping or pelvic lymphadenectomy may be used for patients with stage IB1 disease and select patients with IB2 disease with lesions <2 cm diameter.[61-63] In a radical trachelectomy, the cervix, vaginal margins, and supporting ligaments are removed while leaving the main body and fundus of the uterus intact.[64] Abdominal radical trachelectomy (ART) provides a broader resection of the parametria[63,65] than the vaginal approach and is commonly used in stage IB1–IB2 lesions between 2 to 4 cm in diameter and this mimics type C1 radical hysterectomy.[65-67] Multiple case series have evaluated safety and outcomes with vaginal versus abdominal approaches to radical trachelectomy,[61,68-70] including systematic reviews on VRT[71] and ART.[72] A limited number of studies have specifically examined this approach in patients with tumors between 2 to 4 cm in diameter and reported safe oncologic outcomes; however, as expected, more patients in this subgroup will require adjuvant therapy, which may reduce fertility.[73-75] Laparoscopic pelvic lymphadenectomy accompanies the procedure and can be performed with SLN mapping (see *Lymph Node Mapping and Dissection* below). Para-aortic lymphadenectomy can be added for stage 1B1 and select patients with IB2 cervical cancer.[76]

Studies that examined pregnancy in patients who underwent radical trachelectomy have provided differing success rates. One case series of 125 patients with cervical cancer who underwent VRT reported 106

Version 2.2026 © 2025 National Comprehensive Cancer Network® (NCCN®), All rights reserved. NCCN Guidelines®, and this illustration may not be reproduced in any form without the express written permission of NCCN.

pregnancies among 58 females.[62] In a systematic review of 413 females who underwent ART, 113 of those attempted pregnancy and 67 (59%) successfully conceived.[69] However, miscarriage and pre-term labor rates were elevated among those who underwent radical trachelectomy.[62,77-79]

Due to their aggressive nature, tumors of small cell neuroendocrine histology are considered inappropriate for radical trachelectomy.[80] Trachelectomy is also inappropriate for treating gastric type cervical adenocarcinoma and adenoma malignum (minimal deviation adenocarcinoma) due to their diagnostic challenges and potentially aggressive nature.[81]

Non–Fertility-Sparing Approaches

The Querleu and Morrow surgical classification system[82,83] describes the degree of resection and nerve preservation for radical hysterectomy in three-dimensional planes and updates the previously used Piver-Rutledge classifications.[84] Approaches to hysterectomy include Type A (simple/extrafascial hysterectomy), Type B (modified radical hysterectomy), and Type C (radical hysterectomy).[82,85,86]

Radical hysterectomy (Type C) is the preferred treatment approach for patients with FIGO stage IB1, IB2, IB3, IIA1, and IIA2 cervical cancers. Radical hysterectomy is preferred over simple hysterectomy due to its wider paracervix margin of resection that also includes aspects of the cardinal and uterosacral ligaments, upper vagina, pelvic nodes, and at times, para-aortic nodes. In the United States, definitive chemoradiation is typically preferred over radical surgery for select patients with FIGO IB3 lesions and the vast majority of FIGO stage ≥IIA2 cervical cancers. Abroad, select FIGO stage IB3–IIB cases may be treated with radical hysterectomy or neoadjuvant chemotherapy followed by radical hysterectomy.

For recurrent or persistent cervical cancers that are confined to the central pelvis (ie, no distant metastasis), pelvic exenteration may be a potentially curative surgical option.[87,88] Discussion of the various approaches to pelvic exenteration are offered by Chi and colleagues,[85] and in the Gynecologic Oncology Group (GOG) Surgical Manual.[86]

Lymph Node Mapping and Dissection

Sentinel Lymph Node Mapping

Based on cumulative published data, SLN biopsy may be useful for decreasing the need for pelvic lymphadenectomy in patients with early-stage cervical cancer and to detect low-volume metastasis.[89,90]

Prospective studies generally support the feasibility of SLN detection in patients with early-stage cervical cancer and suggest that extensive pelvic lymphadenectomy may be safely avoided in a significant proportion of early-stage cases.[89-100]

Meta-analyses of pooled data from SLN mapping studies have generated SLN detection rates of 89% to 92% and sensitivity of 89% to 90%.[101,102] Factors determined to be important for detection included laparoscopy, dual blue dye/radiocolloid tracer approaches, and pathologic assessment using immunohistochemistry. However, based on a meta-analysis, indocyanine green (ICG) tracer appears to provide similar overall and bilateral detection rates to the standard dual blue dye/technetium-99 approach.[103] The randomized phase III FILM trial demonstrated that ICG tracer identified more SLNs (overall and bilateral) than blue dye.[104]

Study data also highlight limited sensitivity of this approach and potential to miss SLN micrometastases and isolated tumor cells using intraoperative assessment (ie, frozen section or imprint cytology).[92,96,98] The sensitivity of this approach appears to be better in patients with tumors ≤2 cm in diameter.[89,91,93,105] Ultra staging of detected SLNs has been shown to provide enhanced detection of micrometastases.[94,95]

Version 2.2026 © 2025 National Comprehensive Cancer Network® (NCCN®), All rights reserved. NCCN Guidelines®, and this illustration may not be reproduced in any form without the express written permission of NCCN.

PLEASE NOTE that use of this NCCN Content is governed by the End-User License Agreement, and you MAY NOT distribute this Content or use it with any artificial intelligence model or tool.
Printed by Galya Basol Kochav on 12/29/2025 12:47:39 PM. Copyright © 2025 National Comprehensive Cancer Network, Inc. All Rights Reserved.

The SENTICOL longitudinal study demonstrated the utility of SLN mapping to uncover unusual lymph drainage patterns.[93,106] It also highlighted limited agreement between lymphoscintigraphy and intraoperative SLN mapping.[106] Additionally, this study revealed that bilateral SLN detection and biopsy provided a more reliable assessment of sentinel nodal metastases and led to fewer false negatives than unilateral SLN biopsy.[90]

The SENTICOL-2 study also demonstrates the benefits of omitting pelvic lymphadenectomy in terms of decreased lymphatic morbidity. The study showed that lymphatic morbidity was significantly lower in the sentinel node resection alone (SN arm) (31.4%) than in the SN and pelvic lymph node dissection (SN + PLND arm) (51.5%; $P = .0046$), as was the rate of postoperative neurological symptoms (7.8% vs. 20.6%; $P = .01$, respectively).[107] Generally, research supports ipsilateral lymphadenectomy if no sentinel nodes are detected on a given side of the pelvis as outlined in the SLN mapping algorithm.[89,90,108]

SENTIX (ENGOT-CX2/CEEGOG-CX1) is another study that evaluated SLN biopsy without pelvic lymph node dissection in patients with early-stage cervical cancer. This international, multicenter, prospective observational trial[109] analyzed 395 preregistered patients with stage IA1 with LVSI to IB2 (≤4 cm or ≤ 2 cm for fertility-sparing treatment) cervical cancer without suspicious lymph nodes on imaging before surgery. Bilateral detection was achieved in 90% (355/395), and it was unaffected by tumor size, tumor stage, or body mass index. No SLNs were found outside the seven anatomical pelvic regions. This study showed that SLN biopsy can achieve high bilateral SLN detection in patients with tumors ≤4 cm.

The final outcome of SLN staging in the SENTIX trial of SLN biopsy in patients with cervical cancer was reported in the recent publication by Kocian et al.[110] In the SENTIX SLN study, 647 out of 733 enrolled patients underwent SLN ultrastaging, identifying 12.5% patients (81/647) with node positive, N1 tumors. Intraoperative detection revealed metastases in 56.8% (46/81) of these patients, categorized into macrometastases (83.7%), micrometastases (26.3%), and isolated tumor cells (9.1%). Ultrastaging identified additional metastatic involvement in 43.2% (35/81) of patients. This study highlights that SLN ultrastaging is a key component of SLN biopsy in cervical cancer and based on this study results, SLN mapping has been added to the primary treatment recommendations for early-stage cervical cancer.

The final survival outcome of this study was presented at ESGO and SGO. In a total of 594 intention-to-treat (ITT) patients (66.0% patients with squamous cell carcinoma with IB disease [IB1 = 46.8%; IB2 = 36.9%]), SLN ultrastaging examination detected N1 SLN in 36 (6.1%) and isolated tumor cells in 20 (3.4%) patients. All N1 patients underwent adjuvant (chemo)radiotherapy. The 2-year DFS was 93.3% (95% CI, 94.9%–91.6%), and overall survival (OS) 97.9% (95% CI, 98.9%–97.0%). Compared to historic recurrence rates of 13% of 54 patients treated with conservative surgery for early CC,[111] after a median follow-up of 47 months, 54 (9.1%) patients relapsed in this study. The recurrence was pelvic, extra-pelvic, and combined in 28 (51.9%), 13 (24.1%), and 13 (24.1%) patients, respectively. A Cox proportional hazards model showed that DFS was related to tumor size (hazard ratio [HR] for >4 cm, 5.23), tumor grade 3 (HR, 4.24), and LVSI (HR, 2.65). No DFS benefit was found for open surgical approach ($P = .39$), and no negative impact of N1 SLN involvement (0.434) was observed. If pelvic nodes are positive from PLN, adjuvant treatment is planned based on the surgical margins, parametrium, and para-aortic lymph nodes.

Based on these collective data, the Panel recommends consideration of SLN mapping algorithm and emphasizes that best detection and mapping results are in tumors <2 cm diameter. Adherence to the SLN mapping

Version 2.2026 © 2025 National Comprehensive Cancer Network® (NCCN®), All rights reserved. NCCN Guidelines®, and this illustration may not be reproduced in any form without the express written permission of NCCN.

PLEASE NOTE that use of this NCCN Content is governed by the End-User License Agreement, and you MAY NOT distribute this Content or use it with any artificial intelligence model or tool.
Printed by Galya Basol Kochav on 12/29/2025 12:47:39 PM. Copyright © 2025 National Comprehensive Cancer Network, Inc. All Rights Reserved.

algorithm is important; surgeons should perform side-specific nodal dissection in any cases of failed mapping and remove all suspicious or grossly enlarged nodes regardless of SLN mapping.[89]

Para-Aortic Lymph Node Assessment

Studies of the incidence and distribution of lymph node metastases in patients with stage IB to IIB cervical cancers suggest that para-aortic lymph node involvement is closely tied to the presence of pelvic lymph node metastases, larger primary tumor size (>2 cm), and metastasis to the common iliac nodes.[112,113]

Analysis of outcomes data from 555 patients who participated in GOG trials (GOG 85, GOG 120, and GOG 165) revealed a more positive prognosis for patients who underwent surgical exclusion of para-aortic lymph node involvement versus those who underwent radiographic determination of para-aortic node involvement.[114] One study examined the efficacy of extending the radiation therapy (RT) field to the para-aortic region in patients with para-aortic lymph node involvement, and showed therapeutic benefit especially in patients with small-volume nodal disease.[115]

The ongoing PAROLA trial aims to demonstrate if chemoradiation with tailored external beam radiation therapy (EBRT) based on surgical staging and pathologic examination of the para-aortic lymph node is associated with improved survival compared with patients staged with radiologic staging only and the accrual is estimated to be completed in 2027.[116]

The Panel recommends para-aortic lymphadenectomy for patients with ≥ stage IB1 disease.

Minimally Invasive Surgical Approaches

The standard and historical approach for radical hysterectomy is with an open abdominal approach.

Previous iterations of the Guidelines had indicated that radical hysterectomy could be performed either via open laparotomy or minimally invasive surgery (MIS) laparoscopic approaches, using either conventional or robotic techniques. Data from previous retrospective reviews and prospective observational studies demonstrated oncologic outcomes following conventional laparoscopic radical hysterectomy that were comparable to open abdominal approaches after 3 to 6 years of follow-up.[117-120] Similarly, multicenter retrospective reviews and matched cohort studies showed comparable oncologic outcomes (disease recurrence and survival rates) for open abdominal and robotic radical hysterectomy after 3 to 5 years of follow-up.[120-123] Additionally, a systematic review and meta-analysis of data from 26 studies found that laparoscopic and robotic radical hysterectomy approaches appeared to provide equivalent intraoperative and short-term postoperative outcomes.[124]

However, several key contemporary reports have questioned the presumed therapeutic equivalency of open versus MIS approaches. A pivotal prospective randomized trial demonstrated that minimally invasive radical hysterectomy was associated with lower rates of DFS and OS than open abdominal radical hysterectomy.[125] This phase III LACC trial (NCT00614211) was designed to provide a definitive comparison of outcomes data in patients with early-stage cervical cancer undergoing total abdominal radical hysterectomy (TARH) or total laparoscopic radical hysterectomy/total robotic radical hysterectomy. At closure, 319 patients had received MIS (84% laparoscopy, 16% robotic) and 312 patients underwent TARH. Ninety-two percent of participants in both surgical arms had stage IB1 disease. MIS was associated with lower rate of DFS than open surgery (3-year DFS, 91.2% vs. 97.1%; HR, 3.74; 95% CI, 1.63–8.58), as well as a decrease in OS (3-year OS, 93.8% vs. 99.0%; HR, 6.00; 95% CI, 1.77–20.30).[125] MIS did not meet predetermined

Version 2.2026 © 2025 National Comprehensive Cancer Network® (NCCN®), All rights reserved. NCCN Guidelines®, and this illustration may not be reproduced in any form without the express written permission of NCCN.

PLEASE NOTE that use of this NCCN Content is governed by the End-User License Agreement, and you MAY NOT distribute this Content or use it with any artificial intelligence model or tool.
Printed by Galya Basol Kochav on 12/29/2025 12:47:39 PM. Copyright © 2025 National Comprehensive Cancer Network, Inc. All Rights Reserved.

noninferiority criteria compared with standard-of-care laparotomy (*P* = .88).

Two other epidemiologic studies also demonstrated that minimally invasive radical hysterectomy was associated with shorter OS than open surgery among patients with stage IA2–IB1 cervical cancer.[126,127] Melamed et al reported on a SEER-based cohort study that compared females with stage IA2 or IB1 cervical cancer who underwent laparotomy (n = 1236) or MIS (n = 1225).[126] Four-year mortality was higher among patients undergoing MIS versus laparotomy (9.1% vs. 5.3%; *P* = .002). Relative survival rates were stable prior to the adoption of MIS techniques (2000–2006), but a significant decline was noted in the years following adoption. Margul et al examined National Cancer Database data from 2010 to 2013 to compare outcomes of patients with stage IB1 cervical cancer who underwent radical hysterectomy performed by open abdominal versus MIS approaches.[127] Although MIS was associated with decreased surgical morbidity and costs, patients with tumor sizes ≥2 cm who underwent MIS had decreased 5-year survival compared to those undergoing open radical hysterectomy (81.3% vs. 90.8%; *P* < .001).[127]

Another systematic review and meta-analysis of 15 high-quality studies comprising 9499 patients[128] confirmed that minimally invasive radical hysterectomy was associated with shorter overall and DFS among women with operable cervical cancer compared with open surgery. Of 9499 patients who underwent radical hysterectomy, 49% received MIS; of these, 57% received robot-assisted laparoscopy. The pooled hazard of recurrence or death was 71% higher among patients who underwent minimally invasive radical hysterectomy compared with those who underwent open surgery (HR, 1.71; 95% CI, 1.36–2.15; *P* < .001), and the hazard of death was 56% higher (HR, 1.56; 95% CI, 1.16–2.11; *P* = .004). No association was found between the prevalence of robot-assisted surgery and the magnitude of association between minimally invasive radical hysterectomy and hazard of recurrence or death or all-cause mortality. This study also concluded that among patients undergoing radical hysterectomy for early-stage cervical cancer, MIS was associated with an elevated risk of recurrence and death compared with open surgery.

These findings stand in contradiction to the earlier referenced series that had suggested therapeutic equivalency of MIS compared to open approaches along with the MIS-associated potential advantages of decreased hospital stay and more rapid patient recovery.[120,121,123,124,129-132]

Given the findings of poorer oncologic outcomes and survival with the MIS techniques compared to open laparotomy, patients should be carefully counseled about the oncologic risks and potential short-term benefits of the different surgical approaches.

Principles of Pathology

Pathologic Assessment

Silva Classification System for HPV-Associated Endocervical Adenocarcinoma

According to the 2018 FIGO criteria[39,40] pathologists use tumor size and stromal depth of invasion (DOI) during clinicopathological staging of cervical cancer. During clinicopathological assessment, pathologists calculate DOI (in millimeters) starting from the basement membrane of the originating epithelium.[133] Endocervical glands normally vary in size, shape, and distance of extension into the underlying stroma. Because of this architectural complexity determining the DOI in endocervical adenocarcinoma (EAC) is difficult.[134,135] Obtaining an accurate DOI measurement is important, as it directly informs treatment decisions. The FIGO staging system does not consider the extent of LVSI, but clinicians also use this information to inform treatment decisions. For instance, patients with stage IA1 cervical cancer (DOI ≤3 mm) whose tumors do not

Version 2.2026 © 2025 National Comprehensive Cancer Network® (NCCN®), All rights reserved. NCCN Guidelines®, and this illustration may not be reproduced in any form without the express written permission of NCCN.

PLEASE NOTE that use of this NCCN Content is governed by the End-User License Agreement, and you MAY NOT distribute this Content or use it with any artificial intelligence model or tool.
Printed by Galya Basol Kochav on 12/29/2025 12:47:39 PM. Copyright © 2025 National Comprehensive Cancer Network, Inc. All Rights Reserved.

have LVSI may be candidates for fertility-sparing conservative treatment (ie, cone biopsy, trachelectomy), as these patients generally have low risk of metastasis and recurrence. Patients with IA2 cervical cancer (DOI >3 mm) may also be candidates for these procedures, but also typically undergo lymphadenectomy with or without SLN mapping due to an increased risk of nodal metastases and recurrence compared to patients with stage IA1 cervical cancer without LVSI. Lymphadenectomy and SLN mapping both may increase morbidity. Therefore, more accurate and reproducible methods of staging EAC are needed to avoid the use of unnecessary procedures in patients who may be at minimal risk of nodal metastases, recurrence, and/or death.

The Silva classification system, which considers the extent of LVSI, stromal invasion, and differentiation, has been proposed to stratify patients more accurately with invasive HPV-associated EAC. A 2013 retrospective study published by Diaz De Vivar et al[136] included patients (n = 352) with stage I–IV usual-type EAC, all of whom previously underwent lymphadenectomy. Pathologists classified their tumor samples into one of three Silva categories: Category A tumors are characterized by no LVSI, well-demarcated glands, and no detachment, which may resemble adenocarcinoma in situ; Category B, some LVSI, focal destructive stromal invasion; Category C, more widespread LVSI, diffuse destructive stromal invasion.

For tumors that had mixed histopathological characteristics, pathologists assigned the highest classification that they observed in the sample. The mean follow-up time was approximately 4.5 years. Patients with category A tumors did not experience any metastases or recurrences during this time. Of those with category B tumors, 4.4% experienced metastases and 1.2% had a recurrence. Those with category C tumors had a marked increase in the rate of metastases and recurrences (23.8% and 22.1%, respectively). Thus, tumors with pattern A invasion (defined by well-demarcated glands with round contours, an absence of single cells, an absence of desmoplastic stromal response, and no lymphatic vascular invasion) have excellent survival and do not have lymph node metastases or recurrences.

Since 2013, several other groups independently published retrospective studies on use of the Silva classification system. Spaans et al 2018[137] classified tumor samples from 82 patients with stage IB–IIA HPV-associated EAC, all of whom previously underwent radical hysterectomy or trachelectomy. The median follow-up time was approximately 10 years. Patients with category A tumors did not experience any metastases, recurrences, or deaths during this time. Of patients with category B tumors, 17% experienced metastases, 13% had a recurrence, and 10% died. Of patients with category C tumors, 37% experienced metastases, 35% had a recurrence, and 35% died. The authors suggested that category B and C tumors may be associated with a higher incidence of somatic hotspot mutations but noted that this observation should be confirmed in prospective studies.

Stolnicu et al[138] used the Silva classification system to stratify 341 patients with HPV-associated and non–HPV-associated stage I through IV EAC who previously underwent surgical resection (ie, cone biopsy, trachelectomy, hysterectomy) and lymphadenectomy. Pathologists first classified tumor specimens into HPV-associated and non–HPV-associated EAC according to IECC criteria[19] and then further classified the tumors by Silva criteria. The authors found that the incidence of metastases in HPV-associated EAC was like that observed by Diaz De Vivar et al.[136] They also reported that 100% of the non–HPV-associated EAC tumors were classified as category C, and therefore concluded that the utility of the Silva classification system is limited to patients with HPV-associated EAC.[138] Stolnicu et al, have also proposed a binary Silva classification system that groups patients into low-risk (patterns A and B without

Version 2.2026 © 2025 National Comprehensive Cancer Network® (NCCN®), All rights reserved. NCCN Guidelines®, and this illustration may not be reproduced in any form without the express written permission of NCCN.

PLEASE NOTE that use of this NCCN Content is governed by the End-User License Agreement, and you MAY NOT distribute this Content or use it with any artificial intelligence model or tool.
Printed by Galya Basol Kochav on 12/29/2025 12:47:39 PM. Copyright © 2025 National Comprehensive Cancer Network, Inc. All Rights Reserved.

lymphovascular invasion) and high-risk (pattern B with lymphovascular invasion and pattern C) categories.[139] FIGO (2019 classification) stage IA–IB1 EACs from 15 international institutions were examined for Silva pattern, presence of LVSI, and other prognostic parameters.

On multivariate analysis, LVSI (P = .008) and Silva pattern (P < .001) were significant factors when comparing stage IA versus IB1 endocervical adenocarcinomas. Overall survival was significantly associated with lymph node metastasis (P = .028); recurrence-free survival was significantly associated with LVSI (P = .002) and stage (1B1 vs. 1A) (P = .002). Five- and 10-year overall survival and recurrence-free survival rates were similar among Silva pattern A cases and Silva pattern B cases without LVSI (P = .165 and P = .171, respectively).

Silva pattern and LVSI are important prognostic factors in stage IA1–IB1 endocervical adenocarcinomas and can supplement FIGO staging.

Data from these retrospective studies suggest that the Silva classification system may help stratify patients with invasive, EAC by risk of metastasis, recurrence, and death. Some expert gynecological pathologists are already using the Silva classification system during clinicopathological staging. The system could be particularly helpful for identifying patients who are at low risk with stage I disease who may be candidates for conservative, fertility-sparing treatment without compromising short- and long-term patient health outcomes. However, prospective studies are needed to confirm these observations. If data from future prospective studies agree with the data cited above, the Silva classification system could potentially be used in conjunction with, or incorporated into, FIGO/AJCC criteria at the time of diagnostic biopsy. To this end, Roma et al[140] proposed that a new three-tier FIGO/AJCC classification system could be created for HPV-associated EAC staging, in which Silva A, B, and C categories would replace DOI measurement. Alternatively, DOI could be revised to specify the depth of destructive invasion, and the Silva classification system could then be used in conjunction.[140]

GOG/Sedlis Criteria

The Sedlis Criteria, which are intermediate risk factors used to guide adjuvant treatment decisions, include: 1) greater than one-third stromal invasion; 2) capillary lymphatic space involvement; or 3) cervical tumor diameters >4 cm.[141] However, potentially important risk factors for recurrence may not be limited to the Sedlis Criteria. Additional risk factors for consideration include tumor histology (eg, adenocarcinoma component)[142,143] and close or positive surgical margins.[144,145]

Sedlis criteria were developed primarily for squamous cell carcinoma. Histology-specific nomograms for squamous and adenocarcinoma lesions may provide a more contemporary tool to model the risk of recurrence and base adjuvant recommendations. In an ancillary analysis of GOG 49, 92, and 14 studies,[146] among 715 patients with SCC and 105 with AC, 20% with SCC and 17% with AC recurred. For SCC, LVSI (HR, 1.58; 95% CI, 1.12–2.22), tumor size (TS ≥4 cm: HR, 2.67; CI, 1.67–4.29), and depth of invasion (DOI: middle 1/3, HR, 4.31; 95% CI, 1.81–10.26; deep 1/3, HR, 7.05; 95% CI, 2.99–16.64) were associated with recurrence. For AC, only TS ≥4 cm, was associated with recurrence (HR, 4.69; 95% CI, 1.25–17.63). For both histologies, there was an interaction effect between TS and LVSI. For those with SCC, DOI was most associated with recurrence (16% risk); for AC, TS conferred a 15% risk with negative LVSI versus a 25% risk with positive LVSI. While for squamous lesions, DOI is an important risk factor of recurrence, for adenocarcinoma, tumor size is an important risk factor of recurrence, and this risk becomes more pronounced with the presence of LVSI. It is also important to note that the risk factors may not be limited to the Sedlis criteria. The NCCN Guidelines recommend both GOG and Sedlis criteria to be met for the use of radiation

Version 2.2026 © 2025 National Comprehensive Cancer Network® (NCCN®), All rights reserved. NCCN Guidelines®, and this illustration may not be reproduced in any form without the express written permission of NCCN.

as adjuvant treatment for negative nodes, negative margins, and negative parametrium (See *Adjuvant Treatment*).

Prognostic and Predictive Biomarkers

Over the years, systemic therapy options for cervical cancer have undergone a paradigm shift with the emergence of biomarkers and the growing number of newer treatment options available with meaningful improvement in survival rates. As the importance of testing for the presence of certain biomarkers in advanced disease is well recognized, the availability of several agents targeting these specific biomarkers have led to improved outcomes in patients. Testing for these biomarkers is critical to guide treatment selection especially for patients with advanced or recurrent disease. While predictive biomarkers indicate how certain patients are likely to respond to treatment, either in terms of efficacy or toxicity and forecasts pharmacodynamic resistance or toxicity and can guide initial treatment decisions by identifying potentially successful drugs and potentially minimizing toxicity, prognostic biomarkers predict the overall survival in certain patients, independent of therapy and can guide treatment decision-making, monitor disease progression, and detect recurrence.[147,148]

Several biomarker-based immune-oncologic agents have been added to the Guidelines in the management of recurrent/metastatic cervical cancer in recent years (see *Systemic Therapy Recommendations*) and the NCCN Panel recommends comprehensive molecular profiling as determined by a U.S. Food and Drug Administration (FDA)-approved assay, or a validated test performed in a Clinical Laboratory Improvement Amendments (CLIA)-certified laboratory.

PD-L1

The NCCN Panel recommends programmed death-ligand 1 (PD-L1) testing by an FDA-approved assay, or a validated test performed in a CLIA-certified laboratory for patients with recurrent, progressive, or metastatic disease to help guide better treatment options in first-line, second-line, or subsequent therapy.[149]

The FDA approved pembrolizumab plus chemotherapy, with or without bevacizumab for patients with persistent, recurrent, or metastatic cervical cancer whose tumors express PD-L1 (combined positive score [CPS] ≥1) based on Keynote-826 study.[149] The NCCN Panel also recommends the same as a preferred regimen (Category 1) for first-line therapy for recurrent or metastatic disease.

KEYNOTE-158 is another phase II basket study that evaluates the use of pembrolizumab in multiple cancer types including cervical cancer.[150] The interim results from previously treated patients with advanced cervical cancer demonstrated the durable antitumor activity and manageable safety of pembrolizumab monotherapy. Out of 98 patients treated, 82 (83.7%) had PD-L1-positive tumors (CPS ≥1), 77 having previously received one or more lines of chemotherapy for recurrent or metastatic disease. The primary end point, objective response rate (ORR) was 12.2% (95% CI, 6.5%–20.4%), with three complete and nine partial responses. All 12 responses were in patients with PD-L1-positive tumors, for an ORR of 14.6% (95% CI, 7.8%–24.2%); 14.3% (95% CI, 7.4%–24.1%) of these responses were in those who had received one or more lines of chemotherapy for recurrent or metastatic disease. Based on these results, the FDA granted accelerated approval of pembrolizumab for patients with advanced PD-L1–positive cervical cancer who experienced progression during or after chemotherapy. NCCN also recommends pembrolizumab as a preferred regimen for patients who are PD-L1–positive for second-line or subsequent therapy.

Nivolumab, a checkpoint inhibitor, has shown efficacy in patients with recurrent/metastatic cervical cancer who received at least one prior chemotherapy regimen. The Checkmate-358, phase 1/2, single-arm trial evaluated 19 patients with advanced, pretreated, HPV-associated cervical tumors.[151] The ORR was 26.3% (95% CI, 9.1%–51.2%) and

Version 2.2026 © 2025 National Comprehensive Cancer Network® (NCCN®), All rights reserved. NCCN Guidelines®, and this illustration may not be reproduced in any form without the express written permission of NCCN.

PLEASE NOTE that use of this NCCN Content is governed by the End-User License Agreement, and you MAY NOT distribute this Content or use it with any artificial intelligence model or tool.
Printed by Galya Basol Kochav on 12/29/2025 12:47:39 PM. Copyright © 2025 National Comprehensive Cancer Network, Inc. All Rights Reserved.

disease control rate was 68.4% (95% CI, 43.4%–87.4%). The 12-month OS rate was 77.5% (95% CI, 50.5%–91.0%). The phase 2 trial (NRG-GY002) showed low anti-tumor activity of nivolumab in 25 patients with pretreated persistent/recurrent cervical cancer; 36% of the patients had stable disease (90% CI, 20.2%−54.4%) as best response with median duration of 5.7 months, and progression-free survival (PFS) and OS at 6 months was 16% and 78.4%, respectively.[152,153]

Based on these results, in version 1.2023 of the NCCN Guidelines for Cervical Cancer, the Panel moved nivolumab from preferred, second-line or subsequent therapy options to the “useful in certain circumstances” category for PD-L1–positive tumors.

Tisotumab vedotin (TV) with pembrolizumab has been added as another option for patients with PD-L1 positive disease who have not received prior immuno-oncology (IO) therapy under “useful in certain circumstances” for second-line or subsequent therapy. This addition is based on innovaTV 205/GOG-3024/ENGOT-cx8 trial,[154] a phase IB/II study that evaluated TV in combination with carboplatin as first-line (1L) treatment or with pembrolizumab as 1L or second-/third-line treatment with primary endpoint being ORR in the dose-expansion cohort. A key exclusion criterion in this trial was previous treatment with anti–PD-1 or anti–PD-L1 therapy. In dose expansion cohort (n = 101), the ORR was 40.6% (95% CI, 23.7–59.4) with TV + pembrolizumab (N = 32) in first line, and 35.3% (95% CI, 19.7–53.5) with TV + pembrolizumab (N = 34) in second or subsequent setting compared to 54.5% (95% CI, 36.4–71.9) with 1L TV + carboplatin (N = 33). The TV + pembrolizumab arms comprised predominantly of patients with PD-L1 positive disease (96.6% and 81.5% in 1L and 2L/3L settings, respectively), which warranted the addition of PD-L1 qualifier for this regimen.[154]

Mismatch Repair /Microsatellite Instability

Tumors with mismatch repair deficiency (dMMR) represent approximately 2% to 4% of all diagnosed cancers and have a unique genetic signature, harboring 10- to 100-times more mutations than mismatch repair–proficient tumors. These dMMR tumors have high microsatellite instability (MSI-H) and harbor 100 to 1000 of somatic mutations that encode potential neoantigens and are likely to be immunogenic. The Keynote-158 trial included patients with non-colorectal MSI-H/dMMR tumors in cohort K and the results demonstrated the clinical benefit of pembrolizumab in patients with previously treated unresectable or metastatic MSI-H/dMMR non-colorectal cancer.[155]

Of 233 patients with MSI-H/dMMR advanced non-colorectal cancer who experienced failure with prior therapy who received pembrolizumab, the objective response rate was 34.3% (95% CI, 28.3%–40.8%). Median PFS was 4.1 months (95% CI, 2.4–4.9 months) and median overall survival was 23.5 months (95% CI, 13.5 months – not reached). The NCCN Panel recommends pembrolizumab as a preferred regimen for MSI-H/dMMR tumors as a second-line or subsequent therapy for recurrent or metastatic disease.

TMB

Tumor mutational burden (TMB), defined as the total number of somatic mutations per coding area of a tumor genome, is a measure of all non-synonymous coding mutations in a tumor exome and highly mutated tumors can produce many neoantigens, some of which might increase T-cell reactivity. High TMB has been demonstrated to be associated with treatment response to pembrolizumab.

In a prospective analysis of the multi-cohort, open-label, non-randomized phase 2 KEYNOTE-158 study,[156] the association between antitumor activity and tissue-tumor mutational burden (tTMB) in patients who received at least one dose of pembrolizumab were assessed and

Version 2.2026 © 2025 National Comprehensive Cancer Network® (NCCN®), All rights reserved. NCCN Guidelines®, and this illustration may not be reproduced in any form without the express written permission of NCCN.

tTMB-high status identified a subgroup of patients who could have a robust tumor response to pembrolizumab monotherapy. Out of 790 TMB evaluable, treated patients enrolled by at least 26 weeks before data cutoff, 102 (13%) patients were tTMB-high (<10 mutations per megabase) and 688 (87%) patients had non-tTMB–high status. With a median study follow-up of 37.1 months, the objective responses were observed in 30 (29%; 95% CI, 21–39) of 102 patients in the tTMB-high group and 43 (6%; 95% CI, 5–8) of 688 in the non-tTMB–high group. Cervical cancer had the highest proportion of patients with tTMB-high status (21%) and objective responses were observed in 5/16 patients with tTMB-high status and 7/59 patients with non-tTMB–high status within the cervical cohort.

The NCCN Panel recommends TMB testing by an FDA-approved assay, or a validated test performed in a CLIA-certified laboratory and recommends pembrolizumab as a preferred regimen for the treatment of patients with TMB-H [≥10 mutations/mega base (mut/Mb)] tumors that have progressed following prior treatment and who have no satisfactory alternative treatment options (second-line or subsequent therapy).

NTRK Gene Fusion

NTRK gene fusions are found in about 1% of all solid tumors. An integrated efficacy and safety analysis of patients with metastatic or locally advanced solid tumors harboring oncogenic *NTRK1*, *NTRK2*, and *NTRK3* gene fusions treated with entrectinib in three ongoing, early-phase trials (ALKA-372–001, STARTRK-1, and STARTRK-2) showed durable and clinically meaningful responses with manageable safety profile.[157] The efficacy-evaluable population comprised of 54 adults with advanced or metastatic NTRK fusion-positive solid tumors comprising 10 different tumor types and 19 different histologies, including one patient with cervical sarcoma. Out of 54 patients, 31 (57%; 95% CI, 43.2–70.8) patients had an objective response, of which four (7%) were complete response (CR) and 27 (50%) were partial responses. Median duration of response (DoR) was 10 months (95% CI, 7.1 – not estimable [NE]). In a long-term efficacy and safety analysis in 121 patients at median follow-up of 25.8 months, 61% reported complete or partial responses, median DoR was 20 months (95% CI, 10.1–19.9), and median PFS was 13.8 months (95% CI, 10.1–19.9).[158]

In another primary analysis, the efficacy and safety of larotrectinib was reported in 55 patients enrolled in three clinical studies who had locally advanced or metastatic tumors with *NTRK* gene fusions and had progressed on standard chemotherapy received previously. The three clinical trials included a phase 1 dose-finding study in adults, phase 1–2 dose-finding study in a pediatric population, and a phase 2, single-arm, basket trial.[159] The overall response rate of larotrectinib in these patients was 75% (95% CI, 61%–85%) with 13% CR and 62% partial responses with median DoR and PFS not reached at the time. In a long-term follow-up analysis, out of 153 patients, 121 patients (79%; 95% CI, 72–85) had objective response with 16% having a CR, 63% with partial response, and 12% with a stable disease. The median DoR was 35.2 months (22.8 – NE) and the median PFS was 28.3 months.[160] Both larotrectinib and entrectinib are FDA-approved for *NTRK* gene fusion solid tumors for patients who have progressed following treatment or have no satisfactory standard therapy.[161,162] Repotrectinib, another TKI for the treatment of patients harboring *NTRK* gene fusion was granted accelerated approval based on phase 1/2 TRIDENT-1 trial. The study demonstrated that TRK TKI–naive patients with advanced solid tumors harboring NTRK fusions (n = 40) achieved an ORR of 58% (95% CI, 41%–73%). The median DoR in this population was NE, and the 12-month DoR rate was 86%.[163]

The NCCN Guidelines recommend larotrectenib, entrectinib, and repotrectinib for *NTRK* gene fusion-positive tumors under useful in certain circumstances category in second-line or subsequent therapy setting.

Version 2.2026 © 2025 National Comprehensive Cancer Network® (NCCN®), All rights reserved. NCCN Guidelines®, and this illustration may not be reproduced in any form without the express written permission of NCCN.

PLEASE NOTE that use of this NCCN Content is governed by the End-User License Agreement, and you MAY NOT distribute this Content or use it with any artificial intelligence model or tool.
Printed by Galya Basol Kochav on 12/29/2025 12:47:39 PM. Copyright © 2025 National Comprehensive Cancer Network, Inc. All Rights Reserved.

HER2

HER2 expression is observed in a wide range of solid tumors and is an established prognostic biomarker for breast, gastric, and colorectal cancers. Cervical cancer has shown HER2 positivity rate of approximately 2% to 6% in the literature.[164-166] Trastuzumab deruxtecan is an antibody-drug conjugate that contains the humanized anti-HER2 monoclonal antibody trastuzumab attached to the topoisomerase inhibitor deruxtecan.[167] Another tumor-agnostic study evaluated the durability and clinically meaningful response of trastuzumab deruxtecan across multiple HER2-expressing (immunohistochemistry [IHC] 3+ or 2+) advanced solid tumor types in patients who progressed on prior therapy or who have no satisfactory alternative treatment options.

The DESTINY-PanTumor02 is an open-label, multicenter, phase 2 trial that evaluated trastuzumab deruxtecan (T-DXd) on 267 patients with HER2-expressing (IHC 3+ or 2+) locally advanced or metastatic disease after ≥1 systemic treatment or without alternative treatments. The study included 40 patients with cervical cancer with IHC2+ or 3+ expression of HER2. Overall, the ORR was 37.1% (n = 99; [95% CI, 31.3–43.2]), the median PFS was 6.9 months (95% CI, 5.6–8.0); and the median OS was 13.4 months (95% CI, 11.9–15.5). In patients with cervical cancer, the confirmed ORR was 50% and for HER2 IHC3+ cohort, the ORR was 75% and the median OS was 13.6 months.[168] The Panel recommends HER2 IHC testing (with reflex to HER2 fluorescence in situ hybridization [FISH] for equivocal IHC) for advanced, metastatic, or recurrent cervical carcinoma. The guideline includes fam-trastuzumab deruxtecan-nxki as category 2A, useful in certain circumstances, second-line/subsequent therapy option for HER2-positive tumors (IHC 3+ or 2+).
Neratinib, an irreversible pan-HER tyrosine kinase inhibitor, was FDA approved for extended adjuvant treatment of HER2-positive early stage breast cancer. (https://www.accessdata.fda.gov/scripts/cder/daf/index.cfm). It had shown promising activity in several HER2-mutant cancer types in the phase 2 SUMMIT basket trial.[169] Based on the results from cervical cancer cohort,[170] Neratinib has been added as a recommendation option for HER2 mutant tumors under useful in certain circumstances category. Out of 18 endocervical adenocarcinoma patients, four patients had confirmed partial responses (ORR 18.2%; 95% CI 5.2–40.3); 6 had stable disease ≥16 weeks (clinical benefit rate [CBR], 45.5%; 95% CI, 24.4–67.8). Median DoR was 7.6 months (95% CI, 5.6–12.3). Median PFS was 5.1 months (95% CI, 1.7–7.2). The most common HER2 variant was S310F/Y mutation (n = 13; 59.1%).

RET Gene Fusion

The rearranged during transfection (*RET*) gene fusions most commonly occur in thyroid and non-small cell lung cancers and are observed in <1% of patients with other solid tumors. The prognosis of disease in this small subset of patients who have progressed on or following prior systemic therapy is poor. Phase 1/2, Libretto-001, multicenter, open-label trial evaluated the efficacy of selpercatinib in patients with *RET*-mutant advanced solid tumors. In an interim analysis of the trial in a tumor-agnostic population, the efficacy and safety of selpercatinib was investigated in 41 patients with *RET* fusion-positive solid tumors (other than non-small cell lung cancer and thyroid cancer) with disease progression on or after previous systemic therapies or who had no satisfactory therapeutic options. The ORR was 44% (95% CI, 28.5–60.3), with median duration of response 24.5 months (95% CI, 9.2 – NE).[171,172] Selpercatinib received tumor-agnostic approval by the FDA for patients with solid tumors with a *RET* gene fusion that has progressed on or following prior systemic treatment or who have no satisfactory alternative treatment options. The NCCN Panel recommends that *RET* gene fusion testing may be considered for patients with locally advanced or metastatic cervical cancer. The NCCN Panel also recommends selpercatinib as a

Version 2.2026 © 2025 National Comprehensive Cancer Network® (NCCN®), All rights reserved. NCCN Guidelines®, and this illustration may not be reproduced in any form without the express written permission of NCCN.

PLEASE NOTE that use of this NCCN Content is governed by the End-User License Agreement, and you MAY NOT distribute this Content or use it with any artificial intelligence model or tool.
Printed by Galya Basol Kochav on 12/29/2025 12:47:39 PM. Copyright © 2025 National Comprehensive Cancer Network, Inc. All Rights Reserved.

biomarker-directed second-line/subsequent therapy under useful in certain circumstances category for recurrent or metastatic disease.

HPV Status/p16

Approximately 80% to 90% of cervical carcinomas worldwide is cervical SCC, a squamous epithelial tumor with stromal invasion and/or exophytic invasion and >90% of cervical SCCs are HPV-associated, with HR-HPV 16 and 18 being the most common types. HPV-independent cervical SCC is a relatively recently described entity, with 5% to 7% of cervical SCCs reported to be HPV-negative. Adenocarcinomas of the cervix can be HPV-associated (HR-HPV types 18, 16, and 45 most commonly) or HPV-independent. Adenosquamous carcinoma, an epithelial tumor with squamous and glandular differentiation, accounts for approximately 5% to 6% of all cervical carcinomas and the clinical outcomes are like cervical adenocarcinoma.

Utility of p16 IHC and/or molecular HPV typing is recommended for establishing HPV association in SCC. Almost all HPV-associated SCCs show strong and diffuse p16 overexpression in nuclei and cytoplasm by IHC. Determining the HPV status is recommended as HPV-associated EAC have shown better clinical outcomes compared with HPV-independent adenocarcinomas. 95% of HPV-associated carcinomas will demonstrate block-type p16 expression by IHC. Of note, endometrial carcinomas (high grade endometrioid, serous and clear cell carcinomas) can also express p16; rarely p16 negative cases can occur from methylation-induced activation; and results of p16 were shown to be not as reproducible when performed on older or poorly preserved tissue blocks. When available, HR-HPV in situ hybridization (ISH) can be utilized, as it is as sensitive and more specific than p16 IHC. While PCR can confirm HPV infection, it has lower sensitivity and specificity and does not provide ascertainment that HPV is present within the neoplastic cells. The IHC for p16 usually shows overexpression in both squamous and glandular components of ASC. Additional IHC stains such as CK7, carcinoembryonic antigen (CEA), and PAX8 may be utilized to highlight the glandular component, while p63 and p40 highlight the squamous component.

HPV-Independent Adenocarcinoma

HPV-independent endocervical adenocarcinomas include gastric, clear cell, mesonephric, and endometrioid types. Gastric type makes up approximately 10% to 15% of cervical adenocarcinomas (with up to 25% noted in Japan). It is found in association with Peutz-Jeghers syndrome (STK11 mutation), and while typically negative for p16 block expression, it may show mutated p53 expression in approximately 50% of cases. These tumors show a high prevalence of invasion, extrauterine spread and present at an advanced stage. Mesonephric type demonstrates mesonephric (Wolffian) differentiation and is associated with mesonephric remnants. It typically is located deep in the lateral wall and histologically demonstrates architectural crowding, haphazard infiltration, atypia, mitotic activity, and necrosis. GATA-3 and CD10 IHC stains will be positive in the tumor and associated mesonephric remnants. Clear cell carcinomas make up 3% to 4% of endocervical adenocarcinomas, occurring sporadically or in association with in-utero diethylstilbestrol (DES) exposure. These tumors may demonstrate diffuse p16 expression despite the absence of HPV infection. In these instances, HR-HPV ISH can be utilized. Endometrioid carcinoma is quite uncommon–approximating 1% of primary endocervical adenocarcinomas–and may be present in the setting of endometriosis; however, a primary endometrial carcinoma must be ruled out. Utilizing a panel of immunohistochemical stains (vimentin, ER, p16, and monoclonal CEA) may be helpful in differentiating between endocervical and endometrial carcinoma. Typically, endometrioid adenocarcinoma will express vimentin and ER, while endocervical adenocarcinoma is positive for mCEA and p16 (when HPV-associated).

Version 2.2026 © 2025 National Comprehensive Cancer Network® (NCCN®), All rights reserved. NCCN Guidelines®, and this illustration may not be reproduced in any form without the express written permission of NCCN.

PLEASE NOTE that use of this NCCN Content is governed by the End-User License Agreement, and you MAY NOT distribute this Content or use it with any artificial intelligence model or tool.
Printed by Galya Basol Kochav on 12/29/2025 12:47:39 PM. Copyright © 2025 National Comprehensive Cancer Network, Inc. All Rights Reserved.

Primary Treatment

Recommendations by stage are based on the revised 2018 FIGO staging by Bhatla et al.[39] However, trial data cited within this section primarily utilized the previous 2009 FIGO staging system.[41]

The primary treatment of early-stage cervical cancer is either surgery or RT. Surgery is typically reserved for early-stage disease, fertility-preservation, and smaller lesions, such as stage IA, IB1, IB2, and selected IIA1.[173] The Panel agrees that concurrent chemoradiation is generally the primary treatment of choice for stages IB3–IVA disease based on the results of five randomized clinical trials.[174,175] Chemoradiation can also be used for patients who are not candidates for hysterectomy. Based on Keynote-A18,[176] pembrolizumab can be added to chemoradiation in select patients with stage IIIA–IVA disease. Although few studies have assessed treatment specifically for adenocarcinomas, they are typically treated in a similar manner to squamous cell carcinomas.[177-179]

Pelvic RT or chemoradiation will invariably lead to ovarian failure in patients undergoing premenopause.[180] To preserve intrinsic hormonal function, ovarian transposition may be considered before pelvic RT for select patients younger than 45 years of age with squamous cell cancers.[181,182]

Early-Stage Disease

After careful clinical evaluation and staging, the primary treatment of early-stage cervical cancer is either surgery or RT. The treatment schema is stratified using the FIGO 2018 staging system. A fertility-sparing algorithm may be applied to select patients with stage IA, IB1, and certain cases of IB2 disease. Fertility-sparing surgery is generally not recommended for patients with small cell neuroendocrine tumors, gastric type adenocarcinoma, or adenoma malignum (minimal deviation adenocarcinoma) because of its high-risk nature and a paucity of data.

Stage IA1 Disease

Recommended options for stage IA1 disease depend on the results of cone biopsy and whether patients 1) want to preserve their fertility; 2) are medically operable; or 3) have LVSI. Based on SENTIX trial data,[183] which emphasizes the importance of SLN ultrastaging, SLN mapping is recommended before considering pelvic lymphadenectomy. The extent of the lymphadenectomy depends on whether pelvic nodal disease and/or LVSI are present and the size of the tumors.

Fertility-Sparing

<u>Stage IA1 no LVSI (fertility sparing), stage IA1 with LVSI</u>

For patients who desire fertility preservation, cone biopsy with or without SLN mapping or pelvic lymphadenectomy is recommended.[100,183-185] The goal of cone biopsy is margins that are negative for invasive disease and high-grade squamous intraepithelial lesion (HSIL). For patients with negative margins after cone biopsy and no findings of LVSI, observation may be an option if fertility preservation is desired. For patients with positive margins after cone biopsy, options include repeat cone biopsy to better evaluate depth of invasion (to rule out stage IA2/IB disease) or a radical trachelectomy. In studies of patients who had positive margins after conization, predictors of residual disease included positive endocervical curettage, combined endocervical margin and endocervical curettage, and volume of disease.[144,186,187] For patients with stage IA1 disease with LVSI, conization (with negative margins) plus laparoscopic pelvic SLN mapping/lymphadenectomy or radical trachelectomy and SLN mapping/pelvic lymphadenectomy[70,188-191] is a reasonable strategy. After childbearing is complete, hysterectomy can be considered for patients who have had either radical trachelectomy or a cone biopsy for

Version 2.2026 © 2025 National Comprehensive Cancer Network® (NCCN®), All rights reserved. NCCN Guidelines®, and this illustration may not be reproduced in any form without the express written permission of NCCN.

PLEASE NOTE that use of this NCCN Content is governed by the End-User License Agreement, and you MAY NOT distribute this Content or use it with any artificial intelligence model or tool.
Printed by Galya Basol Kochav on 12/29/2025 12:47:39 PM. Copyright © 2025 National Comprehensive Cancer Network, Inc. All Rights Reserved.

early-stage disease if they have chronic, persistent HPV infection, persistent abnormal Pap tests, or they desire this surgery.
For young (<45 years) patients who are undergoing premenopausal with early-stage squamous cell carcinoma who opt for ovarian preservation (ie, hysterectomy only), the rate of ovarian metastases is low.[192,193] Since GOG-0278 trial[60] also included patients with stage IA1 disease with LVSI, cone biopsy with negative margins with SLN mapping or pelvic lymphadenectomy are recommended for this group.

Non–Fertility-Sparing
For patients who are medically operable and who do not desire fertility preservation, recommended treatment includes either surgery or RT.

Stage IA1 no LVSI
For patients with IA1 disease without LVSI, based on the biopsy results of cone excision, primary treatment is determined based on the margin status and if medically and technically operable. For patients with negative margins after cone biopsy, observation is recommended for those who are medically inoperable or those who refuse surgery. If the tumor is medically operable with negative margins, Type A hysterectomy is commonly recommended. For patients with positive margins for carcinoma and who are medically inoperable for hysterectomy, physicians can consider repeating cone biopsy to better evaluate depth of invasion to rule out stage 1A2/IB1. Radiation therapy (brachytherapy with or without EBRT) can also be considered. If medically operable with positive margins, repeating cone biopsy can be considered to evaluate depth of invasion to rule out stage IA2/IB1 disease. If margins are positive for dysplasia, Type A hysterectomy and if margins are positive for carcinoma, Type B hysterectomy with SLN mapping or bilateral pelvic lymphadenectomy are recommended.

Stage IA1 with LVSI
If LVSI is present based on cone/LEEP, SLN mapping or pelvic lymphadenectomy is recommended along with Type A hysterectomy (if margins are positive for dysplasia) or Type B (if margins are positive for carcinoma). For stage IA1 with LVSI and positive/negative margins for dysplasia or carcinoma, radiation therapy (pelvic EBRT and brachytherapy) is another option to consider. Stage IA1 with LVSI and negative margins can also be treated with Type A hysterectomy with SLN mapping or pelvic lymphadenectomy.

Pelvic EBRT with brachytherapy (traditionally 70–80 Gy to total point A dose) is a treatment option for patients who are medically inoperable or who refuse surgery.[194] These doses are recommended for most patients based on summation of conventional external-beam fractionation and low-dose rate (40–70 cGy/h) brachytherapy equivalents. Treatment should be modified based on normal tissue tolerance, fractionation, and size of target volume or on biologic equivalence calculations when using high-dose rate brachytherapy.

Adjuvant Treatment
Adjuvant treatment is indicated after hysterectomy depending on surgical findings and disease stage. Observation is appropriate for patients with stage IA1, IA2, IB, IIA1, or IIA2 disease who have negative nodes, negative margins, negative parametria, and no cervical risk factors after hysterectomy (Sedlis Criteria). However, adjuvant treatment is indicated after hysterectomy if pathologic risk factors are discovered.

Pelvic EBRT is recommended (category 1) with (or without) concurrent platinum-containing chemotherapy (category 2B for chemotherapy) for patients with stage IA or IB disease who have negative lymph nodes after surgery but have large primary tumors, deep stromal invasion, and/or LVSI that meet GOG/Sedlis criteria.[141,195-198] Recommended radiosensitizing regimens include cisplatin (preferred), carboplatin (preferred if cisplatin intolerant), or capecitabine/mitomycin, gemcitabine, or paclitaxel.

Version 2.2026 © 2025 National Comprehensive Cancer Network® (NCCN®), All rights reserved. NCCN Guidelines®, and this illustration may not be reproduced in any form without the express written permission of NCCN.

PLEASE NOTE that use of this NCCN Content is governed by the End-User License Agreement, and you MAY NOT distribute this Content or use it with any artificial intelligence model or tool.
Printed by Galya Basol Kochav on 12/29/2025 12:47:39 PM. Copyright © 2025 National Comprehensive Cancer Network, Inc. All Rights Reserved.

Adjuvant pelvic RT alone versus no further therapy was tested in a randomized trial (GOG 92) of selected patients with node-negative stage IB carcinoma of the cervix after hysterectomy and pelvic lymphadenectomy.[141] Patients were considered to have intermediate-risk disease and were eligible for this trial if they had at least two of the following risk factors (commonly referred to as Sedlis Criteria): 1) greater than one-third stromal invasion; 2) capillary lymphatic space involvement; or 3) cervical tumor diameters >4 cm. Patients with positive lymph nodes or involved surgical margins were excluded. At 2 years, the recurrence-free rates were 88% for adjuvant RT versus 79% for the no-adjuvant-treatment group. After long-term follow-up (12 years), an updated analysis confirmed that adjuvant pelvic RT increased PFS; a clear trend towards improved overall survival was noted ($P = .07$).[195] The role of concurrent cisplatin/RT in patients with intermediate-risk disease is currently being evaluated in an international phase III randomized trial (GOG 263, NCT01101451).

Potentially important risk factors for recurrence may not be limited to the GOG/ Sedlis Criteria (ie, stromal invasion, LVSI, primary tumor size). Additional risk factors for consideration include tumor histology (eg, adenocarcinoma component)[142,143] and close or positive surgical margins.[144,145]

Postoperative pelvic EBRT with concurrent platinum-containing chemotherapy (category 1)[199] with (or without) brachytherapy is recommended for patients with positive pelvic nodes, positive surgical margin, and/or positive parametrium; these patients are considered to have “high-risk” disease. Vaginal brachytherapy may be a useful boost for those with positive vaginal mucosal margins. Adjuvant concurrent chemoradiation significantly improves overall survival for patients with high-risk, early-stage disease (those with positive pelvic nodes, parametrial extension, and/or positive margins) who undergo radical hysterectomy and pelvic lymphadenectomy.[199] The Intergroup trial 0107/GOG 109 showed a statistically significant benefit of adjuvant pelvic radiation with concurrent cisplatin and fluorouracil in the treatment of patients with stage IA2, IB, or IIA disease who had positive lymph nodes, positive margins, and/or microscopic parametrial involvement found at surgery.[199] A study re-evaluated these findings from GOG 109 in a population-based cohort (n = 3053) in the National Cancer Database, confirming the survival benefit of adjuvant chemoradiation but suggesting that this benefit may be best realized in patients with lymph node involvement.[200]

Depending on the results of primary surgery, imaging may be recommended to determine whether distant metastases are present. In patients who are positive for distant metastases, perform biopsy of suspicious areas as indicated. For patients without distant metastases (including positive pelvic and/or para-aortic lymph nodes and/or positive surgical margins and/or positive parametrium), recommended treatment is extended-field EBRT with concurrent platinum-containing chemotherapy and with (or without) brachytherapy. Recommended radio sensitizing regimens include cisplatin (preferred), carboplatin (preferred if cisplatin intolerant), or capecitabine/mitomycin, gemcitabine or paclitaxel. For patients with distant metastases, recommended treatment is systemic chemotherapy with (or without) individualized EBRT.[201] Patients with positive para-aortic lymph nodes who are positive for distant metastases after biopsy are treated with systemic chemotherapy with (or without) individualized EBRT.[201]

Stage IA2–IB1 Disease

Recommendations for stage IA2 depend upon whether a patient wishes to preserve their fertility and if the disease is medically operable.

Version 2.2026 © 2025 National Comprehensive Cancer Network® (NCCN®), All rights reserved. NCCN Guidelines®, and this illustration may not be reproduced in any form without the express written permission of NCCN.

PLEASE NOTE that use of this NCCN Content is governed by the End-User License Agreement, and you MAY NOT distribute this Content or use it with any artificial intelligence model or tool.
Printed by Galya Basol Kochav on 12/29/2025 12:47:39 PM. Copyright © 2025 National Comprehensive Cancer Network, Inc. All Rights Reserved.

Fertility-Sparing

For stage IA2–IB1 based on cone biopsy and all conservative surgery criteria based on CONCERV[42] and GOG-0278 trials[60] met including no LVSI (preferred), negative cone margins for cancer, squamous cell (any grade) or usual type adenocarcinoma (grade 1 or 2 only) (preferred), tumor size ≤2 cm, depth of invasion ≤10 mm on LEEP/cone and negative imaging for locoregional disease, cone biopsy with negative margins with SLN mapping or pelvic lymphadenectomy is recommended.

Non–Fertility-Sparing

The recommended surgical option for stage 1A2–IB1 with no evidence of LVSI and upon meeting conservative surgery criteria based on CONCERV[42] and GOG-0278 trials[60] is Type A hysterectomy with SLN mapping or pelvic lymphadenectomy. This treatment recommendation is also supported by the results of the SHAPE trial.[202] In a multicenter, randomized, noninferiority trial comparing radical hysterectomy with simple hysterectomy including lymph-node assessment in patients with low-risk cervical cancer (lesions of ≤2 cm with limited stromal invasion), 700 patients were randomized into simple hysterectomy group and radical hysterectomy group and cancer recurrence was analyzed. With a median follow-up time of 4.5 years, the incidence of pelvic recurrence at 3 years was 2.17% in the radical hysterectomy group and 2.52% in the simple hysterectomy group and the incidence of urinary retention in the simple hysterectomy group was also lower than that in the radical hysterectomy group within 4 weeks after surgery (0.6% vs. 11.0%; $P < .001$) and beyond 4 weeks (0.6% vs. 9.9%; $P < .001$). The SHAPE trial also included patients with adenocarcinoma grade 3 (2.7%), invasion of the lymphovascular space (13.4%), and residual disease in the hysterectomy specimen (45.8%). The overall incidence of recurrence in the SHAPE and ConCerv trials are similar (3.6% and 3.5%, respectively).[60,202]

Adjuvant treatment is indicated after hysterectomy depending on surgical findings and disease stage. Observation is appropriate for patients with stage IA1, IA2, IB, IIA1, or IIA2 disease who have negative nodes, negative margins, negative parametria, and no cervical risk factors after hysterectomy (Sedlis Criteria).

Stage IB and IIA Disease

Depending on their stage and disease bulk, patients with stage IB or IIA tumors can be treated with surgery, RT, or concurrent chemoradiation. A combined PET/CT scan can be performed to rule out extra pelvic disease before deciding how to treat these patients.
Neck/chest/abdomen/pelvis/groin FDG-PET/CT is preferred to evaluate metastatic disease. A chest/abdomen/pelvis CT or FDG-PET/MRI can also be performed. Pelvic MRI with or without contrast is preferred to assess local disease extent. Based on a meta-analysis of three GOG studies (GOG 85, GOG 120, and GOG 165), surgical staging with surgical exclusion of positive para-aortic lymph nodes is an option for patients with advanced cervical cancer.[114] Radiologic imaging is recommended for assessing stage IB–IVA tumors (see *Principles of Imaging* in the NCCN Guidelines for Cervical Cancer).

Fertility-Sparing

<u>Stage IB1</u>

For patients who desire fertility preservation, radical trachelectomy with SLN mapping and pelvic lymphadenectomy with (or without) para-aortic lymphadenectomy is an option for stage IB1 who do not meet the conservative surgery criteria, and select cases of IB2 disease, but typically only for tumors <2 cm since that has been most validated.[65,188-191,203] Stage IB2 tumors that are 2 to 4 cm must be carefully selected for a fertility-sparing approach as many of these patients may require postoperative adjuvant therapy due to pathologic risk factors (eg, Sedlis Criteria or positive nodes). However, some surgeons suggest that a 2-cm

Version 2.2026 © 2025 National Comprehensive Cancer Network® (NCCN®), All rights reserved. NCCN Guidelines®, and this illustration may not be reproduced in any form without the express written permission of NCCN.

cutoff may be used for vaginal trachelectomy, whereas a 4-cm cutoff may be used for abdominal trachelectomy.[204] In one study, oncologic outcomes were similar after 4 years when comparing radical trachelectomy with radical hysterectomy for patients with stage IB1 cervical carcinoma.[65] Stage IB1 or IB2 small cell neuroendocrine histology, gastric type adenocarcinoma, and adenoma malignum are not considered suitable for fertility-sparing surgery.

Non–Fertility-Sparing

Stage IB1, IB2, and IIA1

The recommended surgical option for stage IB1 (low-risk) with no evidence of LVSI and upon meeting conservative surgery criteria from CONCERV trial,[42] GOG-0278[60] and SHAPE trial[202] is Type A hysterectomy with SLN mapping or pelvic lymphadenectomy. For stage IB1 (not meeting conservative surgery criteria), IB2, and IIA1 disease, primary surgery consists of Type C1 radical hysterectomy with SLN mapping or bilateral pelvic lymphadenectomy (category 1), with (or without) para-aortic lymphadenectomy (category 2B for para-aortic lymphadenectomy).[205,206] A randomized Italian study compared RT alone versus radical hysterectomy and lymphadenectomy in patients with clinical early-stage disease (stage IB–IIA).[205] Adjuvant RT was given to those with parametrial extension, <3 cm of uninvolved cervical stroma, positive margins, or positive nodes. Identical outcomes were noted for patients treated with radiation versus surgery, with (or without) postoperative radiation, but higher complication rates were noted for the combined modality approach.

Panel members feel that surgery is the most appropriate option for patients with stage IB1, IB2, or IIA1 disease, whereas concurrent chemoradiation is the most appropriate option for those with stage IB3 or IIA2 disease based on randomized trials.[205,207-210] These trials have shown that the use of concurrent chemoradiation results in a 30% to 50% decrease in the risk of death compared with RT alone. Although the optimal concurrent chemotherapy regimen to use with RT requires further investigation, these trials clearly established a role for concurrent cisplatin-containing chemoradiation. Based on these data, the NCI issued an alert stating that strong consideration should be given to using chemoradiation instead of RT alone for invasive cervical cancer.[211] Long-term follow-up of three of these trials has confirmed that concurrent cisplatin-containing chemoradiation improves PFS and OS when compared with RT with (or without) hydroxyurea.[212-214] A recent meta-analysis reported that chemoradiotherapy leads to a 6% improvement in 5-year survival (HR, 0.81; $P < .001$).[215] A large, population-based registry analysis in Canada (n = 4069) confirmed that chemoradiotherapy improved outcomes when compared with RT alone.[216] Thus, the primary surgical option is a category 1 recommendation for patients with stage IB1, IB2, or IIA1 disease; however, primary chemoradiation is the category 1 recommendation for those with stage IB3 or IIA2 disease.[207,210] Para-aortic lymphadenectomy may be performed for patients with larger tumors and suspected or known pelvic nodal disease. Some Panel members feel that a pelvic lymphadenectomy should be performed first and if negative, then a radical hysterectomy should be performed. If the lymph nodes are positive, then hysterectomy should be abandoned; these patients should undergo chemoradiation. For patients with stage IBI (who do not meet conservative surgery criteria), IB2, or IIA tumors (including those who are not candidates for hysterectomy), another option is combined pelvic EBRT and brachytherapy with (or without) concurrent platinum-containing chemotherapy. Preferred radio sensitizing regimens include cisplatin or carboplatin for patients who are cisplatin-intolerant. Other recommended regimens include capecitabine and mitomycin, gemcitabine, and paclitaxel.[217-220] Although concurrent chemoradiation has been proven effective in the definitive treatment of more advanced-stage disease, this approach has not been specifically studied in patients with stage IB1, IB2, or IIA1 disease. Careful

Version 2.2026 © 2025 National Comprehensive Cancer Network® (NCCN®), All rights reserved. NCCN Guidelines®, and this illustration may not be reproduced in any form without the express written permission of NCCN.

PLEASE NOTE that use of this NCCN Content is governed by the End-User License Agreement, and you MAY NOT distribute this Content or use it with any artificial intelligence model or tool.
Printed by Galya Basol Kochav on 12/29/2025 12:47:39 PM. Copyright © 2025 National Comprehensive Cancer Network, Inc. All Rights Reserved.

consideration of the risk/benefit ratio should be undertaken in these patients with smaller tumors.

Stage IB3–IIA2

For patients with clinical stage IB3 or IIA2 tumors who are treated with definitive radiation, concurrent cisplatin-containing chemotherapy has been shown to significantly improve patient survival. The Panel recommends definitive EBRT with concurrent platinum-containing chemotherapy and brachytherapy (traditionally 75–80 Gy to total point A dose) (Category 1).[174,175,208-211,221] Type C1 radical hysterectomy with SLN mapping or pelvic lymphadenectomy with or without para-aortic lymphadenectomy is under category 2A. Addition of para-aortic lymphadenectomy is designated as a category 2B recommendation.
For stage IB3 or IIA2 tumors, the Panel had a major disagreement about recommending adjuvant hysterectomy (category 3) (also known as selective completion surgery) after primary chemoradiation since it is not supported by data.[207] Adjuvant hysterectomy after RT has been shown to improve pelvic control, but not overall survival, and is associated with increased morbidity.[222] A Cochrane review examined whether the addition of hysterectomy to standard nonsurgical treatments benefitted patients with locally advanced cervical cancer, finding insufficient data to demonstrate a survival benefit associated with surgery.[223] The morbidity is higher after completion surgery, but this may be reduced using a laparoscopic technique.[224-227] Although routine completion hysterectomy is not typically performed, this approach may be considered in patients whose extent of disease or uterine anatomy precludes adequate coverage by brachytherapy. This approach should only be considered in patients whose tumor shows a poor response with evidence of residual disease after chemoradiation + image-guided brachytherapy (IGBT) or in patients for whom IGBT is not feasible. Again, treatment should be modified based on normal tissue tolerance, fractionation, and size of target volume.

Advanced Disease

This category has traditionally included patients with stage IIB to IVA disease (ie, locally advanced disease). However, many oncologists now include patients with IB3 and IIA2 disease in the advanced disease category. For patients with more advanced tumors who are undergoing primary chemoradiation, the volume of RT is critical and guided by assessment of nodal involvement in the pelvic and para-aortic nodes. Radiologic imaging studies (neck/chest/abdomen/pelvis/groin FDG-PET/CT (preferred) or chest/abdomen/pelvis CT to evaluate for metastatic disease[228,229] are recommended for stage IB2 or greater disease, especially for evaluation of nodal or extra pelvic tumor (see *Principles of Imaging* in the NCCN Guidelines for Cervical Cancer). Pelvic MRI is preferred to describe local disease extent and assist in radiation treatment planning. However, needle biopsy of extrauterine abnormality can be considered for questionable imaging findings.

For patients with stage IIB–IVA disease, further radiologic workup for metastatic disease is recommended. After radiologic workup, if the patient is negative for distant metastasis or has a negative biopsy of suspicious area, EBRT with concurrent platinum containing chemotherapy and brachytherapy are recommended. Extended field RT is recommended when para-aortic nodes are involved by imaging or confirmed on pathology. This may also be added to select patients with positive pelvic nodes such as common iliac metastasis.

Pembrolizumab may be added with chemoradiotherapy for patients with FIGO 2014 stage III–IVA cervical cancer based on KEYNOTE A18 trial (See *Systemic therapy* section). Patients who are positive for distant metastases after biopsy are treated with systemic chemotherapy with (or without) individualized EBRT.[201]

Version 2.2026 © 2025 National Comprehensive Cancer Network® (NCCN®), All rights reserved. NCCN Guidelines®, and this illustration may not be reproduced in any form without the express written permission of NCCN.

PLEASE NOTE that use of this NCCN Content is governed by the End-User License Agreement, and you MAY NOT distribute this Content or use it with any artificial intelligence model or tool.
Printed by Galya Basol Kochav on 12/29/2025 12:47:39 PM. Copyright © 2025 National Comprehensive Cancer Network, Inc. All Rights Reserved.

Based on INTERLACE trial,[230] the Panel also included induction chemotherapy followed by chemoradiation as a footnote for patients with stage IIB–IVA disease and this is reflected in the systemic therapy recommendations for cervical cancer.

Metastatic Disease

For patients who present with distant metastatic disease (ie, stage IVB), primary treatment is often platinum-containing chemotherapy (see *Therapy for Metastatic Disease* below). In these situations, individualized EBRT may be considered for control of pelvic disease and other symptoms.[201]

Surveillance

The Panel agrees with the new Society of Gynecologic Oncology's (SGOs) recommendations for post-treatment surveillance.[231] The recommended surveillance is based on the patient's risk for recurrence and personal preferences. History and physical examinations are recommended every 3 to 6 months for 2 years, every 6 to 12 months for another 3 to 5 years, and then annually. Patients with high-risk disease can be assessed more frequently (eg, every 3 months for the first 2 years) than patients with low-risk disease (eg, every 6 months).

Annual cervical/vaginal cytology tests can be considered as indicated for detection of lower genital tract dysplasia (eg, for those who have had fertility-sparing surgery). Some clinicians have suggested that rigorous cytology follow-up is not warranted because of studies stating that Pap tests did not detect recurrences in patients with stage I or II cervical cancer who were asymptomatic after treatment.[231-233] Noting the inherent differences between these patients and the general screening population, the Panel does not recommend workup of low-grade squamous dysplasia detected during surveillance, but suggests that patients should follow up with a provider with specific expertise in this area. It is important to emphasize good clinical evaluation and a high index of suspicion, because the detection rate of recurrent cervical cancer is low using cervical and vaginal cytology alone.[234]

For patients with stage I disease, follow-up imaging should be based on symptomatology and clinical concern for recurrent/metastatic disease, such as abnormal physical exam finding or new pelvic, abdominal, or pulmonary symptoms. If fertility-sparing treatment was provided, pelvic MRI should be considered 6 months after surgery and yearly for 2 to 3 years. Neck/chest/abdomen/pelvis/groin FDG-PET/CT can be considered if metastasis is suspected.[235,236] For patients with stage II disease or greater, neck/chest/abdomen/pelvis/groin FDG-PET/CT (preferred) or chest/abdomen/pelvis CT with contrast should be performed within 3 to 6 months of completing therapy; pelvic MRI is optional. Additional imaging should be guided by symptomatology and clinical concern for recurrent/metastatic disease. Specific indications and recommendations for surveillance imaging are detailed in *Principles of Imaging* in the NCCN Guidelines for Cervical Cancer.[229,231,235,237-243]

Many other tests remain optional based on clinical indications, such as semiannual CBCs, blood urea nitrogen (BUN), and serum creatinine determinations. Patients with persistent or recurrent disease need to be evaluated using additional imaging studies as clinically indicated, biopsy with or without examination under anesthesia (EUA) and surgical exploration in selected cases followed by therapy for relapse (see *Therapy for Relapse* section).[244] Comprehensive molecular profiling as determined by FDA-approved assay or a validated test performed in CLIA certified laboratory can be considered for better selection of systemic therapy. If tissue biopsy of metastatic site is not feasible or tissue is not available, comprehensive genomic profiling via a validated plasma circulating tumor DNA (ctDNA) assay can be considered.

Version 2.2026 © 2025 National Comprehensive Cancer Network® (NCCN®), All rights reserved. NCCN Guidelines®, and this illustration may not be reproduced in any form without the express written permission of NCCN.

PLEASE NOTE that use of this NCCN Content is governed by the End-User License Agreement, and you MAY NOT distribute this Content or use it with any artificial intelligence model or tool.
Printed by Galya Basol Kochav on 12/29/2025 12:47:39 PM. Copyright © 2025 National Comprehensive Cancer Network, Inc. All Rights Reserved.

Education of patients regarding symptoms suggestive of recurrence is recommended (eg, vaginal discharge; weight loss; anorexia; pain in the pelvis, hips, back, or legs; persistent coughing). Patients should also be counseled on healthy lifestyle, obesity, nutrition, exercise, sexual health, hormone replacement therapy, and potential long-term and late effects of treatment. Smoking cessation and abstinence should be encouraged.[231] See the NCCN Guidelines for Survivorship, and NCCN Guidelines for Smoking Cessation, both available at www.NCCN.org, and https://www.cancer.org/cancer/survivorship).

Patients who have received RT for cervical cancer may experience vaginal stenosis and dryness and should receive education on important issues regarding sexual health and vaginal health. Providers should inform patients about regular vaginal intercourse and/or vaginal dilator use and on the use of vaginal moisturizers/lubricants (eg, estrogen creams). Anecdotal evidence suggests that vaginal dilators may be used to prevent or treat vaginal stenosis.[245] Dilator use can start 2 to 4 weeks after RT is completed and can be performed indefinitely.

Cervical cancer survivors are at risk for second cancers.[246] Data suggest that patients who undergo RT for pelvic cancers are at risk for radiation-induced second cancers, especially at radiated sites near the cervix (eg, colon, rectum/anus, urinary bladder); therefore, careful surveillance is appropriate for these patients.[247,248]

Therapy for Relapse

Recurrences should be proven by biopsy before proceeding to treatment planning for recurrent disease.

Locoregional Recurrence

Patients with a localized recurrence of cervical cancer after initial treatment may be candidates for radical retreatment; options include: 1) RT and/or chemotherapy; or 2) surgery.[174,249] After treatment for relapse, long-term, disease-free survival rates of approximately 40% have been reported in some situations.[250]

For patients who experience locoregional recurrences who have not undergone previous RT or who experience recurrences outside of the previously treated RT field, therapy for relapse includes tumor-directed EBRT and concurrent platinum containing chemotherapy and/or brachytherapy; surgical resection can be considered if feasible. Typically, the chemoradiation for recurrence uses cisplatin as a single agent or carboplatin (if cisplatin intolerant).[251,252] However, in those patients who have relapsed soon after completing initial chemoradiation with these regimens, other systemic therapy options might be considered or best supportive care could be offered (see NCCN Guidelines for Palliative Care, available at www.NCCN.org).

Patients with central pelvic recurrent disease after RT should be evaluated for pelvic exenteration, with (or without) intraoperative RT (IORT.[253-260] Surgical mortality is generally ≤5%, with survival rates approaching 50% in carefully selected patients.[256] Concomitant measures with these radical procedures include adequate rehabilitation programs dealing with the psychosocial and psychosexual consequences of the surgery as well as reconstructive procedures.[255,261-263] Although exenteration is the common surgical approach in patients who have previously received radiation with isolated central pelvic relapse, radical hysterectomy or brachytherapy or individualized EBRT with or without concurrent platinum containing chemotherapy with cisplatin or carboplatin if cisplatin intolerant may be an option in carefully selected patients with small central lesions (<2 cm).

For patients with noncentral recurrent disease, options include EBRT with (or without) concurrent platinum containing chemotherapy, resection with (or without) IORT,[209] or systemic therapy or best supportive care (see the

Version 2.2026 © 2025 National Comprehensive Cancer Network® (NCCN®), All rights reserved. NCCN Guidelines®, and this illustration may not be reproduced in any form without the express written permission of NCCN.

PLEASE NOTE that use of this NCCN Content is governed by the End-User License Agreement, and you MAY NOT distribute this Content or use it with any artificial intelligence model or tool.
Printed by Galya Basol Kochav on 12/29/2025 12:47:39 PM. Copyright © 2025 National Comprehensive Cancer Network, Inc. All Rights Reserved.

NCCN Guidelines for Palliative Care, available at www.NCCN.org), or participation in a clinical trial.

Patients who experience recurrence after second-line definitive therapy, either surgery or RT, have a poor prognosis. They can be treated with systemic therapy or best supportive care or can be enrolled in a clinical trial.

Therapy for Metastatic Disease

Patients who develop distant metastases, either at initial presentation or at relapse, are rarely curable. Comprehensive molecular profiling as determined by FDA-approved assay, or a validated test performed in CLIA certified laboratory can be considered for better selection of systemic therapy. If tissue biopsy of metastatic site is not feasible or tissue is not available, comprehensive genomic profiling via a validated plasma ctDNA assay can be considered to guide appropriate biomarker directed second line therapy. For highly selected patients with isolated distant metastases amendable to local treatment,[264] occasional long-term survival has been reported with: 1) surgical resection with (or without) EBRT; 2) local ablative therapies with (or without) EBRT; or 3) EBRT with (or without) chemotherapy. Systemic adjuvant chemotherapy can be considered. For example, patients who may benefit from aggressive local therapy for oligometastatic disease include those with nodal, lung, liver, or bone metastases.[265,266] Following local therapy, additional adjuvant chemotherapy can be considered. For most other patients with distant metastases, an appropriate approach is a clinical trial, chemotherapy, or best supportive care (see NCCN Guidelines for Palliative Care, available at www.NCCN.org).

The palliation of pelvic recurrences in heavily irradiated sites that are not amenable to local pain control techniques or to surgical resection is difficult.[267] These sites are generally not responsive to chemotherapy. Adequately palliating the complications of pain and fistulae from these recurrences is clinically challenging (http://emedicine.medscape.com/article/270646-overview). However, short courses of RT may provide symptomatic relief to patients with bone metastases, painful para-aortic nodes, or supraclavicular adenopathy.[201,268,269]

Chemotherapy is often recommended for patients with extra pelvic metastases or recurrent disease who are not candidates for RT or exenterative surgery. Patients whose disease responds to chemotherapy may have relief from pain and other symptoms. If cisplatin was previously used as a radiosensitizer, combination platinum-based regimens are preferred over single agents in the metastatic disease setting based on several randomized phase III trials.[270,271] However, responses to chemotherapy are often of short duration and survival is rarely increased.

Incidental Cervical Cancer

Invasive cervical carcinoma is sometimes found incidentally after simple/total hysterectomy. Workup for these patients include history and physical examination, CBC (including platelets), and liver and renal function tests. Recommended radiologic imaging includes chest radiography, CT, or combined PET/CT; MRI may be performed if indicated to rule out gross residual disease. However, imaging is optional for patients with stage IB1 or smaller tumors.

No definitive data is available to guide the appropriate adjuvant treatment of these patients. Surveillance is recommended for patients with stage IA1 cervical cancer who do not have LVSI.

For patients with either stage IAI with LVSI, or positive margins/gross residual disease, the Panel believes that a reasonable treatment schema should be based on the status of the surgical margins. For stage IA1 with LVSI and negative margins,[60] and stage 1A2–IB1 cancer and all

Version 2.2026 © 2025 National Comprehensive Cancer Network® (NCCN®), All rights reserved. NCCN Guidelines®, and this illustration may not be reproduced in any form without the express written permission of NCCN.

PLEASE NOTE that use of this NCCN Content is governed by the End-User License Agreement, and you MAY NOT distribute this Content or use it with any artificial intelligence model or tool.
Printed by Galya Basol Kochav on 12/29/2025 12:47:39 PM. Copyright © 2025 National Comprehensive Cancer Network, Inc. All Rights Reserved.

conservative surgery inclusion criteria met,[42] a second surgery with pelvic lymphadenectomy is a preferred strategy. Based on the nodal status, adjuvant therapy can be determined after imaging workup. If margins are positive or positive pelvic nodes, parametrium, or para-aortic lymph nodes and imaging is negative for nodal disease, then pelvic EBRT with concurrent platinum-containing chemotherapy with (or without) individualized brachytherapy is recommended. Recommended radiosensitizing regimens include cisplatin (preferred), carboplatin (preferred if patient is cisplatin-intolerant), or cisplatin/fluorouracil. If imaging is positive for metastasis, systemic therapy with individualized EBRT is recommended. When specimen integrity is not known, pelvic EBRT is recommended. Brachytherapy and concurrent platinum-containing chemotherapy can be added to this modality.

If margins or imaging is negative in stage IB1 (not meeting conservative surgery criteria), stage IB2 or greater tumors or GOG/Sedlis Criteria are not met on the hysterectomy specimen, options include: 1) pelvic RT with brachytherapy, with (or without) concurrent platinum-containing chemotherapy; or 2) consideration of complete parametrectomy, upper vaginectomy, and pelvic lymphadenectomy with (or without) para-aortic lymph node sampling (category 2B for para-aortic lymph node sampling). Typically, observation is recommended for patients with negative lymph nodes and no residual disease. However, chemoradiation with vaginal brachytherapy is recommended for subsequent findings of positive nodes, surgical margins, and/or parametrium.

For hysterectomy specimens with positive margins, gross residual disease, negative imaging, or primary tumor characteristics meeting Sedlis Criteria, pelvic EBRT with concurrent platinum-containing chemotherapy (with individualized brachytherapy for positive vaginal margins) is recommended.[141]

Systemic Therapy Recommendations

Chemoradiation for Locally Advanced Cervical Cancer

Concurrent chemoradiation, using platinum containing chemotherapy (cisplatin alone), is the treatment of choice for stages IB3, II, III, and IVA disease based on the results of randomized clinical trials. These trials have shown that the use of concurrent chemoradiation results in a 30% to 50% decrease in the risk of death compared with RT alone. Long-term follow-up of three trials have confirmed that concurrent cisplatin containing chemoradiation improves PFS and OS when compared with RT with (or without) hydroxyurea.[212-214] Cisplatin remains as the preferred radiosensitizing agent in the primary treatment for patients with locally advanced cervical cancer when used concomitantly with EBRT and carboplatin as a preferred radiosensitizing agent for patients who are cisplatin intolerant.[272] When cisplatin and carboplatin are unavailable, the other recommended options are capecitabine/mitomycin IV, gemcitabine, and paclitaxel as radiosensitizers based on a few early-phase studies that have shown their efficacy and tolerability when administered concomitantly with radiation.[217-219]

A phase 3, randomized trial, enrolling 926 patients with locally advanced cervical cancer of stage IIB–IVA, evaluated the efficacy of RT plus concurrent chemotherapy consisting of oral 5-fluorouracil/mitomycin as compared to RT only, RT plus adjuvant chemotherapy (5-fluorouracil) or RT plus concurrent chemoradiotherapy plus adjuvant chemotherapy.[217] Although acute side effects were more prevalent in the concurrent arms and the OS was not significant between the arms, the RT plus concurrent chemotherapy arm showed the least locoregional recurrence and the highest 5-year DFS when compared with the other arms. In particular, the difference in DFS and OS rate was highly significant when comparing the concurrent chemoradiation arm with the RT only arm ($P = .0001$). Several studies have shown that although 5-fluorouracil/mitomycin combined with RT was effective, the combination is also associated with relatively higher

Version 2.2026 © 2025 National Comprehensive Cancer Network® (NCCN®), All rights reserved. NCCN Guidelines®, and this illustration may not be reproduced in any form without the express written permission of NCCN.

PLEASE NOTE that use of this NCCN Content is governed by the End-User License Agreement, and you MAY NOT distribute this Content or use it with any artificial intelligence model or tool.
Printed by Galya Basol Kochav on 12/29/2025 12:47:39 PM. Copyright © 2025 National Comprehensive Cancer Network, Inc. All Rights Reserved.

toxicity rates and should be used with caution.[273,274] The efficacy and safety of gemcitabine combined with pelvic radiation was tested in 19 patients with chemo-naïve, advanced stage IIIB cervical cancer and showed a CR of 89.5% and partial response (PR) of 5.3% for an ORR of 94.7%. The OS at median follow-up time of 19.9 months was 100% with DFS of 84.2%. Due to gemcitabine's high potency as a radiosensitizer, it requires reduced dosing when used concurrently with radiation to avoid radiation toxicity.[218] In a comparative study, the disease control and toxicity profile were found to be similar between cisplatin and gemcitabine.[275] The benefit of paclitaxel alone as a radiosensitizer has not been extensively studied in the literature and there are only a few known preclinical or early-phase studies of its efficacy. In a pilot study to evaluate paclitaxel with RT, CR was achieved by 8 out of 13 patients with locally advanced cervical cancer and by 4 out of 6 patients treated with a recurrent disease.[220] Although chemoradiation is tolerated, acute and long-term side effects have been reported.[215,276,277] Due to significant toxicity concerns associated with these agents, cisplatin or carboplatin is a preferred agent over other non-platinum chemoradiation regimens.

Preferred regimens

A multicenter, randomized, double-blind, placebo-controlled trial KEYNOTE-A18 (NCT04221945) evaluated the efficacy of concurrent platinum-containing chemotherapy (CCRT) with EBRT utilizing cisplatin as a single agent with pembrolizumab in 1060 eligible patients with newly diagnosed, previously untreated, high-risk locally advanced cervical cancer (FIGO 2014 stage IB2–IIB with node-positive disease or stage III–IVA). Pembrolizumab + CCRT showed a statistically significant and clinically meaningful improvement in PFS and a favorable trend in OS compared with placebo + CCRT in patients with high-risk locally advanced cervical cancer.[278] In an exploratory subgroup analysis in the 596 patients with FIGO 2014 stage III–IVA disease, the PFS HR estimate was 0.59 (95% CI, 0.43–0.82), and 21% of patients in the pembrolizumab arm experienced a PFS event compared to 31% of patients in the placebo arm. In contrast, in an exploratory subgroup analysis in the 462 patients with FIGO 2014 stage IB2–IIB disease, the PFS HR estimate was 0.91 (95% CI, 0.63–1.31), indicating that the PFS improvement in the overall population was primarily attributed to patients with FIGO 2014 stage III–IVA disease. Based on this data, the Panel recommends the addition of pembrolizumab to radiation therapy (EBRT+brachytherapy) and concurrent platinum containing chemotherapy for patients with FIGO 2014 stage III–IVA as category 1 option. Since FIGO 2018 staging has separate designations for pelvic lymph node metastasis,[279] irrespective of tumor size and extent as stage IIIC disease, stage IIIC1 for pelvic lymph node metastasis only or stage IIIC2 for para-aortic lymph node metastasis, the Panel achieved <85% consensus in recommending this combination regimen to select patients with FIGO 2018 stage III–IVA disease such as FIGO 2018 stage IIIC purely on nodal metastasis without concomitant tumor characteristics defined in 2014 FIGO Stage IIIA–IIIB (Category 2B). The Panel clarified that if the FIGO 2018 staging of stage III overlaps with FIGO 2014 IIIA/IIIB staging, category 1 can be applied to pembrolizumab with chemoradiation.

Although chemoradiation is tolerated, acute and long-term side effects have been reported.[215,276,277] Concurrent single-agent cisplatin chemoradiation may be preferred over cisplatin/fluorouracil chemoradiation due to lesser toxicity.[175,280] Concurrent carboplatin (preferred if cisplatin intolerant) or non-platinum chemoradiation regimens are options for patients who may not tolerate cisplatin-containing chemoradiation.[215,217,281-285] Carboplatin has been added to the Guidelines as a preferred radiosensitizing agent for patients who are cisplatin intolerant.

The NCCN Panel has noted for all chemoradiation agents that the cost and toxicity profiles of these radiosensitizing agents should be considered

Version 2.2026 © 2025 National Comprehensive Cancer Network® (NCCN®), All rights reserved. NCCN Guidelines®, and this illustration may not be reproduced in any form without the express written permission of NCCN.

PLEASE NOTE that use of this NCCN Content is governed by the End-User License Agreement, and you MAY NOT distribute this Content or use it with any artificial intelligence model or tool.
Printed by Galya Basol Kochav on 12/29/2025 12:47:39 PM. Copyright © 2025 National Comprehensive Cancer Network, Inc. All Rights Reserved.

when selecting an appropriate regimen for treatment and have strongly expressed that this is especially critical when these regimens are being used for extended field radiation therapy where toxicities may be more severe.

Other Recommended Regimens

INTERLACE trial investigated chemoradiotherapy with or without induction chemotherapy to determine whether induction chemotherapy improves both progression-free survival and overall survival.[230] In this multicenter, randomized phase 3 trial, 500 eligible patients with LACC (FIGO 2008 stage IB1 disease with nodal involvement, or stage IB2, IIA, IIB, IIIB, or IVA disease) were randomly assigned (1:1) chemoradiotherapy alone group (n = 250) or the induction chemotherapy with chemoradiotherapy group. After a median follow-up of 67 months, 5-year progression-free survival rates were 72% in the induction chemotherapy with chemoradiotherapy group and 64% in the chemoradiotherapy alone group (HR = 0.65; 95% CI, 0.46–0.91; *P* = .013). 5-year OS rates were 80% in the induction chemotherapy with chemoradiotherapy group and 72% in the chemoradiotherapy alone group (HR = 0.60; 95% CI, 0.40–0.91; *P* = .015). Grade 3 or greater adverse events were reported in 147 (59%) of 250 individuals in the induction chemotherapy with chemoradiotherapy group versus 120 (48%) of 250 individuals in the chemoradiotherapy alone group. This trial demonstrates that short-course induction chemotherapy followed by chemoradiotherapy significantly improves survival of patients with locally advanced cervical cancer. The study also notes that induction chemotherapy could benefit global cervical cancer patients with two affordable, effective, and readily available drugs given before chemoradiotherapy.[230] The Panel included this recommendation as a footnote for patients with stage IIB–IVA disease and this is reflected in the systemic therapy recommendations for cervical cancer.

Systemic Therapy for Recurrent or Metastatic Cervical Cancer

The estimated 5-year survival rate for patients with early-stage cervical cancer is >90% whereas the curative options for advanced stage disease are limited.[286] Systemic therapy with or without radiation forms the basis of treatment of patients with recurrent or metastatic disease.

First-Line Systemic Therapy Options for Recurrent or Metastatic Disease

Preferred Regimens

Pembrolizumab Plus Chemotherapy with or without Bevacizumab

Presently, the Guidelines include two immunotherapy-based regimens as preferred, first-line therapy options for the treatment of PD-L1–positive recurrent or metastatic cervical cancer. Pembrolizumab combined with chemotherapy with or without bevacizumab regimens is the preferred, category 1 treatment option based on the results of the Keynote-826 study.[149] In the primary analysis of the phase 3, Keynote-826 trial, which enrolled 617 patients (548 with PD-L1–positive CPS ≥1 tumors; 317 patients with CPS ≥10) with previously untreated persistent, recurrent, or metastatic cervical cancer, the addition of pembrolizumab to chemotherapy with or without bevacizumab improved PFS and overall survival versus the placebo group (PFS, 10.4 vs. 8.2 months, respectively; HR, 0.65; 95% CI, 0.53–0.79; *P* < .001, and OS at 24 months: 50.4% vs. 40.4%, respectively; HR, 0.67; 95% CI, 0.54–0.84; *P* < .001). The ORR was significantly higher in the pembrolizumab arm as compared to the placebo group in the patients with PD-L1–positive (CPS ≥1) tumors (68.1% vs. 50.2%). The FDA approved pembrolizumab plus chemotherapy, with or without bevacizumab for patients with persistent, recurrent, or metastatic cervical cancer whose tumors express PD-L1 (CPS ≥1). In the final, updated analysis of the trial results, the addition of pembrolizumab to chemotherapy with or without bevacizumab continued to show significant survival benefits in the PD-L1–positive (CPS ≥1)

Version 2.2026 © 2025 National Comprehensive Cancer Network® (NCCN®), All rights reserved. NCCN Guidelines®, and this illustration may not be reproduced in any form without the express written permission of NCCN.

PLEASE NOTE that use of this NCCN Content is governed by the End-User License Agreement, and you MAY NOT distribute this Content or use it with any artificial intelligence model or tool.
Printed by Galya Basol Kochav on 12/29/2025 12:47:39 PM. Copyright © 2025 National Comprehensive Cancer Network, Inc. All Rights Reserved.

tumors at a median follow-up of 39.1 months with median OS and PFS of 28.6 and 10.5 months versus 16.5 and 8.2 months in the pembrolizumab plus chemotherapy arm versus the placebo plus chemotherapy arm, respectively (HR, 0.60; 95% CI, 0.49–0.74; $P < .0001$).[287] The NCCN Panel continues to recommend pembrolizumab plus chemotherapy with or without bevacizumab in patients whose tumors express PD-L1 (CPS ≥1) as determined by an FDA-approved assay, or a validated test performed in a CLIA-certified laboratory.

Chemotherapy with Bevacizumab

The platinum-based chemotherapy (cisplatin or carboplatin)/paclitaxel with bevacizumab have been extensively investigated in clinical studies and is among the preferred, first-line treatment option for patients with recurrent/metastatic cervical cancer in the NCCN Guidelines (based on GOG 240 trial). The cisplatin/paclitaxel/bevacizumab regimen is category 1 in this disease setting.[288]

A randomized phase III trial (GOG 240) studied the addition of bevacizumab to combination chemotherapy regimens (cisplatin/paclitaxel/bevacizumab or topotecan/paclitaxel/bevacizumab) in 452 patients in the first-line setting of metastatic, persistent, or recurrent cervical cancer. Analysis of pooled data from the two chemotherapy regimens revealed significant improvements in overall survival among patients receiving bevacizumab (16.8 vs. 13.3 months; $P = .007$).[289] While bevacizumab led to higher toxicity (eg, hypertension, thromboembolic events, gastrointestinal fistula), it was not associated with a statistically significant decrease in patient-reported quality of life ($P = .27$).[290] A 2017 systemic review and meta-analysis of data from 19 trials of systemic therapy for patients with recurrent, persistent, or metastatic cervical cancer found a trend towards improved OS for the addition of bevacizumab to cisplatin/paclitaxel or topotecan/paclitaxel when compared with all other non-bevacizumab–containing chemotherapy regimens.[291] Based on the collective findings from GOG 240[289] and JGOG0505[292] (described below), the Panel has opted to include carboplatin/paclitaxel/bevacizumab as an additional preferred regimen for recurrent or metastatic cervical cancer (category 2A).

Atezolizumab Plus Chemotherapy with Bevacizumab

Addition of Atezolizumab to bevacizumab plus chemotherapy combination from GOG240 trial was added to preferred regimens as Category 1 based on the results from BEATcc trial.[293] In this open-label, phase 3 trial, 410 of 519 patients with measurable, previously untreated metastatic, persistent, or recurrent cervical cancer and not amenable to curative surgery or radiation were randomly assigned 1:1 to receive standard therapy of cisplatin/carboplatin and paclitaxel with bevacizumab with or without Atezolizumab. Median progression-free survival was 13.7 months (95% CI, 12.3–16.6) with atezolizumab and 10·4 months (95% CI, 9.7–11.7) with standard therapy (HR = 0.62; 95% CI, 0.49–0.78; $P < .0001$). At the interim overall survival analysis, median overall survival was 32.1 months (95% CI, 25.3–36.8) versus 22.8 months (95% CI, 20.3–28.0), respectively (HR = 0.68; 95% CI, 0.52–0.88; $P = .0046$). The post hoc analysis presented at ESMO Gynecology 2025 demonstrated that survival benefits with the addition of atezolizumab were observed across all PD-L1 subgroups indicating that PD-L1 expression did not significantly alter the efficacy of the treatment combination.[294]

Other Recommended Regimens

Cisplatin is generally regarded as the most active agent and is recommended as the preferred first-line single-agent chemotherapy option for recurrent or metastatic cervical cancer; reported response rates are approximately 20% to 30%, with an occasional complete response.[270,295-297] Overall survival with cisplatin is approximately 6 to 9 months. Both carboplatin and paclitaxel have each been reported to be tolerable and efficacious and are also possible first-line single-agent chemotherapy

Version 2.2026 © 2025 National Comprehensive Cancer Network® (NCCN®), All rights reserved. NCCN Guidelines®, and this illustration may not be reproduced in any form without the express written permission of NCCN.

options.[298-302] Therefore, palliation with single agents—cisplatin, carboplatin, or paclitaxel—is a reasonable approach in patients with recurrent disease not amenable to surgical or radiotherapeutic approaches. However, most patients who develop metastatic disease have received concurrent cisplatin/RT as primary treatment and may no longer be sensitive to single-agent platinum therapy.[270,271]

The Panel recommends single agent cisplatin and carboplatin as other recommended regimens. In previous versions of the Guidelines, cisplatin was placed under "preferred, first-line single-agent" category. However, based on the Panel's clinical judgement, as more effective treatment options are increasingly being available in the first-line setting, platinum-based single-agent chemotherapy has been reserved as alternate options under other recommended regimens in the Guidelines.

The published data from a phase III randomized trial (JCOG0505) suggested that carboplatin/paclitaxel was noninferior to cisplatin/paclitaxel in 253 patients with metastatic or recurrent cervical cancer.[292] Many physicians use carboplatin/paclitaxel because of ease of administration and tolerability.[303] Results from JCOG0505 showed that the carboplatin/paclitaxel (TC) regimen was noninferior to cisplatin/paclitaxel (TP) in terms of median overall survival (18.3 months for TP vs. 17.5 months for TC; HR = 0.994 [90% CI, 0.79–1.25]; P = .032) and non-hospitalization periods were significantly longer for patients receiving TC.[292] However, among patients who had not received prior cisplatin, OS for TC and TP was 13.0 and 23.2 months, respectively (HR = 1.571; 95% CI, 1.06–2.32).[292] Based on these data, the Panel recommends carboplatin/paclitaxel as a preferred category 1 option for patients who have received prior cisplatin therapy (category 2A for other indications). A systematic review of the data on cisplatin/paclitaxel and carboplatin/paclitaxel regimens also suggested that lower toxicity carboplatin-based regimens appear to be an equally effective alternative to cisplatin-containing regimens for treating recurrent or metastatic cervical cancer.[304]

The Panel has continued to recommend other platinum-containing combination regimens, such as cisplatin/paclitaxel (category 1), carboplatin/paclitaxel (category 1), topotecan/paclitaxel/bevacizumab (category 1), topotecan/paclitaxel, and cisplatin/topotecan as appropriate alternate options under the other recommended regimens category.[270,271,289,305-307] A randomized phase III study (GOG 169) in 264 patients compared cisplatin/paclitaxel versus cisplatin alone for metastatic, recurrent, or persistent cervical cancer. Patients receiving the 2-drug combination had a higher response rate (36% vs. 19%) and improved PFS (4.8 vs. 2.8 months; P > .001) compared to single-agent cisplatin, although no improvement was seen in median survival.[270] Patients who responded to cisplatin/paclitaxel had a significant improvement in quality of life. Another randomized phase III study (GOG 179) in 294 patients investigated cisplatin/topotecan versus cisplatin alone for recurrent or persistent cervical cancer. The topotecan combination regimen was shown to be superior to single-agent cisplatin with respect to overall response rate (27% vs. 13%, P = .004), PFS (4.6 vs. 2.9 months; P = .014), and median survival (9.4 vs. 6.5 months; P =.017).[271] The FDA has approved cisplatin/topotecan for advanced cervical cancer. However, the cisplatin/paclitaxel or carboplatin/paclitaxel regimens are less toxic and easier to administer than cisplatin/topotecan.[308]

A phase III trial (GOG 204) compared 4 cisplatin-doublet regimens (cisplatin/paclitaxel, cisplatin/topotecan, cisplatin/gemcitabine, and cisplatin/vinorelbine) in 513 patients with advanced metastatic or recurrent cancer.[307] The trial was closed early based on futility analysis, because it was apparent that the cisplatin/topotecan, cisplatin/gemcitabine, and cisplatin/vinorelbine regimens were not superior to the control arm of cisplatin/paclitaxel. No significant differences in overall survival were seen;

Version 2.2026 © 2025 National Comprehensive Cancer Network® (NCCN®), All rights reserved. NCCN Guidelines®, and this illustration may not be reproduced in any form without the express written permission of NCCN.

however, the trends for response rate, PFS, and overall survival (12.9 vs. 10 months) suggest that cisplatin/paclitaxel is superior to the other regimens. Cisplatin/paclitaxel was associated with less thrombocytopenia and anemia (but with more nausea, vomiting, infection, and alopecia) than the other regimens. While topotecan/paclitaxel was not shown to be superior to cisplatin/paclitaxel, it may be considered as an alternative in patients who are not candidates for cisplatin.[289]

Based on previous studies, cisplatin/paclitaxel (category 1) and carboplatin/paclitaxel have become the most widely used systemic regimens for metastatic or recurrent cervical cancer. However, for patients who may not be candidates for taxanes, cisplatin/topotecan remains a reasonable alternative regimen.[271] In 2019, the Panel voted to remove cisplatin/gemcitabine as a first-line combination therapy option. Non-platinum regimens are also being studied and may be considered in patients who cannot tolerate platinum-based chemotherapy.[309]

Second-line/Subsequent Systemic Therapy Options for Recurrent or Metastatic Cervical Cancer

The treatment options for patients with disease progression after first-line therapies have mostly been of limited effect with low response rates to second-line and beyond chemotherapies and median PFS of around 3 to 6 months.[310,311]

Immunotherapy as Preferred, Second-line/Subsequent Therapy

Increasingly available data from several prospective studies have demonstrated the effectiveness of immunotherapies or specific biomarker-based therapies in the setting of disease progression and has significantly transformed the management of cervical cancer. In addition, many biomarker-specific therapies have demonstrated meaningful clinical efficacy and durability regardless of the underlying tumor type leading to an increase in tumor-agnostic regulatory approvals.

Pembrolizumab

Pembrolizumab is an FDA-approved therapy for patients with recurrent or metastatic cervical cancer with disease progression on or after chemotherapy for PD-L1–positive tumors (CPS ≥1). It is also approved for unresectable or metastatic MSI-H/dMMR or TMB-H solid tumors that have progressed following prior treatment and who have no satisfactory alternative treatment options. In the NCCN Guidelines, pembrolizumab monotherapy is the preferred, second-line therapy option for recurrent/metastatic MSI-H/dMMR or TMB-H or PD-L1–positive tumors based on the results from Keynote-028 (phase 1b) and Keynote-158 (phase 2) trials.[156,312,313]

Tisotumab vedotin-tftv

Tisotumab vedotin-tftv is an antibody-drug conjugate directed against tissue factor and monomethyl auristatin E, a potent inhibitor of cell division. The tissue factor is aberrantly expressed across multiple solid tumors and is associated with poor clinical outcomes and an increase in metastatic potential. Studies have indicated that tissue factor is highly prevalent in cervical cancer and might have a role in disease progression and poor patient outcome in the clinic.[314] The phase 1/2, InnovaTV-201 trial enrolled 147 patients with pretreated advanced or metastatic solid tumors, including 34 patients with advanced cervical cancer, in the dose expansion phase of the study to evaluate the safety and durability of tisotumab vedotin-tftv.[315] The ORR was 15.6% (95% CI, 10.2–22.5) with median DOR 5.7 months (95% CI, 3.0–9.5) and the median PFS was 3 months (95% CI, 2.8–4.1). Among the patients with cervical cancer, the ORR was achieved by 9 out of 34 patients (26.5%, 95% CI, 12.9–44.4). The study protocol was further amended to include additional patients in the cervical cancer expansion cohort. Among a total of 55 patients enrolled in the cervical cancer cohort, confirmed ORR was achieved in 22% (95% CI, 12–35) with median DOR 6.0 months (95% CI, 1–9.7) and median PFS of 4.1 months (1.7–6.7).[316]

Version 2.2026 © 2025 National Comprehensive Cancer Network® (NCCN®), All rights reserved. NCCN Guidelines®, and this illustration may not be reproduced in any form without the express written permission of NCCN.

PLEASE NOTE that use of this NCCN Content is governed by the End-User License Agreement, and you MAY NOT distribute this Content or use it with any artificial intelligence model or tool.
Printed by Galya Basol Kochav on 12/29/2025 12:47:39 PM. Copyright © 2025 National Comprehensive Cancer Network, Inc. All Rights Reserved.

This study was followed by the InnovaTV-204 trial, a phase 2 single-arm study that evaluated the efficacy of tisotumab vedotin-tftv in 102 patients with recurrent or metastatic cervical cancer who had progressed on previous systemic therapy.[317] At the median follow-up of 10 months, the confirmed ORR was 24% (95% CI, 16–33), which included 7% CR and 17% PR, and the median DOR was 8.3 months (95% CI, 4.2 – NR). Following the results from innovaTV-201 and innovaTV-204 trials that showed clinically meaningful and durable activity of tisotumab vedotin-tftv against pretreated recurrent/metastatic cervical cancer, the FDA granted accelerated approval for or adult patients with recurrent or metastatic cervical cancer with disease progression on or after chemotherapy.[318]

In phase 3, randomized, InnovaTV-301 /ENGOT-cx12/GOG-3057 trial,[319] among the 502 patients that were randomized (TV: 253; chemotherapy: 249); The TV arm had a 30% reduction in risk of death vs chemotherapy (HR, 0.70; 95% CI, 0.54–0.89; *P* = .004), The results showed that at a median follow-up of 10.8 months (95% CI, 10.3–11.6), with significantly longer median OS (11.5 months [95% CI, 9.8–14.9] vs. 9.5 months [95% CI, 7.9–10.7]). PFS was superior in the TV versus chemotherapy arm (HR, 0.67 [95% CI, 0.54–0.82]; *P* < .0001). Confirmed ORR was 17.8% and 5.2% in the TV and chemotherapy arms, respectively (odds ratio, 4.0; 95% CI, 2.1–7.6; *P* < .0001). The NCCN Guidelines for Cervical Cancer recommend tisotumab vedotin-tftv as a preferred therapy option for the treatment of recurrent/metastatic cervical cancer with disease progression on or after chemotherapy regardless of biomarker status.

Chemotherapy as Other Recommended, Second-line/Subsequent Therapy

The Panel re-evaluated the list of single-agent chemotherapies included as second-line/subsequent therapy options under the other recommended regimens category by re-voting on each of these agents for their efficacy and use based on Panel members' clinical experience and judgement. Other recommended agents that have shown responses or prolongation of PFS and may be useful as second-line therapy include bevacizumab,[320] albumin-bound paclitaxel (ie, nab-paclitaxel),[321] docetaxel,[322] fluorouracil,[323] gemcitabine,[324] ifosfamide,[325,326] irinotecan,[327] mitomycin,[328] pemetrexed,[329] topotecan,[330,331] and vinorelbine.[332]

Immunotherapy as Other Recommended, Second-line/Subsequent Therapy

Cemiplimab

Cemiplimab is a PD-1–blocking monoclonal activity shown to have anti-tumor activity against cervical cancer. The phase 3, randomized, EMPOWER/Cervical 1/GOG-3016 clinical trial evaluated the efficacy of cemiplimab or investigator's choice of chemotherapy (topotecan, vinorelbine, gemcitabine, irinotecan, or pemetrexed) in patients with recurrent or metastatic cervical cancer who have progressed on prior therapy.[333] The trial enrolled 608 patients, who had previously received one or more lines of systemic therapy for recurrence, were randomized to either receive cemiplimab or chemotherapy. The median OS and PFS were significantly longer in the cemiplimab arm than in the control arm (12 vs. 8.5 months; HR, 0.69; 95% CI, 0.56–0.84; *P* < .001 and 2.8 vs. 2.9 months; HR, 0.75; 95% CI, 0.63–0.89; *P* < .001, respectively). 16% of the patients in the test arm achieved an OR (95% CI, 12.5–21.1) as compared to 6.3% (95% CI, 3.8–9.6) in the chemotherapy arm. The median OS in SCC and AC/ASC cervical cancer in cemiplimab versus chemotherapy arm was 11.1 versus 8.8 months (HR, 0.73; 95% CI, 0.58–0.91) and 13.3 versus 7 months (HR, 0.56; 95% CI, 0.36–0.85), respectively, indicating that there is an OS benefit irrespective of histology. In a subanalysis of the study, samples from 254 patients were evaluated for PD-L1 expression to test the efficacy of cemiplimab in tumors with PD-L1 expression of ≥1%. The median OS of cemiplimab-treated PD-L1–expressed tumors (CPS ≥1) versus chemotherapy was 13.9 versus 9.3 months (HR, 0.70; 95% CI, 0.46–1.05) while the OS benefit for tumors with low PD-L1 expression (CPS <1) was comparable in the two arms, although the authors of the

Version 2.2026 © 2025 National Comprehensive Cancer Network® (NCCN®), All rights reserved. NCCN Guidelines®, and this illustration may not be reproduced in any form without the express written permission of NCCN.

PLEASE NOTE that use of this NCCN Content is governed by the End-User License Agreement, and you MAY NOT distribute this Content or use it with any artificial intelligence model or tool.
Printed by Galya Basol Kochav on 12/29/2025 12:47:39 PM. Copyright © 2025 National Comprehensive Cancer Network, Inc. All Rights Reserved.

study noted that due to smaller size of the subgroup population, reliable assessment of the benefits could not be made.

In the final analysis,[334] at a median follow-up of 47.3 months, median OS was 11.7 versus 8.5 months for patients treated with cemiplimab and chemotherapy, respectively (HR = 0.67; 95 % CI, 0.56-0.80; *P* < .00001). OS benefit was seen in PD-L1 positive and negative populations, even though more patients with PD-L1 <1% (n = 92), had poor performance status in the cemiplimab arm than the chemotherapy arm (61.4% vs. 47.9%). This final analysis confirmed that cemiplimab maintained survival benefit compared with chemotherapy in recurrent cervical cancer after progression on first-line platinum therapy, regardless of PD-L1 expression.

Based on these data, cemiplimab was added as other recommended regimen for second line/subsequent-therapy.

Ipilimumab and Nivolumab
Ipilimumab and nivolumab combination is also included based on CheckMate 358 trial.[335] In this phase 1/2 , open label, multicohort trial, out of 176 treated, recurrent or metastatic cervical cancer patients, 19 patients received nivolumab monotherapy, 45 received nivolumab/ipilimumab (nivolumab 3 mg/kg every 2 weeks/ipilimumab 1 mg/kg every 6 weeks), and 112 received NIVO1 plus IPI3 (nivolumab 1 mg/kg every 3 weeks plus ipilimumab 3 mg/kg every 3 weeks then nivolumab 240 mg every 2 weeks). Objective response rates were 26% (95% CI, 9–51) with nivolumab, 31% (95% CI,18–47) with NIVO3 plus IPI1, 40% (95% CI, 26–56) with randomized NIVO1 plus IPI3, and 38% (95% CI, 29–48) with pooled NIVO1 plus IPI3.

Biomarker-Directed, Useful in Certain Circumstances, Second-line/Subsequent Therapy

The NCCN Guidelines for Cervical Cancer have included a list of biomarkers with their associated targeted treatments as second-line/subsequent therapies under useful in certain circumstances options. The *Pathology* section of the Guidelines provides recommendations for individual biomarkers that should be evaluated for targeted therapy.

Nivolumab for PD-L1–Positive Tumor
Nivolumab, a checkpoint inhibitor, has shown efficacy in patients with recurrent/metastatic cervical cancer who received at least one prior chemotherapy regimen. Based on Checkmate-358 data (see *Prognostic and Predictive Biomarkers* section), in version 1.2023 of the NCCN Guidelines for Cervical Cancer, the Panel moved nivolumab from preferred, second-line or subsequent therapy options to the useful in certain circumstances category for PD-L1–positive tumors.

Tisotumab Vedotin with Pembrolizumab for PD-L1–Positive Tumor
TV with pembrolizumab has been added as another option for PD-L1 positive patients who have not received prior IO therapy under the useful in certain circumstances category for second-line or subsequent therapy based on innovaTV 205/GOG-3024/ENGOT-cx8 trial.[154]

Trastuzumab Deruxtecan for HER2-Positive Tumor
Another tumor-agnostic study evaluated the durability and clinically meaningful response of trastuzumab deruxtecan across multiple HER2-expressing (IHC 3+ or 2+) advanced solid tumor types in patients who progressed on prior therapy or who have no satisfactory alternative treatment options. HER2 expression is observed in a wide range of solid tumors and is an established prognostic biomarker for breast, gastric, and colorectal cancers. Cervical cancer has shown HER2 positivity rate of

Version 2.2026 © 2025 National Comprehensive Cancer Network® (NCCN®), All rights reserved. NCCN Guidelines®, and this illustration may not be reproduced in any form without the express written permission of NCCN.

approximately 2% to 6% in the literature.[164-166] Trastuzumab deruxtecan is an antibody-drug conjugate that contains the humanized anti-HER2 monoclonal antibody trastuzumab attached to the topoisomerase inhibitor deruxtecan.[167]

Based on DESTINY-PanTumor02 (see *Prognostic and Predictive Biomarkers* section) NCCN Guidelines for Cervical Cancer includes fam-trastuzumab deruxtecan-nxki as a category 2A, useful in certain circumstances, second line/subsequent therapy option for HER2-positive tumors (IHC 3+ or 2+). The Panel recommends HER2 IHC testing (with reflex to HER2 FISH for equivocal IHC) for advanced, metastatic, or recurrent cervical carcinoma.

Neratinib for HER2-Mutant Tumor
Based on the results from cervical cancer cohort of SUMMIT trial,[170] Neratinib has been added as a recommendation option for *HER2*-mutant tumors under useful in certain circumstances. (See *Prognostic and Predictive Biomarkers* section).

Selpercatinib for RET-Gene Fusion Tumor
Selpercatinib received tumor-agnostic approval by the FDA for patients with solid tumors with a *RET* gene fusion that has progressed on or following prior systemic treatment or who have no satisfactory alternative treatment options. The NCCN Panel recommends selpercatinib as a biomarker-directed second-line/subsequent therapy under useful in certain circumstances category for *RET*-gene fusion-positive tumors given its efficacy in tumor-agnostic population. The NCCN Panel also specified that *RET* gene fusion testing may be considered for patients with locally advanced or metastatic cervical cancer (see *Prognostic and Predictive Biomarkers* section).

TRK Inhibitors for NTRK-Gene Fusion Tumor
In addition to selpercatinib, other targeted therapy regimens included in the NCCN Guidelines for Cervical Cancer as biomarker-directed second-line/subsequent therapies that have been approved in a tumor-agnostic population are the tropomyosin receptor kinase (TRK) inhibitors, larotrectinib and entrectinib. Larotrectinib targets the TRK proteins that are encoded by the genes *NTRK1*, *NTRK2*, and *NTRK3*. *NTRK* gene fusions are found in about 1% of all solid tumors. The NCCN Guidelines for Cervical Cancer recommend larotrectinib, entrectinib and repotrectinib as a second-line or subsequent, useful in certain circumstances option for *NTRK*-gene fusion positive tumors and have changed the category of evidence from category 2B to category 2A based on FDA approval and several clinical trials (see *Prognostic and Predictive Biomarkers* section).

Principles of Radiation Therapy

Radiation therapy is often used in the management of patients with cervical cancer either 1) as definitive therapy for those with locally advanced disease or for those who are poor surgical candidates; or 2) as adjuvant therapy following radical hysterectomy for those who have one or more pathologic risk factors (eg, positive lymph nodes, parametrial infiltration, positive surgical margins, large tumor size, deep stromal invasion, LVSI).

The algorithm provides general RT dosage recommendations, which should not be interpreted as stand-alone recommendations because RT techniques and clinical judgment are an essential part of developing an appropriate treatment regimen. The ASTRO clinical practice guideline on radiation therapy for cervical cancer provides recommendations for the use of radiation therapy in the treatment of nonmetastatic cervical cancer, including postoperative radiation therapy for intermediate and high-risk factors, chemoradiation for stages IB3–IVA, and RT or chemoradiation for stages IA1–IB2 if medically inoperable. The guideline emphasizes the importance of intensity modulated radiation therapy (IMRT) and

Version 2.2026 © 2025 National Comprehensive Cancer Network® (NCCN®), All rights reserved. NCCN Guidelines®, and this illustration may not be reproduced in any form without the express written permission of NCCN.

brachytherapy, as well as the use of image-guided adaptive brachytherapy and MRI for treatment planning.[336]

Optimum staging of disease to precisely delineate the primary tumor volume and draining lymph nodes, including abdominopelvic radiologic studies (CT, MRI, or combined PET/CT scans), is recommended in patients with stage IB2, IIA2, or advanced-stage tumors. Contemporary imaging studies must be correlated with careful assessment of clinical findings to define tumor extent, especially regarding vaginal or parametrial extension.

Radiation Treatment Planning

Technologic advances in imaging, computer treatment planning systems, and linear accelerator technology have enabled the more precise delivery of radiation doses to the pelvis. However, physical accuracy of dose delivery must be matched to a clear understanding of tumor extent, potential pathways of spread, and historical patterns of locoregional recurrence to avoid geographic misses.

CT-based treatment planning with conformal blocking and dosimetry is considered standard care for EBRT. In patients who are not surgically staged, FDG-PET imaging is useful to help define the nodal volume of coverage and may be useful postoperatively to confirm removal of abnormal nodes.[337] IMRT technique is preferred to minimize toxicities in definitive treatment of the pelvis with or without para-aortic treatment. Regular use of image-guided radiation therapy (IGRT) with orthogonal imaging and/or routine volumetric imaging (such as cone beam CT) at the time of treatment delivery, is essential to ensure appropriate coverage of targets and sparing of normal tissues. Brachytherapy is a critical component of definitive therapy in patients with cervical cancer who are not candidates for surgery (ie, those with an intact cervix); it may also be used as adjuvant therapy. Brachytherapy is typically combined with EBRT in an integrated treatment plan. MRI imaging immediately preceding brachytherapy may be helpful in delineating residual tumor geometry. Stereotactic body radiotherapy (SBRT) allows delivery of very high doses of focused external beam radiation and may be applied to isolated metastatic sites.[76,338]

Routine image guidance, such as cone-beam CT (CBCT), may be helpful in defining daily internal soft tissue positioning. Concepts regarding the gross target volume (GTV), clinical target volume (CTV), planning target volume (PTV), organs at risk (OARs) and dose-volume histogram (DVH) have been defined for use in conformal radiotherapy, especially for IMRT.[339-341]

Point A, representing a paracervical reference point, has been the most widely used, validated, and reproducible dosing parameter used to date. However, limitations of the Point A dosing system include the fact that it does not consider the three-dimensional shape of tumors, nor individual tumor to normal tissue structure correlations.

Traditionally point A doses were based on widely validated dose fractionation for brachytherapy with low dose rate (LDR). The dose at point A assumes an LDR delivery of 40–70 cGy/h. The traditional LDR point A prescription dose was 70–80 Gy. Typical point A prescription doses are 5.5 Gy X 5 fractions for early disease and 6 Gy X 5 fractions for large tumors or those demonstrating a poor response. Another reasonable choice that has been well-studied in European trials for intracavity dosing to the high-risk CTV (HR-CTV) is 28 Gy in 4 fractions.[342]

Ferrigno et al published a report on the comparative outcome of cervical cancer patients treated with LDR and high dose rate (HDR) brachytherapy.[343] In this retrospective analysis, 190 patients were treated with LDR brachytherapy and 118 patients were treated with HDR brachytherapy. 57.4% of patients in the LDR group were FIGO stage II,

Version 2.2026 © 2025 National Comprehensive Cancer Network® (NCCN®), All rights reserved. NCCN Guidelines®, and this illustration may not be reproduced in any form without the express written permission of NCCN.

36.3% with stage III and 6.3% with stage I disease. In the HDR group, 47.4% of patients were FIGO stage III, 43.2% with stage II, and 9.3% with stage I disease. Median doses of LDR brachytherapy at Point A were 40 Gy and 50 Gy for patients treated with 1 and 2 implants, respectively. All patients from the HDR group were treated with 24 Gy in 4 fractions of 6 Gy to Point A.

With a median follow-up time of 70 months (LDR) and 33 months (HDR) groups, the OS, DFS, and local control at 5 years were better in the LDR group (69% vs. 55%, $P = .007$; 73% vs. 56%, $P = .002$; and 74% vs. 65%; $P = .04$, respectively) for all stages combined. However, for clinical stages I and II, no differences were seen in OS, DFS, and local control at 5 years between the two groups. For clinical stage III, although OS and DFS at 5 years were better in the LDR than in the HDR group (46% vs. 36%, $P = .04$ and 49% vs. 37%, $P = .03$, respectively), the 5-year probability of rectal complications was higher in the LDR group than in the HDR group (16% vs. 8%; $P = .03$).

Thus, similar outcomes were observed for patients who were stages I and II treated with either HDR or LDR brachytherapy. Although lower overall and disease-free survival and marginally lower local control were observed for patients who were stage III treated with HDR brachytherapy, less late rectal complications were observed in this group. These findings were probably the result of the relatively low HDR brachytherapy dose delivered at Point A.

There are increasing efforts to use and standardize image-based volumetric brachytherapy approaches using MR, CT or ultrasound – international validation efforts with different studies including EMBRACE-I study, which is a benchmark study that represents a positive breakthrough in the treatment of locally advanced cervical cancer.[342,344-349]

One such study analyzed the details of brachytherapy practice in cervical cancer patients in the United States between 1996 and 1999 to understand the impact of different practices across different facilities.[350] A total of 442 patient records were reviewed in 59 different radiation facilities that were selected from a stratified random sample to obtain data about patients' characteristics including tumor extent, and treatment. Unless otherwise specified, brachytherapy practice was based on the 408 patients who had their brachytherapy or all their treatment at the surveyed facility. A total of 91.5% of patients underwent brachytherapy at the initial treating institution; 8.5% were referred to a second site for brachytherapy. Of these patients who had brachytherapy, 77.8%, 13.3%, and 0.9%, respectively, were treated with LDR, HDR, or a combination of HDR and LDR brachytherapy; 7.9% had interstitial brachytherapy (5.7% LDR and 1.9% HDR, 0.3% mixed). The median duration of treatment and median Point A dose were very similar for patients treated with HDR or LDR. Patients with HDR were treated using a variety of treatment schedules. Different applicator types were favored for LDR versus HDR. Of patients treated with HDR, 73.4% had no brachytherapy bladder or rectal doses recorded, suggesting that full dosimetric calculations were performed only for the first fraction in many institutions. Facility size significantly impacted on referral to another institution for brachytherapy, brachytherapy dose, and treatment duration.

In EMBRACE-I trial, a prospective, observational, multicenter cohort study, cervical cancer patient data from 24 centers in Europe, Asia, and North America with FIGO stage 1B–IVA or stage IVB restricted to para-aortic lymph metastasis below the L1–L2 interspace were prospectively collected.[344] The patients were treated with CRT followed by MRI-based image-guided adaptive brachytherapy (IGABT) with primary endpoints being local control and late morbidity. Among 1341 patients analyzed, the actuarial overall 5-year local control was 92% (95% CI, 90–93) at a median follow-up of 51 months and actuarial cumulative 5-year incidence

Version 2.2026 © 2025 National Comprehensive Cancer Network® (NCCN®), All rights reserved. NCCN Guidelines®, and this illustration may not be reproduced in any form without the express written permission of NCCN.

PLEASE NOTE that use of this NCCN Content is governed by the End-User License Agreement, and you MAY NOT distribute this Content or use it with any artificial intelligence model or tool.
Printed by Galya Basol Kochav on 12/29/2025 12:47:39 PM. Copyright © 2025 National Comprehensive Cancer Network, Inc. All Rights Reserved.

of grade 3–5 morbidity from 1251 patients was 6.8% (95% CI, 5.4–8.6) for genitourinary events, 8.5% (6.9–10.6) for gastrointestinal events, 5.7% (4.3–7.6) for vaginal events, and 3.2% (2.2–4.5) for fistulae. CRT and MRI-based IGABT result in effective and stable long-term local control across all stages of locally advanced cervical cancer, with a limited severe morbidity per organ.

A unified approach to techniques and prescription/fractionation schedules for both EBRT and IGABT is required and RetroEMBRACE and EMBRACE I studies have demonstrated that clinical outcome is related to dose prescription and technique. The EMBRACE II study is an interventional and observational multicenter study which aims to benchmark a high level of local, nodal, and systemic control while limiting morbidity, using an advanced target volume selection and contouring protocol for EBRT and a multi-parametric brachytherapy dose prescription protocol for brachytherapy, and use of advanced EBRT (IMRT and IGRT) and brachytherapy (Intracavitary/Interstitial-IC/IS) techniques.[351]

For EMBRACE-II, 153 patients were treated with: IMRT/VMAT, daily IGRT, 45 Gy over 25 fractions for the elective CTV, and simultaneously integrated boost for pathologic lymph nodes. Application of IMRT/VMAT, IGRT, and a 45 to Gy dose provides the potential of higher conformality inducing significant reduction of treated volume and the study is currently underway.[352] For patients with locally advanced cancers, initial radiation treatment of 40 to 45 Gy to the whole pelvis is often necessary to obtain tumor shrinkage to permit optimal intracavitary placements. With low dose-rate intracavitary systems, total doses from brachytherapy and EBRT to point A of at least 80 Gy are currently recommended for small tumors, with doses of 85 Gy or higher recommended for larger tumors (http://www.americanbrachytherapy.org/guidelines/cervical_cancer_taskgroup.pdf).[174]

For lesions in the lower one third of the vagina, the inguinal lymph nodes must be treated. The use of extended-field radiation to treat occult or macroscopic para-aortic lymph node disease must be carefully planned to ensure an adequate dose (45 Gy for microscopic disease) without exceeding bowel, spinal cord, or renal tolerances.[353] General recommendations for radiation volumes and doses are discussed in the algorithm.

Intensity-modulated RT is becoming more widely available; however, issues regarding target definition, patient and target immobilization, tissue deformation, toxicity, and reproducibility remain to be validated.[354-361] Initial phase II hematologic toxicity data from RTOG 418 suggested that limiting the volume of bone marrow treated with IMRT was an important consideration for patients with cervical cancer who were receiving concurrent chemotherapy.[362] The reported TIME-C trial (RTOG 1203, NCT01672892) compared post-hysterectomy patients receiving adjuvant IMRT or standard four-field RT to determine whether IMRT reduced acute toxicity. Among the 278 patients with cervical and endometrial cancer included in the analysis, pelvic IMRT was associated with significantly lower scores for gastrointestinal and urinary toxicity than standard RT.[363] Dose-escalated IMRT (limiting V55 to below 15 cm^3 and limiting the dose to duodenum) can safely and effectively treat para-aortic nodal disease in gynecologic malignancies reducing the risk of late duodenal toxicity.[364] Among 105 patients with gynecologic primary tumors (including 38 cervical patients) and treated to a nodal clinical target volume to 45 to 50.4 Gy with a boost to 60 to 66 Gy, only nine of 105 patients (2/38 cervical patients) experienced duodenal toxicity with 3-year actuarial rate of any duodenal toxicity of 11.7%. IMRT technique can reduce acute and chronic gastrointestinal and hematologic toxicity. An International Multicenter Phase II Clinical Trial (INTERTECC-2) evaluated acute hematologic and gastrointestinal (GI) toxicity for patients with locoregionally in which 83 patients met the eligibility criteria and received weekly cisplatin

Version 2.2026 © 2025 National Comprehensive Cancer Network® (NCCN®), All rights reserved. NCCN Guidelines®, and this illustration may not be reproduced in any form without the express written permission of NCCN.

PLEASE NOTE that use of this NCCN Content is governed by the End-User License Agreement, and you MAY NOT distribute this Content or use it with any artificial intelligence model or tool.
Printed by Galya Basol Kochav on 12/29/2025 12:47:39 PM. Copyright © 2025 National Comprehensive Cancer Network, Inc. All Rights Reserved.

concurrently with once-daily IMRT, followed by intracavitary brachytherapy.[365] The primary endpoint was the occurrence of either acute grade ≥3 neutropenia or clinically significant GI toxicity within 30 days of completing chemoradiation therapy. The incidence of any primary event was 26.5% (95% CI, 18.2%–36.9%), and the incidence of grade ≥3 neutropenia and clinically significant GI toxicity was 19.3% (95% CI, 12.2%–29.0%) and 12.0% (95% CI, 6.7%–20.8%), respectively. Compared with patients treated without IG-IMRT (n = 48), those treated with IG-IMRT (n = 35) had a significantly lower incidence of grade ≥3 neutropenia (8.6% vs. 27.1%; 2-sided $\chi 2$; $P = .035$). Several retrospective analyses suggest that prolonged RT treatment duration has an adverse effect on outcome.[366-370] Extending the overall treatment beyond 6 to 8 weeks can result in approximately a 0.5% to 1% decrease in pelvic control and cause specific survival for each extra day of overall treatment time. Thus, although no prospective randomized trials have been performed, it is generally accepted that the entire RT course (including both EBRT and brachytherapy components) should be completed in a timely fashion (within 8 weeks); delays or splits in the radiation treatment should be avoided whenever possible.

Techniques for re-irradiation may include IORT, intracavitary or interstitial brachytherapy, SBRT, IMRT, or proton therapy.[371-373] Such cases are highly customized and depend on the target, proximity to critical organs, previous RT dose, extent of overlap, and time intervals since prior RT. The appropriate dose for each case needs to be individualized.

Normal Tissue Considerations

Planning for RT in cervical cancer must take into account the potential impact on surrounding critical structures, such as rectum, bladder, sigmoid, small bowel, and bone. Acute effects (ie, diarrhea, bladder irritation, fatigue) occur to some degree in most patients undergoing radiation and are typically magnified by concurrent chemotherapy. However, acute effects can often be managed with medications and supportive care, and they generally resolve soon after completion of radiation. To avoid treatment-related menopause, ovarian transposition can be considered before pelvic RT in select young patients (<45 years with early-stage disease).[180-182]

After therapy for cervical cancer, late side effects may include potential injury to bladder, rectum, bowel, and pelvic skeletal structures.[374] The risk of major complications (eg, obstruction, fibrosis/necrosis, and fistula) is related to the volume, total dose, dose per fraction, and specific intrinsic radiosensitivity of the normal tissue that is irradiated.[353,375,376] Careful blocking in order to minimize normal tissue exposure while maintaining tumor coverage is critical for optimal outcomes. In addition, patient-related conditions (ie, inflammatory bowel disease, collagen-vascular disease, multiple abdominal/pelvic surgeries, history of pelvic inflammatory disease, diabetes) influence determination of radiation dose and volumes.

For most patients, it is generally accepted that the whole pelvis can tolerate an external-beam radiation dose of 40 to 50 Gy. Gross disease in the parametria or unresected nodes may be treated with tightly contoured external-beam boosts to 60 to 65 Gy. Intracavitary brachytherapy boosts require attention to proper placement of the applicators within the uterus and against the cervix and vaginal apex, as well as appropriate packing to maximally displace the bladder and rectum. SBRT is not considered an appropriate routine alternative to brachytherapy. Normal tissue dose constraint guidelines for cervical cancer are added to the guidelines. Although the suggested dose constraints are provided in the guidelines, the NCCN Panel recommends that the clinicians must balance the risks of normal tissue toxicity with tumor control.

Version 2.2026 © 2025 National Comprehensive Cancer Network® (NCCN®), All rights reserved. NCCN Guidelines®, and this illustration may not be reproduced in any form without the express written permission of NCCN.

PLEASE NOTE that use of this NCCN Content is governed by the End-User License Agreement, and you MAY NOT distribute this Content or use it with any artificial intelligence model or tool.
Printed by Galya Basol Kochav on 12/29/2025 12:47:39 PM. Copyright © 2025 National Comprehensive Cancer Network, Inc. All Rights Reserved.

Small Cell Neuroendocrine Carcinoma of the Cervix

Overview

Neuroendocrine tumors (NETs) are a highly heterogeneous group of neoplasms derived from ubiquitous neuroendocrine cells, mostly from the lungs, the gastrointestinal tract, and the pancreas, but more rarely are found in almost all body tissues including uncommon sites, such as female genital tract.[377] The 2014 WHO Classification of neuroendocrine tumors has been updated with adoption of the terms low-grade NET and high-grade neuroendocrine carcinoma (NEC). In the endometrium and cervix, high-grade NEC are much more prevalent than low-grade and are more common in the cervix.[378]

NECC accounts for about 1% to 1.5% of all cervical cancers and is an aggressive histological variant of cervical cancer.[379] Although rare, the cervix is the most common site for neuroendocrine carcinoma (eg, small cell and large cell neuroendocrine carcinoma) in the genital tract. Small cell NEC is the most common type of NECC, whereas well-differentiated NET, especially NET G1 (typical carcinoid) and NET G2 (atypical carcinoid), are very rare at this location.[378]

Primary Workup

Small cell neuroendocrine cervical cancer is an aggressive type of cervical cancer and most data on treatment regimens for this disease have been adapted from NCCN lung and pulmonary disease-management guidelines (NCCN Guidelines for Neuroendocrine and Adrenal Tumors and NCCN Guidelines for Non-Small Cell Lung Cancer, both available at www.NCCN.org) given that small cell disease is commonplace in those settings. Because this condition is rare in the gynecologic realm and few data are available on small cell cervical cancer, high-level randomized trials are difficult to achieve and some of the primary workup and treatment recommendations are based on cervical cancer guidelines as well.[380] FIGO staging system is implemented to describe characteristics and outcomes of patients with small cell neuroendocrine carcinoma of the cervix (small cell NECC) since it is more predictive than the two-tier staging system. Most patients were treated with cisplatin and etoposide.[381]

Radical hysterectomy with SLN mapping or pelvic lymphadenectomy with or without para-aortic lymph node sampling is one of the primary treatment options recommended for NECC tumors confined to the cervix (≤ 4 cm), followed by adjuvant treatment with chemotherapy (cisplatin/etoposide or carboplatin/etoposide) or chemoradiation. Chemoradiation and brachytherapy combination is also a recommended primary treatment with additional consideration of systemic therapy. For NECC tumors confined to the cervix that are greater than 4 cm, chemoradiation along with brachytherapy and neoadjuvant chemotherapy with cisplatin/etoposide or carboplatin/etoposide are some primary treatment options. Radical hysterectomy can be considered if not previously done, followed by adjuvant radiation or chemoradiation.

For locally advanced, stage IIA–IVA disease, chemoradiation with cisplatin (or carboplatin) plus etoposide with brachytherapy with or without chemotherapy (preferred) or neoadjuvant chemotherapy are primary treatment options. Based on the treatment response and disease persistence or recurrence with local disease, the patient can be further treated with pelvic exenteration other systemic therapy/best supportive care.

Principles of Pathology

NECC is clinically aggressive, with rapid metastasis and a frequently poor clinical outcome. NECC is usually HPV-associated; types 16 and 18 are the most common (18 more often than 16).[382] This carcinoma type morphologically resembles neuroendocrine carcinomas of the lung. Small cell NECC is a morphologic diagnosis regardless of IHC staining profile. Most NECCs are diffusely positive for p16 due to the presence of high-risk HPV. However, p16 positivity cannot be used to aid in

Version 2.2026 © 2025 National Comprehensive Cancer Network® (NCCN®), All rights reserved. NCCN Guidelines®, and this illustration may not be reproduced in any form without the express written permission of NCCN.

PLEASE NOTE that use of this NCCN Content is governed by the End-User License Agreement, and you MAY NOT distribute this Content or use it with any artificial intelligence model or tool.
Printed by Galya Basol Kochav on 12/29/2025 12:47:39 PM. Copyright © 2025 National Comprehensive Cancer Network, Inc. All Rights Reserved.

determining the site of origin; neuroendocrine carcinomas arising at other sites may strongly express p16 due to a non-HPV–related process.

If the tumor demonstrates classic morphologic features of small cell NECC, the diagnosis can be made in the absence of IHC neuroendocrine positivity because of the high variability in the expression levels. Small cell NECC is variably positive for chromogranin, CD56, and synaptophysin by IHC. CD56 and synaptophysin are the most sensitive neuroendocrine markers, but CD56 lacks specificity. Chromogranin is the most specific neuroendocrine marker but lacks sensitivity with only about 50% to 60% of small cell NECC being positive. Insulinoma-associated protein 1 (INSM1) and synaptophysin are other neuroendocrine markers, with 80% and 70% positivity, respectively.[383,384] A high percentage of primary NECCs are thyroid transcription factor-1 (TTF1)-positive, including some with diffuse immunoreactivity, and this marker is of no value in distinction from a pulmonary metastasis. Small cell NECC may be only focally positive (often punctuate cytoplasmic staining) or even negative with broad-spectrum cytokeratins.

Systemic Therapy

Chemoradiation

NECC, being a rare variant of cervical cancer with a poor prognosis, based on a systematic review, multimodality treatment with radical surgery and neoadjuvant/adjuvant chemotherapy with cisplatin and etoposide with or without radiotherapy is the mainstay of treatment for early-stage disease while chemotherapy with cisplatin and etoposide or topotecan, paclitaxel, and bevacizumab is appropriate for women with locally advanced or recurrent NECC.[379]

The dosing and schedule for chemoradiation and first-line adjuvant therapy are based on NCCN Guidelines for Small Cell Lung Cancer (SCL-E, available at www.NCCN.org). Cisplatin and etoposide combination is one of the most common adjuvant chemotherapy regimens based on literature and tend to have a better prognosis,[385] and is the preferred regimen in chemoradiation and first-line therapy for recurrent or metastatic small cell NECC.

First-line Therapy

Many physicians use carboplatin/paclitaxel because of ease of administration and tolerability, similar to cervical cancer.[292,303] The addition of atezolizumab to chemotherapy in the first-line treatment of extensive-stage small-cell lung cancer resulted in significantly longer overall survival and progression-free survival than chemotherapy alone.[386] A double-blind, placebo-controlled, phase 3 trial evaluated atezolizumab plus carboplatin and etoposide in patients with extensive-stage small-cell lung cancer who had not previously received treatment. A total of 201 patients were randomly assigned to receive carboplatin and etoposide with atezolizumab and 202 patients were assigned to receive placebo after carboplatin and etoposide in the induction phase. At a median follow-up of 13.9 months, the median overall survival was 12.3 months in the atezolizumab group and 10.3 months in the placebo group (HR for death, 0.70; 95% CI, 0.54–0.91; $P = .007$). The median PFS was 5.2 months and 4.3 months, respectively (HR for disease progression or death, 0.77; 95% CI, 0.62–0.96; $P = .02$). Based on these results in small cell lung cancer, a high-grade neuroendocrine carcinoma, the NCCN Panel recommends Cisplatin(or carboplatin)/etoposide with atezolizumab under other recommended regimens for recurrent or metastatic small cell NECC.

The CASPIAN trial[387] assessed durvalumab, with or without tremelimumab, in combination with etoposide plus either cisplatin or carboplatin (platinum-etoposide) in patients with extensive-stage small cell lung cancer (ES-SCLC) who never received treatment and demonstrated that first-line durvalumab plus platinum-etoposide significantly improved overall survival in patients with ES-SCLC. In this randomized, open-label, phase 3 trial, 268 patients were randomly allocated to the durvalumab plus

Version 2.2026 © 2025 National Comprehensive Cancer Network® (NCCN®), All rights reserved. NCCN Guidelines®, and this illustration may not be reproduced in any form without the express written permission of NCCN.

platinum-etoposide group and 269 to the platinum-etoposide group. Durvalumab plus platinum-etoposide was associated with a significant improvement in overall survival, with HR of 0.73 (95% CI, 0.59–0.91; *P* = .0047]); median overall survival was 13.0 months (95% CI, 11.5–14.8) in the durvalumab plus platinum-etoposide group versus 10.3 months (9.3–11.2) in the platinum-etoposide group. Based on this trial data, a combination of durvalumab with Cisplatin (or carboplatin) and etoposide is one of the recommended regimens for first-line, recurrent or metastatic small cell NECC along with atezolizumab. Based on the published data from IMscin001 trial,[388] FDA recently approved atezolizumab and hyaluronidase-tqjs for subcutaneous injection as the intravenous formulation of atezolizumab and this is added in the footnote. Other recommended regimens for first line therapy for recurrent or metastatic small cell NECC includes topotecan, paclitaxel and bevacizumab combination. Frumovitz et al,[389] assessed the activity of topotecan, paclitaxel, and bevacizumab (TPB) in recurrent small cell cervical cancer (SCCC) and compared the survival of patients with SCCC who received TPB versus not receiving this regimen. In this retrospectively analyzed study of women with recurrent SCCC who received chemotherapy as primary therapy, 13 women treated with TPB for first recurrence were compared to 21 women treated with non-TPB chemotherapy, most commonly platinum with or without a taxane. Median PFS was 7.8 months for TPB and 4.0 months for non-TPB regimens (HR, 0.21; 95% CI, 0.09–0.54; *P* = .001). Median OS was 9.7 months for TPB and 9.4 months for non-TPB regimens (HR, 0.53; 95% CI, 0.23–1.22; *P* = .13). These findings from the study indicated that TPB for recurrent SCCC significantly improved PFS over non-TPB regimens.

Other Recommended Regimens

In addition to other recommended agents that include bevacizumab,[320] albumin bound paclitaxel (ie, nab paclitaxel),[321] docetaxel,[322] irinotecan,[327] and topotecan,[330,331] Ipilimumab and nivolumab combination is also included based on case reports demonstrating durable response.[390] In this phase 1/2, open label, multicohort trial, out of 176 treated, recurrent or metastatic cervical cancer patients, 19 patients received nivolumab monotherapy, 45 received nivolumab/ipilimumab (nivolumab 3 mg/kg every 2 weeks/ ipilimumab 1 mg/kg every 6 weeks), and 112 received NIVO1 plus IPI3 (nivolumab 1 mg/kg every 3 weeks plus ipilimumab 3 mg/kg every 3 weeks then nivolumab 240 mg every 2 weeks). Objective response rates were 26% (95% CI, 9–51) with nivolumab, 31% (95% CI,18–47) with NIVO3 plus IPI1, 40% (95% CI, 26–56) with randomized NIVO1 plus IPI3, and 38% (95% CI, 29–48) with pooled NIVO1 plus IPI3.

Cervical Cancer and Pregnancy

Cervical cancer is the most frequently diagnosed gynecologic malignancy in pregnant individuals; however, most of these patients have stage I disease.[391-394] Invasive cervical cancer during pregnancy creates a clinical dilemma and requires multidisciplinary care.[391,395] Patients must make the difficult decision either to delay treatment until documented fetal maturity or to undergo immediate treatment based on their stage of disease.[392,395] Patients who delay treatment until fetal maturity should have their children delivered by cesarean section.[394,396,397] Radical trachelectomy with preservation of pregnancy has been successfully performed in a few pregnant patients with early-stage cervical cancer.[66,398-400] Patients with early-stage disease may prefer to have radical hysterectomy and node dissection instead of RT to avoid radiation fibrosis and to preserve their ovaries. Patients with stage I disease who delay treatment until fetal maturity can undergo cesarean section with concurrent radical hysterectomy and pelvic node dissection. For those choosing RT, traditional RT with (or without) chemotherapy protocols (described previously) may need to be modified.[394]

Version 2.2026 © 2025 National Comprehensive Cancer Network® (NCCN®), All rights reserved. NCCN Guidelines®, and this illustration may not be reproduced in any form without the express written permission of NCCN.

PLEASE NOTE that use of this NCCN Content is governed by the End-User License Agreement, and you MAY NOT distribute this Content or use it with any artificial intelligence model or tool.
Printed by Galya Basol Kochav on 12/29/2025 12:47:39 PM. Copyright © 2025 National Comprehensive Cancer Network, Inc. All Rights Reserved.

Drug Reactions

Virtually all drugs have the potential to cause adverse reactions, either during or after infusion.[401] In cervical cancer treatment, drugs that more commonly cause adverse reactions include carboplatin, cisplatin, docetaxel, liposomal doxorubicin, and paclitaxel. Most of these drug reactions are mild infusion reactions (ie, skin reactions, cardiovascular reactions, respiratory or throat tightness), but more severe allergic reactions (ie, life-threatening anaphylaxis) can occur.[402,403] In addition, patients can have severe infusion reactions and mild allergic reactions. Infusion reactions are more common with paclitaxel.[404] Allergic reactions (ie, true drug allergies) are more common with platinum agents (eg, cisplatin).[404,405] Management of drug reactions is discussed in the NCCN Guidelines for Ovarian Cancer (available at www.NCCN.org).[404] Importantly, patients who experienced severe life-threatening reactions should not receive the implicated agent again unless evaluated by an allergist or specialist in drug desensitization. If a mild allergic reaction previously occurred and it is appropriate to re-administer the drug, a desensitization regimen is recommended even if the symptoms have resolved. Various desensitization regimens have been published and should be followed.[405-407] Patients must be desensitized with each infusion if they have had a previous reaction. Almost all patients can be desensitized.[401] To maximize safety, patients should be desensitized in the intensive care unit.[401]

Gynecologic Survivorship

Treatment for gynecologic cancer typically involves surgery, chemotherapy, hormone therapy, RT, and/or immunotherapy, which may cause acute, short term, and long-term toxicities. Surgical approaches may be extensive and cause adhesions to form, which in turn may cause pain and contribute to the development of small bowel obstruction, urinary or gastrointestinal complications (eg, incontinence, diarrhea), pelvic floor dysfunction (manifested by a variety of urinary, bowel, and/or sexual effects), and lymphedema. Chemotherapy agents vary, though commonly used regimens may pose a significant risk of neurotoxicity, cardiac toxicity, cognitive dysfunction, and the development of hematologic cancers. Long-term estrogen deprivation may cause symptoms such as hot flashes, vaginal dryness, and bone loss. RT may cause long-term complications (eg, fibrosis, stenosis, vulvovaginal atrophy) and may predispose patients to subsequent cancers of the skin, subcutaneous tissue, and/or underlying organs that are proximal to the radiation field. Use of immunotherapy agents in gynecologic cancers is emerging, and to date, long term effects of these treatments are unknown.

Following completion of treatment, all gynecologic cancer survivors should receive regular general medical care that focuses on managing chronic diseases (eg, depression, diabetes, hypertension), monitoring cardiovascular risk factors, receiving recommended vaccinations, and encouraging adoption of a healthy lifestyle (eg, promoting exercise, smoking cessation). To assess the late and long-term effects of gynecologic cancers, clinicians should comprehensively document the patient's history, including prior treatment history, and conduct a thorough physical examination followed by necessary imaging and/or laboratory testing. As most treatments for gynecologic cancers will cause sexual dysfunction, early menopause, and infertility, special attention to the resultant medical and psychosocial implications is needed. All patients, whether sexually active or not, should be asked about genitourinary symptoms, including vulvovaginal dryness. Post-radiation use of vaginal dilators and moisturizers is recommended. Psychosocial effects may include psychological (eg, depression, anxiety, fear of recurrence, altered body image), financial (eg, return to work, insurance concerns), and interpersonal (eg, relationships, sexuality, intimacy). Patients should be referred to appropriate specialty providers (eg, physical therapy, pelvic floor therapy, sexual therapy, psychotherapy) as needed, based on prior

Version 2.2026 © 2025 National Comprehensive Cancer Network® (NCCN®), All rights reserved. NCCN Guidelines®, and this illustration may not be reproduced in any form without the express written permission of NCCN.

PLEASE NOTE that use of this NCCN Content is governed by the End-User License Agreement, and you MAY NOT distribute this Content or use it with any artificial intelligence model or tool.
Printed by Galya Basol Kochav on 12/29/2025 12:47:39 PM. Copyright © 2025 National Comprehensive Cancer Network, Inc. All Rights Reserved.

treatment history and assessed risk of developing late effects and/or existing concerns. Communication and coordination with all clinicians involved in the care of survivors, including primary care clinicians, is critical. Providing survivors with a summary of their treatment and recommendations for follow up is also recommended. To this end, the SGO has developed templates for gynecologic cancer specific survivorship care plans to aid survivors and their clinicians in summarizing cancer history, treatments received, possible side effects, and recommended follow up.

Best Supportive Care

Patients with refractory systemic cancer warrant a comprehensive coordinated approach involving hospice care, pain consultants, and emotional and spiritual support, individualized to the situation (see the NCCN Guidelines for Palliative Care, available at www.NCCN.org).

Summary

Cervical cancer is decreasing in the United States because of the wide use of screening; however, it is increasing in developing countries (~275,000 deaths/year), because screening is not available to many. Effective treatment for cervical cancer (including surgery and concurrent chemoradiation) can yield cures in 80% of patients with early-stage disease (stages I–II) and in 60% of patients with stage III disease. The hope is that immunization against HPV (using vaccines) will prevent persistent infection with the types of HPV against which the vaccine is designed and will therefore prevent specific HPV cancer.[28,29,408]

Version 2.2026 © 2025 National Comprehensive Cancer Network® (NCCN®), All rights reserved. NCCN Guidelines®, and this illustration may not be reproduced in any form without the express written permission of NCCN.

PLEASE NOTE that use of this NCCN Content is governed by the End-User License Agreement, and you MAY NOT distribute this Content or use it with any artificial intelligence model or tool.
Printed by Galya Basol Kochav on 12/29/2025 12:47:39 PM. Copyright © 2025 National Comprehensive Cancer Network, Inc. All Rights Reserved.

References

1. Siegel RL, Giaquinto AN, Jemal A. Cancer statistics, 2024. CA Cancer J Clin 2024;74:12–49. Available at: https://www.ncbi.nlm.nih.gov/pubmed/38230766.

2. Siegel RL, Kratzer TB, Giaquinto AN, et al. Cancer statistics, 2025. CA Cancer J Clin 2025;75:10–45. Available at: https://www.ncbi.nlm.nih.gov/pubmed/39817679.

3. Miller KD, Ortiz AP, Pinheiro PS, et al. Cancer statistics for the US Hispanic/Latino population, 2021. CA Cancer J Clin 2021;71:466–487. Available at: https://www.ncbi.nlm.nih.gov/pubmed/34545941.

4. Amboree TL, Damgacioglu H, Sonawane K, et al. Recent trends in cervical cancer incidence, stage at diagnosis, and mortality according to county-level income in the United States, 2000-2019. Int J Cancer 2024;154:1549–1555. Available at: https://www.ncbi.nlm.nih.gov/pubmed/38270521.

5. Gopalani SV, Janitz AE, Campbell JE. Cervical Cancer Incidence and Mortality among Non-Hispanic African American and White Women, United States, 1999-2015. J Natl Med Assoc 2020;112:632–638. Available at: https://www.ncbi.nlm.nih.gov/pubmed/32651038.

6. Yu L, Sabatino SA, White MC. Rural-Urban and Racial/Ethnic Disparities in Invasive Cervical Cancer Incidence in the United States, 2010-2014. Prev Chronic Dis 2019;16:E70. Available at: https://www.ncbi.nlm.nih.gov/pubmed/31172917.

7. Cohen CM, Wentzensen N, Castle PE, et al. Racial and Ethnic Disparities in Cervical Cancer Incidence, Survival, and Mortality by Histologic Subtype. J Clin Oncol 2023;41:1059–1068. Available at: https://www.ncbi.nlm.nih.gov/pubmed/36455190.

8. Matz M, Weir HK, Alkhalawi E, et al. Disparities in cervical cancer survival in the United States by race and stage at diagnosis: An analysis of 138,883 women diagnosed between 2001 and 2014 (CONCORD-3). Gynecol Oncol 2021;163:305–311. Available at: https://www.ncbi.nlm.nih.gov/pubmed/34454725.

9. Bray F, Laversanne M, Sung H, et al. Global cancer statistics 2022: GLOBOCAN estimates of incidence and mortality worldwide for 36 cancers in 185 countries. CA Cancer J Clin 2024;74:229–263. Available at: https://www.ncbi.nlm.nih.gov/pubmed/38572751.

10. Singh D, Vignat J, Lorenzoni V, et al. Global estimates of incidence and mortality of cervical cancer in 2020: a baseline analysis of the WHO Global Cervical Cancer Elimination Initiative. Lancet Glob Health 2023;11:e197–e206. Available at: https://www.ncbi.nlm.nih.gov/pubmed/36528031.

11. Momenimovahed Z, Mazidimoradi A, Maroofi P, et al. Global, regional and national burden, incidence, and mortality of cervical cancer. Cancer Rep (Hoboken) 2023;6:e1756. Available at: https://www.ncbi.nlm.nih.gov/pubmed/36545760.

12. Cervical Cancer: Estimated Incidence, Mortality and Prevalence Worldwide in 2022. International Agency for Research on Cancer and World Health Organization; 2022. Available at: https://gco.iarc.who.int/media/globocan/factsheets/cancers/23-cervix-uteri-fact-sheet.pdf. Accessed February 26, 2024.

13. Sung H, Ferlay J, Siegel RL, et al. Global Cancer Statistics 2020: GLOBOCAN Estimates of Incidence and Mortality Worldwide for 36 Cancers in 185 Countries. CA Cancer J Clin 2021;71:209–249. Available at: https://www.ncbi.nlm.nih.gov/pubmed/33538338.

14. Kamangar F, Dores GM, Anderson WF. Patterns of cancer incidence, mortality, and prevalence across five continents: defining priorities to reduce cancer disparities in different geographic regions of the world. J Clin Oncol 2006;24:2137–2150. Available at: https://www.ncbi.nlm.nih.gov/pubmed/16682732.

15. Bray F, Loos AH, McCarron P, et al. Trends in cervical squamous cell carcinoma incidence in 13 European countries: changing risk and the effects of screening. Cancer Epidemiol Biomarkers Prev 2005;14:677–686. Available at: https://www.ncbi.nlm.nih.gov/pubmed/15767349.

16. Wang SS, Sherman ME, Hildesheim A, et al. Cervical adenocarcinoma and squamous cell carcinoma incidence trends among white women and

Version 2.2026 © 2025 National Comprehensive Cancer Network® (NCCN®), All rights reserved. NCCN Guidelines®, and this illustration may not be reproduced in any form without the express written permission of NCCN.

PLEASE NOTE that use of this NCCN Content is governed by the End-User License Agreement, and you MAY NOT distribute this Content or use it with any artificial intelligence model or tool.
Printed by Galya Basol Kochav on 12/29/2025 12:47:39 PM. Copyright © 2025 National Comprehensive Cancer Network, Inc. All Rights Reserved.

black women in the United States for 1976-2000. Cancer 2004;100:1035–1044. Available at: https://www.ncbi.nlm.nih.gov/pubmed/14983500.

17. Castellsague X, Diaz M, de Sanjose S, et al. Worldwide human papillomavirus etiology of cervical adenocarcinoma and its cofactors: implications for screening and prevention. J Natl Cancer Inst 2006;98:303–315. Available at: https://www.ncbi.nlm.nih.gov/pubmed/16507827.

18. Sasieni P, Castanon A, Cuzick J. Screening and adenocarcinoma of the cervix. Int J Cancer 2009;125:525–529. Available at: https://www.ncbi.nlm.nih.gov/pubmed/19449379.

19. Stolnicu S, Barsan I, Hoang L, et al. International Endocervical Adenocarcinoma Criteria and Classification (IECC): A New Pathogenetic Classification for Invasive Adenocarcinomas of the Endocervix. Am J Surg Pathol 2018;42:214–226. Available at: https://www.ncbi.nlm.nih.gov/pubmed/29135516.

20. Kjaer SK, Frederiksen K, Munk C, Iftner T. Long-term absolute risk of cervical intraepithelial neoplasia grade 3 or worse following human papillomavirus infection: role of persistence. J Natl Cancer Inst 2010;102:1478–1488. Available at: https://www.ncbi.nlm.nih.gov/pubmed/20841605.

21. Rodriguez AC, Schiffman M, Herrero R, et al. Longitudinal study of human papillomavirus persistence and cervical intraepithelial neoplasia grade 2/3: critical role of duration of infection. J Natl Cancer Inst 2010;102:315–324. Available at: https://www.ncbi.nlm.nih.gov/pubmed/20157096.

22. Ong SK, Abe SK, Thilagaratnam S, et al. Towards elimination of cervical cancer - human papillomavirus (HPV) vaccination and cervical cancer screening in Asian National Cancer Centers Alliance (ANCCA) member countries. Lancet Reg Health West Pac 2023;39:100860. Available at: https://www.ncbi.nlm.nih.gov/pubmed/37576906.

23. Brown DR, Joura EA, Yen GP, et al. Systematic literature review of cross-protective effect of HPV vaccines based on data from randomized clinical trials and real-world evidence. Vaccine 2021;39:2224–2236. Available at: https://www.ncbi.nlm.nih.gov/pubmed/33744051.

24. Lei J, Ploner A, Elfstrom KM, et al. HPV Vaccination and the Risk of Invasive Cervical Cancer. N Engl J Med 2020;383:1340–1348. Available at: https://www.ncbi.nlm.nih.gov/pubmed/32997908.

25. Villa LL, Costa RL, Petta CA, et al. Prophylactic quadrivalent human papillomavirus (types 6, 11, 16, and 18) L1 virus-like particle vaccine in young women: a randomised double-blind placebo-controlled multicentre phase II efficacy trial. Lancet Oncol 2005;6:271–278. Available at: https://www.ncbi.nlm.nih.gov/pubmed/15863374.

26. Ault KA, Future IISG. Effect of prophylactic human papillomavirus L1 virus-like-particle vaccine on risk of cervical intraepithelial neoplasia grade 2, grade 3, and adenocarcinoma in situ: a combined analysis of four randomised clinical trials. Lancet 2007;369:1861–1868. Available at: https://www.ncbi.nlm.nih.gov/pubmed/17544766.

27. Group FIS. Quadrivalent vaccine against human papillomavirus to prevent high-grade cervical lesions. N Engl J Med 2007;356:1915–1927. Available at: https://www.ncbi.nlm.nih.gov/pubmed/17494925.

28. Arbyn M, Dillner J. Review of current knowledge on HPV vaccination: an appendix to the European Guidelines for Quality Assurance in Cervical Cancer Screening. J Clin Virol 2007;38:189–197. Available at: https://www.ncbi.nlm.nih.gov/pubmed/17258503.

29. Rambout L, Hopkins L, Hutton B, Fergusson D. Prophylactic vaccination against human papillomavirus infection and disease in women: a systematic review of randomized controlled trials. CMAJ 2007;177:469–479. Available at: https://www.ncbi.nlm.nih.gov/pubmed/17671238.

30. Dahlstrom LA, Ylitalo N, Sundstrom K, et al. Prospective study of human papillomavirus and risk of cervical adenocarcinoma. Int J Cancer 2010;127:1923–1930. Available at: https://www.ncbi.nlm.nih.gov/pubmed/20473898.

Version 2.2026 © 2025 National Comprehensive Cancer Network® (NCCN®), All rights reserved. NCCN Guidelines®, and this illustration may not be reproduced in any form without the express written permission of NCCN.

PLEASE NOTE that use of this NCCN Content is governed by the End-User License Agreement, and you MAY NOT distribute this Content or use it with any artificial intelligence model or tool.
Printed by Galya Basol Kochav on 12/29/2025 12:47:39 PM. Copyright © 2025 National Comprehensive Cancer Network, Inc. All Rights Reserved.

31. Schiffman M, Doorbar J, Wentzensen N, et al. Carcinogenic human papillomavirus infection. Nat Rev Dis Primers 2016;2:16086. Available at: https://www.ncbi.nlm.nih.gov/pubmed/27905473.

32. Network CGAR. Integrated genomic and molecular characterization of cervical cancer. Nature 2017;543:378. Available at:

33. International Collaboration of Epidemiological Studies of Cervical C. Comparison of risk factors for invasive squamous cell carcinoma and adenocarcinoma of the cervix: collaborative reanalysis of individual data on 8,097 women with squamous cell carcinoma and 1,374 women with adenocarcinoma from 12 epidemiological studies. Int J Cancer 2007;120:885–891. Available at: https://www.ncbi.nlm.nih.gov/pubmed/17131323.

34. Dugue PA, Rebolj M, Garred P, Lynge E. Immunosuppression and risk of cervical cancer. Expert Rev Anticancer Ther 2013;13:29–42. Available at: https://www.ncbi.nlm.nih.gov/pubmed/23259425.

35. Cervical Cancer Causes, Risk Factors, and Prevention: Patient Version. PDQ Cancer Information Summaries. Bethesda (MD): National Cancer Institute (US); 2002.

36. Hohn AK, Brambs CE, Hiller GGR, et al. 2020 WHO Classification of Female Genital Tumors. Geburtshilfe Frauenheilkd 2021;81:1145–1153. Available at: https://www.ncbi.nlm.nih.gov/pubmed/34629493.

37. Teoh D, Musa F, Salani R, et al. Diagnosis and Management of Adenocarcinoma in Situ: A Society of Gynecologic Oncology Evidence-Based Review and Recommendations. Obstet Gynecol 2020;135:869–878. Available at: https://www.ncbi.nlm.nih.gov/pubmed/32168211.

38. Sherman ME, Wang SS, Carreon J, Devesa SS. Mortality trends for cervical squamous and adenocarcinoma in the United States. Relation to incidence and survival. Cancer 2005;103:1258–1264. Available at: https://www.ncbi.nlm.nih.gov/pubmed/15693030.

39. Bhatla N, Berek JS, Cuello Fredes M, et al. Revised FIGO staging for carcinoma of the cervix uteri. Int J Gynaecol Obstet 2019;145:129–135. Available at: https://www.ncbi.nlm.nih.gov/pubmed/30656645.

40. Corrigendum to "Revised FIGO staging for carcinoma of the cervix uteri" [Int J Gynecol Obstet 145(2019) 129-135]. Int J Gynaecol Obstet 2019;147:279–280. Available at: https://www.ncbi.nlm.nih.gov/pubmed/31571232.

41. Pecorelli S. Revised FIGO staging for carcinoma of the vulva, cervix, and endometrium. Int J Gynaecol Obstet 2009;105:103–104. Available at: https://www.ncbi.nlm.nih.gov/pubmed/19367689.

42. Schmeler KM, Pareja R, Lopez Blanco A, et al. ConCerv: a prospective trial of conservative surgery for low-risk early-stage cervical cancer. Int J Gynecol Cancer 2021;31:1317–1325. Available at: https://www.ncbi.nlm.nih.gov/pubmed/34493587.

43. Krishnamurti U M-LS, Bell DA, et al. Protocol for the Examination of Specimens from Patients with Primary Carcinoma of the Uterine Cervix. College of American Pathologists 2020. Available at: https://documents.cap.org/protocols/cp-gynecologic-uterinecervix-resection-20-5000.pdf.

44. Rutgers JK, Roma AA, Park KJ, et al. Pattern classification of endocervical adenocarcinoma: reproducibility and review of criteria. Mod Pathol 2016;29:1083–1094. Available at: https://www.ncbi.nlm.nih.gov/pubmed/27255163.

45. Hodgson A, Park KJ, Djordjevic B, et al. International Endocervical Adenocarcinoma Criteria and Classification: Validation and Interobserver Reproducibility. Am J Surg Pathol 2019;43:75–83. Available at: https://www.ncbi.nlm.nih.gov/pubmed/29877920.

46. Marnitz S, Tsunoda AT, Martus P, et al. Surgical versus clinical staging prior to primary chemoradiation in patients with cervical cancer FIGO stages IIB-IVA: oncologic results of a prospective randomized international multicenter (Uterus-11) intergroup study. Int J Gynecol Cancer 2020;30:1855–1861. Available at: https://www.ncbi.nlm.nih.gov/pubmed/33293284.

47. Bentivegna E, Gouy S, Maulard A, et al. Oncological outcomes after fertility-sparing surgery for cervical cancer: a systematic review. Lancet

Version 2.2026 © 2025 National Comprehensive Cancer Network® (NCCN®), All rights reserved. NCCN Guidelines®, and this illustration may not be reproduced in any form without the express written permission of NCCN.

PLEASE NOTE that use of this NCCN Content is governed by the End-User License Agreement, and you MAY NOT distribute this Content or use it with any artificial intelligence model or tool.
Printed by Galya Basol Kochav on 12/29/2025 12:47:39 PM. Copyright © 2025 National Comprehensive Cancer Network, Inc. All Rights Reserved.

Oncol 2016;17:e240–e253. Available at: https://www.ncbi.nlm.nih.gov/pubmed/27299280.

48. Ueki M, Okamoto Y, Misaki O, et al. Conservative therapy for microinvasive carcinoma of the uterine cervix. Gynecol Oncol 1994;53:109–113. Available at: https://www.ncbi.nlm.nih.gov/pubmed/8175008.

49. Al-Kalbani M, McVeigh G, Nagar H, McCluggage WG. Do FIGO stage IA and small (</=2 cm) IB1 cervical adenocarcinomas have a good prognosis and warrant less radical surgery? Int J Gynecol Cancer 2012;22:291–295. Available at: https://www.ncbi.nlm.nih.gov/pubmed/22080884.

50. Webb JC, Key CR, Qualls CR, Smith HO. Population-based study of microinvasive adenocarcinoma of the uterine cervix. Obstet Gynecol 2001;97:701–706. Available at: https://www.ncbi.nlm.nih.gov/pubmed/11339919.

51. Sevin BU, Nadji M, Averette HE, et al. Microinvasive carcinoma of the cervix. Cancer 1992;70:2121–2128. Available at: https://www.ncbi.nlm.nih.gov/pubmed/1394041.

52. Huang LW, Hwang JL. A comparison between loop electrosurgical excision procedure and cold knife conization for treatment of cervical dysplasia: residual disease in a subsequent hysterectomy specimen. Gynecol Oncol 1999;73:12–15. Available at: https://www.ncbi.nlm.nih.gov/pubmed/10094873.

53. Miroshnichenko GG, Parva M, Holtz DO, et al. Interpretability of excisional biopsies of the cervix: cone biopsy and loop excision. J Low Genit Tract Dis 2009;13:10–12. Available at: https://www.ncbi.nlm.nih.gov/pubmed/19098600.

54. Greenspan DL, Faubion M, Coonrod DV, et al. Compliance after loop electrosurgical excision procedure or cold knife cone biopsy. Obstet Gynecol 2007;110:675–680. Available at: https://www.ncbi.nlm.nih.gov/pubmed/17766617.

55. Fanning J, Padratzik J. Cold knife conization vs. LEEP. Are they the same procedure? J Reprod Med 2002;47:33–35. Available at: https://www.ncbi.nlm.nih.gov/pubmed/11838307.

56. Simmons JR, Anderson L, Hernandez E, Heller PB. Evaluating cervical neoplasia. LEEP as an alternative to cold knife conization. J Reprod Med 1998;43:1007–1013. Available at: https://www.ncbi.nlm.nih.gov/pubmed/9883402.

57. Kim MK, Kim MA, Kim JW, et al. Loop electrosurgical excision procedure findings for identification of patients with early-stage cervical cancer suitable for less radical surgery. Int J Gynecol Cancer 2012;22:1214–1219. Available at: https://www.ncbi.nlm.nih.gov/pubmed/22801033.

58. Bouchard-Fortier G, Reade CJ, Covens A. Non-radical surgery for small early-stage cervical cancer. Is it time? Gynecol Oncol 2014;132:624–627. Available at: https://www.ncbi.nlm.nih.gov/pubmed/24480237.

59. Kato T, Takashima A, Kasamatsu T, et al. Clinical tumor diameter and prognosis of patients with FIGO stage IB1 cervical cancer (JCOG0806-A). Gynecol Oncol 2015;137:34–39. Available at: https://www.ncbi.nlm.nih.gov/pubmed/25662625.

60. Covens A, Huang HQ, Monk BJ, et al. Evaluation of efficacy and fertility after nonradical surgical therapy (extra fascial hysterectomy or cone biopsy, with pelvic lymphadenectomy) for stage IA1, IA2, and IB1 cervical cancer (GOG-0278). Gynecol Oncol 2025;195:59–65. Available at: https://www.ncbi.nlm.nih.gov/pubmed/40056831.

61. Cao DY, Yang JX, Wu XH, et al. Comparisons of vaginal and abdominal radical trachelectomy for early-stage cervical cancer: preliminary results of a multi-center research in China. Br J Cancer 2013;109:2778–2782. Available at: https://www.ncbi.nlm.nih.gov/pubmed/24169350.

62. Plante M, Gregoire J, Renaud MC, Roy M. The vaginal radical trachelectomy: an update of a series of 125 cases and 106 pregnancies.

Version 2.2026 © 2025 National Comprehensive Cancer Network® (NCCN®), All rights reserved. NCCN Guidelines®, and this illustration may not be reproduced in any form without the express written permission of NCCN.

PLEASE NOTE that use of this NCCN Content is governed by the End-User License Agreement, and you MAY NOT distribute this Content or use it with any artificial intelligence model or tool.
Printed by Galya Basol Kochav on 12/29/2025 12:47:39 PM. Copyright © 2025 National Comprehensive Cancer Network, Inc. All Rights Reserved.

Gynecol Oncol 2011;121:290–297. Available at: https://www.ncbi.nlm.nih.gov/pubmed/21255824.

63. Abu-Rustum NR, Sonoda Y, Black D, et al. Fertility-sparing radical abdominal trachelectomy for cervical carcinoma: technique and review of the literature. Gynecol Oncol 2006;103:807–813. Available at: https://www.ncbi.nlm.nih.gov/pubmed/16837027.

64. Dargent D, Martin X, Sacchetoni A, Mathevet P. Laparoscopic vaginal radical trachelectomy: a treatment to preserve the fertility of cervical carcinoma patients. Cancer 2000;88:1877–1882. Available at: https://www.ncbi.nlm.nih.gov/pubmed/10760765.

65. Diaz JP, Sonoda Y, Leitao MM, et al. Oncologic outcome of fertility-sparing radical trachelectomy versus radical hysterectomy for stage IB1 cervical carcinoma. Gynecol Oncol 2008;111:255–260. Available at: https://www.ncbi.nlm.nih.gov/pubmed/18755500.

66. Abu-Rustum NR, Tal MN, DeLair D, et al. Radical abdominal trachelectomy for stage IB1 cervical cancer at 15-week gestation. Gynecol Oncol 2010;116:151–152. Available at: https://www.ncbi.nlm.nih.gov/pubmed/19878979.

67. Ramirez PT, Pareja R, Rendon GJ, et al. Management of low-risk early-stage cervical cancer: should conization, simple trachelectomy, or simple hysterectomy replace radical surgery as the new standard of care? Gynecol Oncol 2014;132:254–259. Available at: https://www.ncbi.nlm.nih.gov/pubmed/24041877.

68. Einstein MH, Park KJ, Sonoda Y, et al. Radical vaginal versus abdominal trachelectomy for stage IB1 cervical cancer: a comparison of surgical and pathologic outcomes. Gynecol Oncol 2009;112:73–77. Available at: https://www.ncbi.nlm.nih.gov/pubmed/18973933.

69. Wethington SL, Cibula D, Duska LR, et al. An international series on abdominal radical trachelectomy: 101 patients and 28 pregnancies. Int J Gynecol Cancer 2012;22:1251–1257. Available at: https://www.ncbi.nlm.nih.gov/pubmed/22914213.

70. Abu-Rustum NR, Sonoda Y. Fertility-sparing surgery in early-stage cervical cancer: indications and applications. J Natl Compr Canc Netw 2010;8:1435–1438. Available at: https://www.ncbi.nlm.nih.gov/pubmed/21147906.

71. Beiner ME, Covens A. Surgery insight: radical vaginal trachelectomy as a method of fertility preservation for cervical cancer. Nat Clin Pract Oncol 2007;4:353–361. Available at: https://www.ncbi.nlm.nih.gov/pubmed/17534391.

72. Pareja R, Rendon GJ, Sanz-Lomana CM, et al. Surgical, oncological, and obstetrical outcomes after abdominal radical trachelectomy - a systematic literature review. Gynecol Oncol 2013;131:77–82. Available at: https://www.ncbi.nlm.nih.gov/pubmed/23769758.

73. Lintner B, Saso S, Tarnai L, et al. Use of abdominal radical trachelectomy to treat cervical cancer greater than 2 cm in diameter. Int J Gynecol Cancer 2013;23:1065–1070. Available at: https://www.ncbi.nlm.nih.gov/pubmed/23722476.

74. Wethington SL, Sonoda Y, Park KJ, et al. Expanding the indications for radical trachelectomy: a report on 29 patients with stage IB1 tumors measuring 2 to 4 centimeters. Int J Gynecol Cancer 2013;23:1092–1098. Available at: https://www.ncbi.nlm.nih.gov/pubmed/23714706.

75. Lanowska M, Mangler M, Speiser D, et al. Radical vaginal trachelectomy after laparoscopic staging and neoadjuvant chemotherapy in women with early-stage cervical cancer over 2 cm: oncologic, fertility, and neonatal outcome in a series of 20 patients. Int J Gynecol Cancer 2014;24:586–593. Available at: https://www.ncbi.nlm.nih.gov/pubmed/24469326.

76. Choi CW, Cho CK, Yoo SY, et al. Image-guided stereotactic body radiation therapy in patients with isolated para-aortic lymph node metastases from uterine cervical and corpus cancer. Int J Radiat Oncol Biol Phys 2009;74:147–153. Available at: https://www.ncbi.nlm.nih.gov/pubmed/18990511.

77. Shepherd JH, Spencer C, Herod J, Ind TE. Radical vaginal trachelectomy as a fertility-sparing procedure in women with early-stage

Version 2.2026 © 2025 National Comprehensive Cancer Network® (NCCN®), All rights reserved. NCCN Guidelines®, and this illustration may not be reproduced in any form without the express written permission of NCCN.

PLEASE NOTE that use of this NCCN Content is governed by the End-User License Agreement, and you MAY NOT distribute this Content or use it with any artificial intelligence model or tool.
Printed by Galya Basol Kochav on 12/29/2025 12:47:39 PM. Copyright © 2025 National Comprehensive Cancer Network, Inc. All Rights Reserved.

cervical cancer-cumulative pregnancy rate in a series of 123 women. BJOG 2006;113:719–724. Available at: https://www.ncbi.nlm.nih.gov/pubmed/16709216.

78. Park JY, Kim DY, Suh DS, et al. Reproductive outcomes after laparoscopic radical trachelectomy for early-stage cervical cancer. J Gynecol Oncol 2014;25:9–13. Available at: https://www.ncbi.nlm.nih.gov/pubmed/24459575.

79. Gizzo S, Ancona E, Saccardi C, et al. Radical trachelectomy: the first step of fertility preservation in young women with cervical cancer (Review). Oncol Rep 2013;30:2545–2554. Available at: https://www.ncbi.nlm.nih.gov/pubmed/24065029.

80. Viswanathan AN, Deavers MT, Jhingran A, et al. Small cell neuroendocrine carcinoma of the cervix: outcome and patterns of recurrence. Gynecol Oncol 2004;93:27–33. Available at: https://www.ncbi.nlm.nih.gov/pubmed/15047210.

81. Young RH, Clement PB. Endocervical adenocarcinoma and its variants: their morphology and differential diagnosis. Histopathology 2002;41:185–207. Available at: https://www.ncbi.nlm.nih.gov/pubmed/12207781.

82. Cibula D, Abu-Rustum NR, Benedetti-Panici P, et al. New classification system of radical hysterectomy: emphasis on a three-dimensional anatomic template for parametrial resection. Gynecol Oncol 2011;122:264–268. Available at: https://www.ncbi.nlm.nih.gov/pubmed/21592548.

83. Querleu D, Morrow CP. Classification of radical hysterectomy. Lancet Oncol 2008;9:297–303. Available at: https://www.ncbi.nlm.nih.gov/pubmed/18308255.

84. Piver MS, Rutledge F, Smith JP. Five classes of extended hysterectomy for women with cervical cancer. Obstet Gynecol 1974;44:265–272. Available at: https://www.ncbi.nlm.nih.gov/pubmed/4417035.

85. Chi DS, Abu-Rustum NR, Plante M, Roy M. Cancer of the cervix. In: Rock JA, Jones HW, eds, eds. TeLinde's Operative Gynecology, 10th ed. Philadelphia: Lippincott Williams and Wilkins; 2008:1227.

86. Whitney CW, Spirtos NM. Gynecologic Oncology Group Surgical Procedures Manual. Philadelphia: Gynecologic Oncology Group; 2009. Available at: https://gogmember.gog.org/manuals/pdf/surgman.pdf. Accessed April 18, 2014.

87. Sardain H, Lavoue V, Redpath M, et al. Curative pelvic exenteration for recurrent cervical carcinoma in the era of concurrent chemotherapy and radiation therapy. A systematic review. Eur J Surg Oncol 2015;41:975–985. Available at: https://www.ncbi.nlm.nih.gov/pubmed/25922209.

88. Chiantera V, Rossi M, De Iaco P, et al. Morbidity after pelvic exenteration for gynecological malignancies: a retrospective multicentric study of 230 patients. Int J Gynecol Cancer 2014;24:156–164. Available at: https://www.ncbi.nlm.nih.gov/pubmed/24362721.

89. Cormier B, Diaz JP, Shih K, et al. Establishing a sentinel lymph node mapping algorithm for the treatment of early cervical cancer. Gynecol Oncol 2011;122:275–280. Available at: https://www.ncbi.nlm.nih.gov/pubmed/21570713.

90. Lecuru F, Mathevet P, Querleu D, et al. Bilateral negative sentinel nodes accurately predict absence of lymph node metastasis in early cervical cancer: results of the SENTICOL study. J Clin Oncol 2011;29:1686–1691. Available at: https://www.ncbi.nlm.nih.gov/pubmed/21444878.

91. Altgassen C, Hertel H, Brandstadt A, et al. Multicenter validation study of the sentinel lymph node concept in cervical cancer: AGO Study Group. J Clin Oncol 2008;26:2943–2951. Available at: https://www.ncbi.nlm.nih.gov/pubmed/18565880.

92. Bats AS, Buenerd A, Querleu D, et al. Diagnostic value of intraoperative examination of sentinel lymph node in early cervical cancer: a prospective, multicenter study. Gynecol Oncol 2011;123:230–235. Available at: https://www.ncbi.nlm.nih.gov/pubmed/21893335.

Version 2.2026 © 2025 National Comprehensive Cancer Network® (NCCN®), All rights reserved. NCCN Guidelines®, and this illustration may not be reproduced in any form without the express written permission of NCCN.

PLEASE NOTE that use of this NCCN Content is governed by the End-User License Agreement, and you MAY NOT distribute this Content or use it with any artificial intelligence model or tool.
Printed by Galya Basol Kochav on 12/29/2025 12:47:39 PM. Copyright © 2025 National Comprehensive Cancer Network, Inc. All Rights Reserved.

93. Bats AS, Mathevet P, Buenerd A, et al. The sentinel node technique detects unexpected drainage pathways and allows nodal ultrastaging in early cervical cancer: insights from the multicenter prospective SENTICOL study. Ann Surg Oncol 2013;20:413–422. Available at: https://www.ncbi.nlm.nih.gov/pubmed/22911367.

94. Cibula D, Abu-Rustum NR, Dusek L, et al. Bilateral ultrastaging of sentinel lymph node in cervical cancer: Lowering the false-negative rate and improving the detection of micrometastasis. Gynecol Oncol 2012;127:462–466. Available at: https://www.ncbi.nlm.nih.gov/pubmed/22943880.

95. Cibula D, Abu-Rustum NR, Dusek L, et al. Prognostic significance of low volume sentinel lymph node disease in early-stage cervical cancer. Gynecol Oncol 2012;124:496–501. Available at: https://www.ncbi.nlm.nih.gov/pubmed/22120175.

96. Fader AN, Edwards RP, Cost M, et al. Sentinel lymph node biopsy in early-stage cervical cancer: utility of intraoperative versus postoperative assessment. Gynecol Oncol 2008;111:13–17. Available at: https://www.ncbi.nlm.nih.gov/pubmed/18684499.

97. Lecuru F, Bats A, Mathevet P, et al. Impact of sentinel lymph node biopsy on staging of early cervical cancer: Results of a prospective, multicenter study [abstract]. J Clin Oncol 2009;27(Suppl 18):Abstract CRA5506. Available at: http://meeting.ascopubs.org/cgi/content/abstract/27/18S/CRA5506.

98. Slama J, Dundr P, Dusek L, Cibula D. High false negative rate of frozen section examination of sentinel lymph nodes in patients with cervical cancer. Gynecol Oncol 2013;129:384–388. Available at: https://www.ncbi.nlm.nih.gov/pubmed/23395889.

99. van de Lande J, Torrenga B, Raijmakers PG, et al. Sentinel lymph node detection in early stage uterine cervix carcinoma: a systematic review. Gynecol Oncol 2007;106:604–613. Available at: https://www.ncbi.nlm.nih.gov/pubmed/17628644.

100. Andikyan V, Khoury-Collado F, Denesopolis J, et al. Cervical conization and sentinel lymph node mapping in the treatment of stage I cervical cancer: is less enough? Int J Gynecol Cancer 2014;24:113–117. Available at: https://www.ncbi.nlm.nih.gov/pubmed/24335661.

101. Wu Y, Li Z, Wu H, Yu J. Sentinel lymph node biopsy in cervical cancer: A meta-analysis. Mol Clin Oncol 2013;1:1025–1030. Available at: https://www.ncbi.nlm.nih.gov/pubmed/24649288.

102. Kadkhodayan S, Hasanzadeh M, Treglia G, et al. Sentinel node biopsy for lymph nodal staging of uterine cervix cancer: a systematic review and meta-analysis of the pertinent literature. Eur J Surg Oncol 2015;41:1–20. Available at: https://www.ncbi.nlm.nih.gov/pubmed/25454828.

103. Ruscito I, Gasparri ML, Braicu EI, et al. Sentinel Node Mapping in Cervical and Endometrial Cancer: Indocyanine Green Versus Other Conventional Dyes-A Meta-Analysis. Ann Surg Oncol 2016;23:3749–3756. Available at: https://www.ncbi.nlm.nih.gov/pubmed/27160526.

104. Frumovitz M, Plante M, Lee PS, et al. The FILM Trial: A randomized phase III multicenter study assessing near infrared fluorescence in the identification of sentinel lymph nodes (SLN). Gynecologic Oncology 2018;149:7. Available at: https://doi.org/10.1016/j.ygyno.2018.04.023.

105. Eiriksson LR, Covens A. Sentinel lymph node mapping in cervical cancer: the future? BJOG 2012;119:129–133. Available at: https://www.ncbi.nlm.nih.gov/pubmed/21917113.

106. Bats AS, Frati A, Mathevet P, et al. Contribution of lymphoscintigraphy to intraoperative sentinel lymph node detection in early cervical cancer: Analysis of the prospective multicenter SENTICOL cohort. Gynecol Oncol 2015;137:264–269. Available at: https://www.ncbi.nlm.nih.gov/pubmed/25727652.

107. Mathevet P, Lecuru F, Uzan C, et al. Sentinel lymph node biopsy and morbidity outcomes in early cervical cancer: Results of a multicentre randomised trial (SENTICOL-2). Eur J Cancer 2021;148:307–315. Available at: https://www.ncbi.nlm.nih.gov/pubmed/33773275.

108. Darlin L, Persson J, Bossmar T, et al. The sentinel node concept in early cervical cancer performs well in tumors smaller than 2 cm. Gynecol

Version 2.2026 © 2025 National Comprehensive Cancer Network® (NCCN®), All rights reserved. NCCN Guidelines®, and this illustration may not be reproduced in any form without the express written permission of NCCN.

PLEASE NOTE that use of this NCCN Content is governed by the End-User License Agreement, and you MAY NOT distribute this Content or use it with any artificial intelligence model or tool.
Printed by Galya Basol Kochav on 12/29/2025 12:47:39 PM. Copyright © 2025 National Comprehensive Cancer Network, Inc. All Rights Reserved.

Oncol 2010;117:266–269. Available at: https://www.ncbi.nlm.nih.gov/pubmed/20167355.

109. Cibula D, Kocian R, Plaikner A, et al. Sentinel lymph node mapping and intraoperative assessment in a prospective, international, multicentre, observational trial of patients with cervical cancer: The SENTIX trial. Eur J Cancer 2020;137:69–80. Available at: https://www.ncbi.nlm.nih.gov/pubmed/32750501.

110. Kocian R, Kohler C, Bajsova S, et al. Sentinel lymph node pathological ultrastaging: Final outcome of the Sentix prospective international study in patients with early-stage cervical cancer. Gynecol Oncol 2024;188:83–89. Available at: https://www.ncbi.nlm.nih.gov/pubmed/38941963.

111. Tomao F, Maruccio M, Preti EP, et al. Conization in Early Stage Cervical Cancer: Pattern of Recurrence in a 10-Year Single-Institution Experience. Int J Gynecol Cancer 2017;27:1001–1008. Available at: https://www.ncbi.nlm.nih.gov/pubmed/28486242.

112. Sakuragi N, Satoh C, Takeda N, et al. Incidence and distribution pattern of pelvic and paraaortic lymph node metastasis in patients with Stages IB, IIA, and IIB cervical carcinoma treated with radical hysterectomy. Cancer 1999;85:1547–1554. Available at: https://www.ncbi.nlm.nih.gov/pubmed/10193945.

113. Huang H, Liu J, Li Y, et al. Metastasis to deep obturator and para-aortic lymph nodes in 649 patients with cervical carcinoma. Eur J Surg Oncol 2011;37:978–983. Available at: https://www.ncbi.nlm.nih.gov/pubmed/21907530.

114. Gold MA, Tian C, Whitney CW, et al. Surgical versus radiographic determination of para-aortic lymph node metastases before chemoradiation for locally advanced cervical carcinoma: a Gynecologic Oncology Group Study. Cancer 2008;112:1954–1963. Available at: https://www.ncbi.nlm.nih.gov/pubmed/18338811.

115. Gouy S, Morice P, Narducci F, et al. Prospective multicenter study evaluating the survival of patients with locally advanced cervical cancer undergoing laparoscopic para-aortic lymphadenectomy before chemoradiotherapy in the era of positron emission tomography imaging. J Clin Oncol 2013;31:3026–3033. Available at: https://www.ncbi.nlm.nih.gov/pubmed/23857967.

116. Martinez A, Lecuru F, Bizzarri N, et al. PARa-aOrtic LymphAdenectomy in locally advanced cervical cancer (PAROLA trial): a GINECO, ENGOT, and GCIG study. Int J Gynecol Cancer 2023;33:293–298. Available at: https://www.ncbi.nlm.nih.gov/pubmed/36717163.

117. Chen Y, Xu H, Li Y, et al. The outcome of laparoscopic radical hysterectomy and lymphadenectomy for cervical cancer: a prospective analysis of 295 patients. Ann Surg Oncol 2008;15:2847–2855. Available at: https://www.ncbi.nlm.nih.gov/pubmed/18649105.

118. Puntambekar SP, Palep RJ, Puntambekar SS, et al. Laparoscopic total radical hysterectomy by the Pune technique: our experience of 248 cases. J Minim Invasive Gynecol 2007;14:682–689. Available at: https://www.ncbi.nlm.nih.gov/pubmed/17980327.

119. Nam JH, Park JY, Kim DY, et al. Laparoscopic versus open radical hysterectomy in early-stage cervical cancer: long-term survival outcomes in a matched cohort study. Ann Oncol 2012;23:903–911. Available at: https://www.ncbi.nlm.nih.gov/pubmed/21841155.

120. Wang YZ, Deng L, Xu HC, et al. Laparoscopy versus laparotomy for the management of early stage cervical cancer. BMC Cancer 2015;15:928. Available at: https://www.ncbi.nlm.nih.gov/pubmed/26596955.

121. Sert BM, Boggess JF, Ahmad S, et al. Robot-assisted versus open radical hysterectomy: A multi-institutional experience for early-stage cervical cancer. Eur J Surg Oncol 2016;42:513–522. Available at: https://www.ncbi.nlm.nih.gov/pubmed/26843445.

122. Mendivil AA, Rettenmaier MA, Abaid LN, et al. Survival rate comparisons amongst cervical cancer patients treated with an open, robotic-assisted or laparoscopic radical hysterectomy: A five year experience. Surg Oncol 2016;25:66–71. Available at: https://www.ncbi.nlm.nih.gov/pubmed/26409687.

Version 2.2026 © 2025 National Comprehensive Cancer Network® (NCCN®), All rights reserved. NCCN Guidelines®, and this illustration may not be reproduced in any form without the express written permission of NCCN.

PLEASE NOTE that use of this NCCN Content is governed by the End-User License Agreement, and you MAY NOT distribute this Content or use it with any artificial intelligence model or tool.
Printed by Galya Basol Kochav on 12/29/2025 12:47:39 PM. Copyright © 2025 National Comprehensive Cancer Network, Inc. All Rights Reserved.

123. Park DA, Yun JE, Kim SW, Lee SH. Surgical and clinical safety and effectiveness of robot-assisted laparoscopic hysterectomy compared to conventional laparoscopy and laparotomy for cervical cancer: A systematic review and meta-analysis. Eur J Surg Oncol 2017;43:994–1002. Available at: https://www.ncbi.nlm.nih.gov/pubmed/27546015.

124. Shazly SA, Murad MH, Dowdy SC, et al. Robotic radical hysterectomy in early stage cervical cancer: A systematic review and meta-analysis. Gynecol Oncol 2015;138:457–471. Available at: https://www.ncbi.nlm.nih.gov/pubmed/26056752.

125. Ramirez PT, Frumovitz M, Pareja R, et al. Phase III randomized trial of laparoscopic or robotic versus abdominal radical hysterectomy in patients with early-stage cervical cancer: LACC Trial. Gynecologic Oncology 2018;149:245. Available at: https://doi.org/10.1016/j.ygyno.2018.04.552.

126. Melamed, Chen L, Keating NL, et al. Comparative effectiveness of minimally-invasive staging surgery in women with early-stage cervical cancer. Gynecologic Oncology 2018;149:245–246. Available at: https://doi.org/10.1016/j.ygyno.2018.04.553.

127. Margul DJ, Yang J, Seagle BL, et al. Outcomes and costs of open, robotic, and laparoscopic radical hysterectomy for stage IB1 cervical cancer. Journal of Clinical Oncology 2018;36:5502–5502. Available at: http://ascopubs.org/doi/abs/10.1200/JCO.2018.36.15_suppl.5502.

128. Nitecki R, Ramirez PT, Frumovitz M, et al. Survival After Minimally Invasive vs Open Radical Hysterectomy for Early-Stage Cervical Cancer: A Systematic Review and Meta-analysis. JAMA Oncol 2020;6:1019–1027. Available at: https://www.ncbi.nlm.nih.gov/pubmed/32525511.

129. Nevis IF, Vali B, Higgins C, et al. Robot-assisted hysterectomy for endometrial and cervical cancers: a systematic review. J Robot Surg 2017;11:1–16. Available at: https://www.ncbi.nlm.nih.gov/pubmed/27424111.

130. Lowe MP, Chamberlain DH, Kamelle SA, et al. A multi-institutional experience with robotic-assisted radical hysterectomy for early stage cervical cancer. Gynecol Oncol 2009;113:191–194. Available at: https://www.ncbi.nlm.nih.gov/pubmed/19249082.

131. Nezhat FR, Datta MS, Liu C, et al. Robotic radical hysterectomy versus total laparoscopic radical hysterectomy with pelvic lymphadenectomy for treatment of early cervical cancer. JSLS 2008;12:227–237. Available at: https://www.ncbi.nlm.nih.gov/pubmed/18765043.

132. Cantrell LA, Mendivil A, Gehrig PA, Boggess JF. Survival outcomes for women undergoing type III robotic radical hysterectomy for cervical cancer: a 3-year experience. Gynecol Oncol 2010;117:260–265. Available at: https://www.ncbi.nlm.nih.gov/pubmed/20153886.

133. Benedet JL, Bender H, Jones H, 3rd, et al. FIGO staging classifications and clinical practice guidelines in the management of gynecologic cancers. FIGO Committee on Gynecologic Oncology. Int J Gynaecol Obstet 2000;70:209–262. Available at: https://www.ncbi.nlm.nih.gov/pubmed/11041682.

134. Zaino RJ. Glandular lesions of the uterine cervix. Mod Pathol 2000;13:261–274. Available at: https://www.ncbi.nlm.nih.gov/pubmed/10757337.

135. Zaino RJ. Symposium part I: adenocarcinoma in situ, glandular dysplasia, and early invasive adenocarcinoma of the uterine cervix. Int J Gynecol Pathol 2002;21:314–326. Available at: https://www.ncbi.nlm.nih.gov/pubmed/12352181.

136. Diaz De Vivar A, Roma AA, Park KJ, et al. Invasive endocervical adenocarcinoma: proposal for a new pattern-based classification system with significant clinical implications: a multi-institutional study. Int J Gynecol Pathol 2013;32:592–601. Available at: https://www.ncbi.nlm.nih.gov/pubmed/24071876.

137. Spaans VM, Scheunhage DA, Barzaghi B, et al. Independent validation of the prognostic significance of invasion patterns in endocervical adenocarcinoma: Pattern A predicts excellent survival. Gynecol Oncol 2018;151:196–201. Available at: https://www.ncbi.nlm.nih.gov/pubmed/30262404.

Version 2.2026 © 2025 National Comprehensive Cancer Network® (NCCN®), All rights reserved. NCCN Guidelines®, and this illustration may not be reproduced in any form without the express written permission of NCCN.

PLEASE NOTE that use of this NCCN Content is governed by the End-User License Agreement, and you MAY NOT distribute this Content or use it with any artificial intelligence model or tool.
Printed by Galya Basol Kochav on 12/29/2025 12:47:39 PM. Copyright © 2025 National Comprehensive Cancer Network, Inc. All Rights Reserved.

138. Stolnicu S, Barsan I, Hoang L, et al. Stromal invasion pattern identifies patients at lowest risk of lymph node metastasis in HPV-associated endocervical adenocarcinomas, but is irrelevant in adenocarcinomas unassociated with HPV. Gynecol Oncol 2018;150:56–60. Available at: https://www.ncbi.nlm.nih.gov/pubmed/29859673.

139. Stolnicu S, Hoang L, Almadani N, et al. Clinical correlation of lymphovascular invasion and Silva pattern of invasion in early-stage endocervical adenocarcinoma: proposed binary Silva classification system. Pathology 2022;54:548–554. Available at: https://www.ncbi.nlm.nih.gov/pubmed/35501168.

140. Roma AA, Mistretta TA, Diaz De Vivar A, et al. New pattern-based personalized risk stratification system for endocervical adenocarcinoma with important clinical implications and surgical outcome. Gynecol Oncol 2016;141:36–42. Available at: https://www.ncbi.nlm.nih.gov/pubmed/27016227.

141. Sedlis A, Bundy BN, Rotman MZ, et al. A randomized trial of pelvic radiation therapy versus no further therapy in selected patients with stage IB carcinoma of the cervix after radical hysterectomy and pelvic lymphadenectomy: A Gynecologic Oncology Group Study. Gynecol Oncol 1999;73:177–183. Available at: https://www.ncbi.nlm.nih.gov/pubmed/10329031.

142. Ryu SY, Kim MH, Nam BH, et al. Intermediate-risk grouping of cervical cancer patients treated with radical hysterectomy: a Korean Gynecologic Oncology Group study. Br J Cancer 2014;110:278–285. Available at: https://www.ncbi.nlm.nih.gov/pubmed/24357798.

143. Noh JM, Park W, Kim YS, et al. Comparison of clinical outcomes of adenocarcinoma and adenosquamous carcinoma in uterine cervical cancer patients receiving surgical resection followed by radiotherapy: a multicenter retrospective study (KROG 13-10). Gynecol Oncol 2014;132:618–623. Available at: https://www.ncbi.nlm.nih.gov/pubmed/24486605.

144. Diaz ES, Aoyama C, Baquing MA, et al. Predictors of residual carcinoma or carcinoma-in-situ at hysterectomy following cervical conization with positive margins. Gynecol Oncol 2014;132:76–80. Available at: https://www.ncbi.nlm.nih.gov/pubmed/24262876.

145. Estape RE, Angioli R, Madrigal M, et al. Close vaginal margins as a prognostic factor after radical hysterectomy. Gynecol Oncol 1998;68:229–232. Available at: https://www.ncbi.nlm.nih.gov/pubmed/9570971.

146. Levinson K, Beavis AL, Purdy C, et al. Beyond Sedlis-A novel histology-specific nomogram for predicting cervical cancer recurrence risk: An NRG/GOG ancillary analysis. Gynecol Oncol 2021;162:532–538. Available at: https://www.ncbi.nlm.nih.gov/pubmed/34217544.

147. National Cancer Institute. Biomarker Testing for Cancer Treatment. . 2021. Available at: https://www.cancer.gov/about-cancer/treatment/types/biomarker-testing-cancer-treatment. . Accessed May 2.

148. Louie AD, Huntington K, Carlsen L, et al. Integrating Molecular Biomarker Inputs Into Development and Use of Clinical Cancer Therapeutics. Front Pharmacol 2021;12:747194. Available at: https://www.ncbi.nlm.nih.gov/pubmed/34737704.

149. Colombo N, Dubot C, Lorusso D, et al. Pembrolizumab for Persistent, Recurrent, or Metastatic Cervical Cancer. N Engl J Med 2021;385:1856–1867. Available at: https://www.ncbi.nlm.nih.gov/pubmed/34534429.

150. Chung HC, Ros W, Delord JP, et al. Efficacy and Safety of Pembrolizumab in Previously Treated Advanced Cervical Cancer: Results From the Phase II KEYNOTE-158 Study. J Clin Oncol 2019;37:1470–1478. Available at: https://www.ncbi.nlm.nih.gov/pubmed/30943124.

151. Naumann RW, Hollebecque A, Meyer T, et al. Safety and Efficacy of Nivolumab Monotherapy in Recurrent or Metastatic Cervical, Vaginal, or Vulvar Carcinoma: Results From the Phase I/II CheckMate 358 Trial. J Clin Oncol 2019;37:2825–2834. Available at: https://www.ncbi.nlm.nih.gov/pubmed/31487218.

152. Yoshimoto D, Taguchi A, Tanikawa M, et al. Recurrent cervical cancer with PD-L1 amplification treated with nivolumab: A case enrolled in

Version 2.2026 © 2025 National Comprehensive Cancer Network® (NCCN®), All rights reserved. NCCN Guidelines®, and this illustration may not be reproduced in any form without the express written permission of NCCN.

PLEASE NOTE that use of this NCCN Content is governed by the End-User License Agreement, and you MAY NOT distribute this Content or use it with any artificial intelligence model or tool.
Printed by Galya Basol Kochav on 12/29/2025 12:47:39 PM. Copyright © 2025 National Comprehensive Cancer Network, Inc. All Rights Reserved.

the BELIEVE trial. J Obstet Gynaecol Res 2022;48:2010–2014. Available at: https://www.ncbi.nlm.nih.gov/pubmed/35373441.

153. Santin AD, Deng W, Frumovitz M, et al. Phase II evaluation of nivolumab in the treatment of persistent or recurrent cervical cancer (NCT02257528/NRG-GY002). Gynecol Oncol 2020;157:161–166. Available at: https://www.ncbi.nlm.nih.gov/pubmed/31924334.

154. Vergote I, Van Nieuwenhuysen E, O'Cearbhaill RE, et al. Tisotumab Vedotin in Combination With Carboplatin, Pembrolizumab, or Bevacizumab in Recurrent or Metastatic Cervical Cancer: Results From the innovaTV 205/GOG-3024/ENGOT-cx8 Study. J Clin Oncol 2023;41:5536–5549. Available at: https://www.ncbi.nlm.nih.gov/pubmed/37651655.

155. Marabelle A, Le DT, Ascierto PA, et al. Efficacy of Pembrolizumab in Patients With Noncolorectal High Microsatellite Instability/Mismatch Repair-Deficient Cancer: Results From the Phase II KEYNOTE-158 Study. J Clin Oncol 2020;38:1–10. Available at: https://www.ncbi.nlm.nih.gov/pubmed/31682550.

156. Marabelle A, Fakih M, Lopez J, et al. Association of tumour mutational burden with outcomes in patients with advanced solid tumours treated with pembrolizumab: prospective biomarker analysis of the multicohort, open-label, phase 2 KEYNOTE-158 study. Lancet Oncol 2020;21:1353–1365. Available at: https://www.ncbi.nlm.nih.gov/pubmed/32919526.

157. Doebele RC, Drilon A, Paz-Ares L, et al. Entrectinib in patients with advanced or metastatic NTRK fusion-positive solid tumours: integrated analysis of three phase 1-2 trials. Lancet Oncol 2020;21:271–282. Available at: https://www.ncbi.nlm.nih.gov/pubmed/31838007.

158. Demetri GD, De Braud F, Drilon A, et al. Updated Integrated Analysis of the Efficacy and Safety of Entrectinib in Patients With NTRK Fusion-Positive Solid Tumors. Clin Cancer Res 2022;28:1302–1312. Available at: https://www.ncbi.nlm.nih.gov/pubmed/35144967.

159. Drilon A, Laetsch TW, Kummar S, et al. Efficacy of Larotrectinib in TRK Fusion-Positive Cancers in Adults and Children. N Engl J Med 2018;378:731–739. Available at: https://www.ncbi.nlm.nih.gov/pubmed/29466156.

160. Hong DS, DuBois SG, Kummar S, et al. Larotrectinib in patients with TRK fusion-positive solid tumours: a pooled analysis of three phase 1/2 clinical trials. Lancet Oncol 2020;21:531–540. Available at: https://www.ncbi.nlm.nih.gov/pubmed/32105622.

161. Marcus L, Donoghue M, Aungst S, et al. FDA Approval Summary: Entrectinib for the Treatment of NTRK gene Fusion Solid Tumors. Clin Cancer Res 2021;27:928–932. Available at: https://www.ncbi.nlm.nih.gov/pubmed/32967940.

162. Scott LJ. Larotrectinib: First Global Approval. Drugs 2019;79:201–206. Available at: https://www.ncbi.nlm.nih.gov/pubmed/30635837.

163. Solomon BJ, Drilon A, Lin JJ, et al. 1372P Repotrectinib in patients (pts) with NTRK fusion-positive (NTRK+) advanced solid tumors, including NSCLC: Update from the phase I/II TRIDENT-1 trial. Annals of Oncology 2023;34:S787–S788. Available at:

164. Yan M, Schwaederle M, Arguello D, et al. HER2 expression status in diverse cancers: review of results from 37,992 patients. Cancer Metastasis Rev 2015;34:157–164. Available at: https://www.ncbi.nlm.nih.gov/pubmed/25712293.

165. Chavez-Blanco A, Perez-Sanchez V, Gonzalez-Fierro A, et al. HER2 expression in cervical cancer as a potential therapeutic target. BMC Cancer 2004;4:59. Available at: https://www.ncbi.nlm.nih.gov/pubmed/15341668.

166. Itkin B, Garcia A, Straminsky S, et al. Prevalence of HER2 overexpression and amplification in cervical cancer: A systematic review and meta-analysis. PLoS One 2021;16:e0257976. Available at: https://www.ncbi.nlm.nih.gov/pubmed/34591928.

167. Cai ZL, Yang HT, Huang T, et al. Efficacy and safety of trastuzumab deruxtecan in patients with solid tumors: a systematic review and meta-analysis of 3 randomized controlled trials. Am J Cancer Res

Version 2.2026 © 2025 National Comprehensive Cancer Network® (NCCN®), All rights reserved. NCCN Guidelines®, and this illustration may not be reproduced in any form without the express written permission of NCCN.

PLEASE NOTE that use of this NCCN Content is governed by the End-User License Agreement, and you MAY NOT distribute this Content or use it with any artificial intelligence model or tool.
Printed by Galya Basol Kochav on 12/29/2025 12:47:39 PM. Copyright © 2025 National Comprehensive Cancer Network, Inc. All Rights Reserved.

2023;13:3266–3274. Available at: https://www.ncbi.nlm.nih.gov/pubmed/37693138.

168. Meric-Bernstam F, Makker V, Oaknin A, et al. Efficacy and Safety of Trastuzumab Deruxtecan in Patients With HER2-Expressing Solid Tumors: Primary Results From the DESTINY-PanTumor02 Phase II Trial. J Clin Oncol 2024;42:47–58. Available at: https://www.ncbi.nlm.nih.gov/pubmed/37870536.

169. Oaknin A, Friedman CF, Roman LD, et al. Neratinib in patients with HER2-mutant, metastatic cervical cancer: Findings from the phase 2 SUMMIT basket trial. Gynecol Oncol 2020;159:150–156. Available at: https://www.ncbi.nlm.nih.gov/pubmed/32723675.

170. Friedman CF, D'Souza A, Bello Roufai D, et al. Targeting HER2-mutant metastatic cervical cancer with neratinib: Final results from the phase 2 SUMMIT basket trial. Gynecol Oncol 2024;181:162–169. Available at: https://www.ncbi.nlm.nih.gov/pubmed/38211393.

171. Subbiah V, Wolf J, Konda B, et al. Tumour-agnostic efficacy and safety of selpercatinib in patients with RET fusion-positive solid tumours other than lung or thyroid tumours (LIBRETTO-001): a phase 1/2, open-label, basket trial. Lancet Oncol 2022;23:1261–1273. Available at: https://www.ncbi.nlm.nih.gov/pubmed/36108661.

172. Duke ES, Bradford D, Marcovitz M, et al. FDA Approval Summary: Selpercatinib for the Treatment of Advanced RET Fusion-Positive Solid Tumors. Clin Cancer Res 2023;29:3573–3578. Available at: https://www.ncbi.nlm.nih.gov/pubmed/37265412.

173. American College of O, Gynecologists. ACOG practice bulletin. Diagnosis and treatment of cervical carcinomas. Number 35, May 2002. American College of Obstetricians and Gynecologists. Int J Gynaecol Obstet 2002;78:79–91. Available at: https://www.ncbi.nlm.nih.gov/pubmed/12197489.

174. Gaffney DK, Erickson-Wittmann BA, Jhingran A, et al. ACR Appropriateness Criteria(R) on Advanced Cervical Cancer Expert Panel on Radiation Oncology-Gynecology. Int J Radiat Oncol Biol Phys 2011;81:609–614. Available at: https://www.ncbi.nlm.nih.gov/pubmed/21215531.

175. Monk BJ, Tewari KS, Koh WJ. Multimodality therapy for locally advanced cervical carcinoma: state of the art and future directions. J Clin Oncol 2007;25:2952–2965. Available at: https://www.ncbi.nlm.nih.gov/pubmed/17617527.

176. Lorusso D, Xiang Y, Hasegawa K, et al. Pembrolizumab or placebo with chemoradiotherapy followed by pembrolizumab or placebo for newly diagnosed, high-risk, locally advanced cervical cancer (ENGOT-cx11/GOG-3047/KEYNOTE-A18): a randomised, double-blind, phase 3 clinical trial. Lancet 2024;403:1341–1350. Available at: https://www.ncbi.nlm.nih.gov/pubmed/38521086.

177. Gien LT, Beauchemin MC, Thomas G. Adenocarcinoma: a unique cervical cancer. Gynecol Oncol 2010;116:140–146. Available at: https://www.ncbi.nlm.nih.gov/pubmed/19880165.

178. Baalbergen A, Veenstra Y, Stalpers LL, Ansink AC. Primary surgery versus primary radiation therapy with or without chemotherapy for early adenocarcinoma of the uterine cervix. Cochrane Database Syst Rev 2010:CD006248. Available at: https://www.ncbi.nlm.nih.gov/pubmed/20091590.

179. Park JY, Kim DY, Kim JH, et al. Outcomes after radical hysterectomy in patients with early-stage adenocarcinoma of uterine cervix. Br J Cancer 2010;102:1692–1698. Available at: https://www.ncbi.nlm.nih.gov/pubmed/20531414.

180. Wo JY, Viswanathan AN. Impact of radiotherapy on fertility, pregnancy, and neonatal outcomes in female cancer patients. Int J Radiat Oncol Biol Phys 2009;73:1304–1312. Available at: https://www.ncbi.nlm.nih.gov/pubmed/19306747.

181. Pahisa J, Martinez-Roman S, Martinez-Zamora MA, et al. Laparoscopic ovarian transposition in patients with early cervical cancer. Int J Gynecol Cancer 2008;18:584–589. Available at: https://www.ncbi.nlm.nih.gov/pubmed/18476952.

Version 2.2026 © 2025 National Comprehensive Cancer Network® (NCCN®), All rights reserved. NCCN Guidelines®, and this illustration may not be reproduced in any form without the express written permission of NCCN.

PLEASE NOTE that use of this NCCN Content is governed by the End-User License Agreement, and you MAY NOT distribute this Content or use it with any artificial intelligence model or tool.
Printed by Galya Basol Kochav on 12/29/2025 12:47:39 PM. Copyright © 2025 National Comprehensive Cancer Network, Inc. All Rights Reserved.

182. Morice P, Juncker L, Rey A, et al. Ovarian transposition for patients with cervical carcinoma treated by radiosurgical combination. Fertil Steril 2000;74:743–748. Available at: https://www.ncbi.nlm.nih.gov/pubmed/11020517.

183. Cibula D, Köhler C, Bajsova S, et al. 526MO Pathological assessment of sentinel lymph node in early-stage cervical cancer: Results from the prospective SENTIX trial (CEEGOG-CX01; ENGOT-CX2). Annals of Oncology 2022. Available at:

184. Koliopoulos G, Sotiriadis A, Kyrgiou M, et al. Conservative surgical methods for FIGO stage IA2 squamous cervical carcinoma and their role in preserving women's fertility. Gynecol Oncol 2004;93:469–473. Available at: https://www.ncbi.nlm.nih.gov/pubmed/15099964.

185. Wright JD, Nathavithrana R, Lewin SN, et al. Fertility-conserving surgery for young women with stage IA1 cervical cancer: safety and access. Obstet Gynecol 2010;115:585–590. Available at: https://www.ncbi.nlm.nih.gov/pubmed/20177290.

186. Tierney KE, Lin PS, Amezcua C, et al. Cervical conization of adenocarcinoma in situ: a predicting model of residual disease. Am J Obstet Gynecol 2014;210:366 e361–366 e365. Available at: https://www.ncbi.nlm.nih.gov/pubmed/24370689.

187. Yoneda JY, Braganca JF, Sarian LO, et al. Surgical treatment of microinvasive cervical cancer: analysis of pathologic features with implications on radicality. Int J Gynecol Cancer 2015;25:694–698. Available at: https://www.ncbi.nlm.nih.gov/pubmed/25742569.

188. Bernardini M, Barrett J, Seaward G, Covens A. Pregnancy outcomes in patients after radical trachelectomy. Am J Obstet Gynecol 2003;189:1378–1382. Available at: https://www.ncbi.nlm.nih.gov/pubmed/14634572.

189. Boss EA, van Golde RJ, Beerendonk CC, Massuger LF. Pregnancy after radical trachelectomy: a real option? Gynecol Oncol 2005;99:S152–156. Available at: https://www.ncbi.nlm.nih.gov/pubmed/16140367.

190. Plante M, Renaud MC, Hoskins IA, Roy M. Vaginal radical trachelectomy: a valuable fertility-preserving option in the management of early-stage cervical cancer. A series of 50 pregnancies and review of the literature. Gynecol Oncol 2005;98:3–10. Available at: https://www.ncbi.nlm.nih.gov/pubmed/15936061.

191. Marchiole P, Benchaib M, Buenerd A, et al. Oncological safety of laparoscopic-assisted vaginal radical trachelectomy (LARVT or Dargent's operation): a comparative study with laparoscopic-assisted vaginal radical hysterectomy (LARVH). Gynecol Oncol 2007;106:132–141. Available at: https://www.ncbi.nlm.nih.gov/pubmed/17493666.

192. Landoni F, Zanagnolo V, Lovato-Diaz L, et al. Ovarian metastases in early-stage cervical cancer (IA2-IIA): a multicenter retrospective study of 1965 patients (a Cooperative Task Force study). Int J Gynecol Cancer 2007;17:623–628. Available at: https://www.ncbi.nlm.nih.gov/pubmed/17309669.

193. Shimada M, Kigawa J, Nishimura R, et al. Ovarian metastasis in carcinoma of the uterine cervix. Gynecol Oncol 2006;101:234–237. Available at: https://www.ncbi.nlm.nih.gov/pubmed/16300819.

194. Small W, Jr., Strauss JB, Jhingran A, et al. ACR Appropriateness Criteria(R) definitive therapy for early-stage cervical cancer. Am J Clin Oncol 2012;35:399–405. Available at: https://www.ncbi.nlm.nih.gov/pubmed/22810416.

195. Rotman M, Sedlis A, Piedmonte MR, et al. A phase III randomized trial of postoperative pelvic irradiation in Stage IB cervical carcinoma with poor prognostic features: follow-up of a gynecologic oncology group study. Int J Radiat Oncol Biol Phys 2006;65:169–176. Available at: https://www.ncbi.nlm.nih.gov/pubmed/16427212.

196. Monk BJ, Wang J, Im S, et al. Rethinking the use of radiation and chemotherapy after radical hysterectomy: a clinical-pathologic analysis of a Gynecologic Oncology Group/Southwest Oncology Group/Radiation Therapy Oncology Group trial. Gynecol Oncol 2005;96:721–728. Available at: https://www.ncbi.nlm.nih.gov/pubmed/15721417.

Version 2.2026 © 2025 National Comprehensive Cancer Network® (NCCN®), All rights reserved. NCCN Guidelines®, and this illustration may not be reproduced in any form without the express written permission of NCCN.

PLEASE NOTE that use of this NCCN Content is governed by the End-User License Agreement, and you MAY NOT distribute this Content or use it with any artificial intelligence model or tool.
Printed by Galya Basol Kochav on 12/29/2025 12:47:39 PM. Copyright © 2025 National Comprehensive Cancer Network, Inc. All Rights Reserved.

197. Chernofsky MR, Felix JC, Muderspach LI, et al. Influence of quantity of lymph vascular space invasion on time to recurrence in women with early-stage squamous cancer of the cervix. Gynecol Oncol 2006;100:288–293. Available at: https://www.ncbi.nlm.nih.gov/pubmed/16182347.

198. Marchiole P, Buenerd A, Benchaib M, et al. Clinical significance of lympho vascular space involvement and lymph node micrometastases in early-stage cervical cancer: a retrospective case-control surgico-pathological study. Gynecol Oncol 2005;97:727–732. Available at: https://www.ncbi.nlm.nih.gov/pubmed/15943983.

199. Peters WA, 3rd, Liu PY, Barrett RJ, 2nd, et al. Concurrent chemotherapy and pelvic radiation therapy compared with pelvic radiation therapy alone as adjuvant therapy after radical surgery in high-risk early-stage cancer of the cervix. J Clin Oncol 2000;18:1606–1613. Available at: https://www.ncbi.nlm.nih.gov/pubmed/10764420.

200. Trifiletti DM, Swisher-McClure S, Showalter TN, et al. Postoperative Chemoradiation Therapy in High-Risk Cervical Cancer: Re-evaluating the Findings of Gynecologic Oncology Group Study 109 in a Large, Population-Based Cohort. Int J Radiat Oncol Biol Phys 2015;93:1032–1044. Available at: https://www.ncbi.nlm.nih.gov/pubmed/26581141.

201. Lutz ST, Chow EL, Hartsell WF, Konski AA. A review of hypofractionated palliative radiotherapy. Cancer 2007;109:1462–1470. Available at: https://www.ncbi.nlm.nih.gov/pubmed/17330854.

202. Plante M, Kwon JS, Ferguson S, et al. Simple versus Radical Hysterectomy in Women with Low-Risk Cervical Cancer. N Engl J Med 2024;390:819–829. Available at: https://www.ncbi.nlm.nih.gov/pubmed/38416430.

203. Raju SK, Papadopoulos AJ, Montalto SA, et al. Fertility-sparing surgery for early cervical cancer-approach to less radical surgery. Int J Gynecol Cancer 2012;22:311–317. Available at: https://www.ncbi.nlm.nih.gov/pubmed/22237381.

204. Li J, Wu X, Li X, Ju X. Abdominal radical trachelectomy: Is it safe for IB1 cervical cancer with tumors >/= 2 cm? Gynecol Oncol 2013;131:87–92. Available at: https://www.ncbi.nlm.nih.gov/pubmed/23872192.

205. Landoni F, Maneo A, Colombo A, et al. Randomised study of radical surgery versus radiotherapy for stage Ib-IIa cervical cancer. Lancet 1997;350:535–540. Available at: https://www.ncbi.nlm.nih.gov/pubmed/9284774.

206. Landoni F, Maneo A, Cormio G, et al. Class II versus class III radical hysterectomy in stage IB-IIA cervical cancer: a prospective randomized study. Gynecol Oncol 2001;80:3–12. Available at: https://www.ncbi.nlm.nih.gov/pubmed/11136561.

207. Keys HM, Bundy BN, Stehman FB, et al. Cisplatin, radiation, and adjuvant hysterectomy compared with radiation and adjuvant hysterectomy for bulky stage IB cervical carcinoma. N Engl J Med 1999;340:1154–1161. Available at: https://www.ncbi.nlm.nih.gov/pubmed/10202166.

208. Rose PG, Bundy BN, Watkins EB, et al. Concurrent cisplatin-based radiotherapy and chemotherapy for locally advanced cervical cancer. N Engl J Med 1999;340:1144–1153. Available at: https://www.ncbi.nlm.nih.gov/pubmed/10202165.

209. Whitney CW, Sause W, Bundy BN, et al. Randomized comparison of fluorouracil plus cisplatin versus hydroxyurea as an adjunct to radiation therapy in stage IIB-IVA carcinoma of the cervix with negative para-aortic lymph nodes: a Gynecologic Oncology Group and Southwest Oncology Group study. J Clin Oncol 1999;17:1339–1348. Available at: https://www.ncbi.nlm.nih.gov/pubmed/10334517.

210. Morris M, Eifel PJ, Lu J, et al. Pelvic radiation with concurrent chemotherapy compared with pelvic and para-aortic radiation for high-risk cervical cancer. N Engl J Med 1999;340:1137–1143. Available at: https://www.ncbi.nlm.nih.gov/pubmed/10202164.

211. Thomas GM. Improved treatment for cervical cancer--concurrent chemotherapy and radiotherapy. N Engl J Med 1999;340:1198–1200. Available at: https://www.ncbi.nlm.nih.gov/pubmed/10202172.

212. Rose PG, Ali S, Watkins E, et al. Long-term follow-up of a randomized trial comparing concurrent single agent cisplatin, cisplatin-based combination chemotherapy, or hydroxyurea during pelvic irradiation

Version 2.2026 © 2025 National Comprehensive Cancer Network® (NCCN®), All rights reserved. NCCN Guidelines®, and this illustration may not be reproduced in any form without the express written permission of NCCN.

PLEASE NOTE that use of this NCCN Content is governed by the End-User License Agreement, and you MAY NOT distribute this Content or use it with any artificial intelligence model or tool.
Printed by Galya Basol Kochav on 12/29/2025 12:47:39 PM. Copyright © 2025 National Comprehensive Cancer Network, Inc. All Rights Reserved.

for locally advanced cervical cancer: a Gynecologic Oncology Group Study. J Clin Oncol 2007;25:2804–2810. Available at: https://www.ncbi.nlm.nih.gov/pubmed/17502627.

213. Eifel PJ, Winter K, Morris M, et al. Pelvic irradiation with concurrent chemotherapy versus pelvic and para-aortic irradiation for high-risk cervical cancer: an update of radiation therapy oncology group trial (RTOG) 90-01. J Clin Oncol 2004;22:872–880. Available at: https://www.ncbi.nlm.nih.gov/pubmed/14990643.

214. Stehman FB, Ali S, Keys HM, et al. Radiation therapy with or without weekly cisplatin for bulky stage 1B cervical carcinoma: follow-up of a Gynecologic Oncology Group trial. Am J Obstet Gynecol 2007;197:503 e501–506. Available at: https://www.ncbi.nlm.nih.gov/pubmed/17980189.

215. Chemoradiotherapy for Cervical Cancer Meta-Analysis C. Reducing uncertainties about the effects of chemoradiotherapy for cervical cancer: a systematic review and meta-analysis of individual patient data from 18 randomized trials. J Clin Oncol 2008;26:5802–5812. Available at: https://www.ncbi.nlm.nih.gov/pubmed/19001332.

216. Pearcey R, Miao Q, Kong W, et al. Impact of adoption of chemoradiotherapy on the outcome of cervical cancer in Ontario: results of a population-based cohort study. J Clin Oncol 2007;25:2383–2388. Available at: https://www.ncbi.nlm.nih.gov/pubmed/17557951.

217. Lorvidhaya V, Chitapanarux I, Sangruchi S, et al. Concurrent mitomycin C, 5-fluorouracil, and radiotherapy in the treatment of locally advanced carcinoma of the cervix: a randomized trial. Int J Radiat Oncol Biol Phys 2003;55:1226–1232. Available at: https://www.ncbi.nlm.nih.gov/pubmed/12654431.

218. Pattaranutaporn P, Thirapakawong C, Chansilpa Y, et al. Phase II study of concurrent gemcitabine and radiotherapy in locally advanced stage IIIB cervical carcinoma. Gynecol Oncol 2001;81:404–407. Available at: https://www.ncbi.nlm.nih.gov/pubmed/11371129.

219. Candelaria M, Garcia-Arias A, Cetina L, Duenas-Gonzalez A. Radiosensitizers in cervical cancer. Cisplatin and beyond. Radiat Oncol 2006;1:15. Available at: https://www.ncbi.nlm.nih.gov/pubmed/16722549.

220. Cerrotta A, Gardan G, Cavina R, et al. Concurrent radiotherapy and weekly paclitaxel for locally advanced or recurrent squamous cell carcinoma of the uterine cervix. A pilot study with intensification of dose. Eur J Gynaecol Oncol 2002;23:115–119. Available at: https://www.ncbi.nlm.nih.gov/pubmed/12013105.

221. Rose PG. Combination therapy: New treatment paradigm for locally advanced cervical cancer? Nat Rev Clin Oncol 2011;8:388–390. Available at: https://www.ncbi.nlm.nih.gov/pubmed/21629215.

222. Keys HM, Bundy BN, Stehman FB, et al. Radiation therapy with and without extrafascial hysterectomy for bulky stage IB cervical carcinoma: a randomized trial of the Gynecologic Oncology Group. Gynecol Oncol 2003;89:343–353. Available at: https://www.ncbi.nlm.nih.gov/pubmed/12798694.

223. Kokka F, Bryant A, Brockbank E, et al. Hysterectomy with radiotherapy or chemotherapy or both for women with locally advanced cervical cancer. Cochrane Database Syst Rev 2015;4:CD010260. Available at: https://www.ncbi.nlm.nih.gov/pubmed/25847525.

224. Colombo PE, Bertrand MM, Gutowski M, et al. Total laparoscopic radical hysterectomy for locally advanced cervical carcinoma (stages IIB, IIA and bulky stages IB) after concurrent chemoradiation therapy: surgical morbidity and oncological results. Gynecol Oncol 2009;114:404–409. Available at: https://www.ncbi.nlm.nih.gov/pubmed/19555996.

225. Touboul C, Uzan C, Mauguen A, et al. Prognostic factors and morbidities after completion surgery in patients undergoing initial chemoradiation therapy for locally advanced cervical cancer. Oncologist 2010;15:405–415. Available at: https://www.ncbi.nlm.nih.gov/pubmed/20332143.

226. Huguet F, Cojocariu OM, Levy P, et al. Preoperative concurrent radiation therapy and chemotherapy for bulky stage IB2, IIA, and IIB carcinoma of the uterine cervix with proximal parametrial invasion. Int J Radiat Oncol Biol Phys 2008;72:1508–1515. Available at: https://www.ncbi.nlm.nih.gov/pubmed/18676093.

Version 2.2026 © 2025 National Comprehensive Cancer Network® (NCCN®), All rights reserved. NCCN Guidelines®, and this illustration may not be reproduced in any form without the express written permission of NCCN.

PLEASE NOTE that use of this NCCN Content is governed by the End-User License Agreement, and you MAY NOT distribute this Content or use it with any artificial intelligence model or tool.
Printed by Galya Basol Kochav on 12/29/2025 12:47:39 PM. Copyright © 2025 National Comprehensive Cancer Network, Inc. All Rights Reserved.

227. Cetina L, Gonzalez-Enciso A, Cantu D, et al. Brachytherapy versus radical hysterectomy after external beam chemoradiation with gemcitabine plus cisplatin: a randomized, phase III study in IB2-IIB cervical cancer patients. Ann Oncol 2013;24:2043–2047. Available at: https://www.ncbi.nlm.nih.gov/pubmed/23609186.

228. Gandy N, Arshad MA, Park WE, et al. FDG-PET Imaging in Cervical Cancer. Semin Nucl Med 2019;49:461–470. Available at: https://www.ncbi.nlm.nih.gov/pubmed/31630730.

229. Brooks RA, Rader JS, Dehdashti F, et al. Surveillance FDG-PET detection of asymptomatic recurrences in patients with cervical cancer. Gynecol Oncol 2009;112:104–109. Available at: https://www.ncbi.nlm.nih.gov/pubmed/18929403.

230. McCormack M, Eminowicz G, Gallardo D, et al. Induction chemotherapy followed by standard chemoradiotherapy versus standard chemoradiotherapy alone in patients with locally advanced cervical cancer (GCIG INTERLACE): an international, multicentre, randomised phase 3 trial. Lancet 2024;404:1525–1535. Available at: https://www.ncbi.nlm.nih.gov/pubmed/39419054.

231. Salani R, Khanna N, Frimer M, et al. An update on post-treatment surveillance and diagnosis of recurrence in women with gynecologic malignancies: Society of Gynecologic Oncology (SGO) recommendations. Gynecol Oncol 2017;146:3–10. Available at: https://www.ncbi.nlm.nih.gov/pubmed/28372871.

232. Bodurka-Bevers D, Morris M, Eifel PJ, et al. Posttherapy surveillance of women with cervical cancer: an outcomes analysis. Gynecol Oncol 2000;78:187–193. Available at: https://www.ncbi.nlm.nih.gov/pubmed/10926801.

233. Morice P, Deyrolle C, Rey A, et al. Value of routine follow-up procedures for patients with stage I/II cervical cancer treated with combined surgery-radiation therapy. Ann Oncol 2004;15:218–223. Available at: https://www.ncbi.nlm.nih.gov/pubmed/14760112.

234. Elit L, Fyles AW, Devries MC, et al. Follow-up for women after treatment for cervical cancer: a systematic review. Gynecol Oncol 2009;114:528–535. Available at: https://www.ncbi.nlm.nih.gov/pubmed/19560188.

235. Sala E, Micco M, Burger IA, et al. Complementary Prognostic Value of Pelvic Magnetic Resonance Imaging and Whole-Body Fluorodeoxyglucose Positron Emission Tomography/Computed Tomography in the Pretreatment Assessment of Patients With Cervical Cancer. Int J Gynecol Cancer 2015;25:1461–1467. Available at: https://www.ncbi.nlm.nih.gov/pubmed/26397068.

236. Gee MS, Atri M, Bandos AI, et al. Identification of Distant Metastatic Disease in Uterine Cervical and Endometrial Cancers with FDG PET/CT: Analysis from the ACRIN 6671/GOG 0233 Multicenter Trial. Radiology 2018;287:176–184. Available at: https://www.ncbi.nlm.nih.gov/pubmed/29185901.

237. Balleyguier C, Sala E, Da Cunha T, et al. Staging of uterine cervical cancer with MRI: guidelines of the European Society of Urogenital Radiology. Eur Radiol 2011;21:1102–1110. Available at: https://www.ncbi.nlm.nih.gov/pubmed/21063710.

238. Sala E, Rockall AG, Freeman SJ, et al. The added role of MR imaging in treatment stratification of patients with gynecologic malignancies: what the radiologist needs to know. Radiology 2013;266:717–740. Available at: https://www.ncbi.nlm.nih.gov/pubmed/23431227.

239. Elit L, Reade CJ. Recommendations for Follow-up Care for Gynecologic Cancer Survivors. Obstet Gynecol 2015;126:1207–1214. Available at: https://www.ncbi.nlm.nih.gov/pubmed/26551194.

240. Rajendran JG, Greer BE. Expanding role of positron emission tomography in cancer of the uterine cervix. J Natl Compr Canc Netw 2006;4:463–469. Available at: https://www.ncbi.nlm.nih.gov/pubmed/16687094.

241. Atri M, Zhang Z, Dehdashti F, et al. Utility of PET-CT to evaluate retroperitoneal lymph node metastasis in advanced cervical cancer: Results of ACRIN6671/GOG0233 trial. Gynecol Oncol 2016;142:413–419. Available at: https://www.ncbi.nlm.nih.gov/pubmed/27178725.

Version 2.2026 © 2025 National Comprehensive Cancer Network® (NCCN®), All rights reserved. NCCN Guidelines®, and this illustration may not be reproduced in any form without the express written permission of NCCN.

PLEASE NOTE that use of this NCCN Content is governed by the End-User License Agreement, and you MAY NOT distribute this Content or use it with any artificial intelligence model or tool.
Printed by Galya Basol Kochav on 12/29/2025 12:47:39 PM. Copyright © 2025 National Comprehensive Cancer Network, Inc. All Rights Reserved.

242. Schwarz JK, Siegel BA, Dehdashti F, Grigsby PW. Association of posttherapy positron emission tomography with tumor response and survival in cervical carcinoma. JAMA 2007;298:2289–2295. Available at: https://www.ncbi.nlm.nih.gov/pubmed/18029833.

243. Sironi S, Picchio M, Landoni C, et al. Post-therapy surveillance of patients with uterine cancers: value of integrated FDG PET/CT in the detection of recurrence. Eur J Nucl Med Mol Imaging 2007;34:472–479. Available at: https://www.ncbi.nlm.nih.gov/pubmed/17106701.

244. Chung HH, Jo H, Kang WJ, et al. Clinical impact of integrated PET/CT on the management of suspected cervical cancer recurrence. Gynecol Oncol 2007;104:529–534. Available at: https://www.ncbi.nlm.nih.gov/pubmed/17049971.

245. Wolfson AH, Varia MA, Moore D, et al. ACR Appropriateness Criteria(R) role of adjuvant therapy in the management of early stage cervical cancer. Gynecol Oncol 2012;125:256–262. Available at: https://www.ncbi.nlm.nih.gov/pubmed/22155418.

246. Chaturvedi AK, Kleinerman RA, Hildesheim A, et al. Second cancers after squamous cell carcinoma and adenocarcinoma of the cervix. J Clin Oncol 2009;27:967–973. Available at: https://www.ncbi.nlm.nih.gov/pubmed/19114696.

247. Chaturvedi AK, Engels EA, Gilbert ES, et al. Second cancers among 104,760 survivors of cervical cancer: evaluation of long-term risk. J Natl Cancer Inst 2007;99:1634–1643. Available at: https://www.ncbi.nlm.nih.gov/pubmed/17971527.

248. Kumar S, Shah JP, Bryant CS, et al. Radiation-associated endometrial cancer. Obstet Gynecol 2009;113:319–325. Available at: https://www.ncbi.nlm.nih.gov/pubmed/19155901.

249. Hong JH, Tsai CS, Lai CH, et al. Recurrent squamous cell carcinoma of cervix after definitive radiotherapy. Int J Radiat Oncol Biol Phys 2004;60:249–257. Available at: https://www.ncbi.nlm.nih.gov/pubmed/15337563.

250. Thomas GM, Dembo AJ, Myhr T, et al. Long-term results of concurrent radiation and chemotherapy for carcinoma of the cervix recurrent after surgery. Int J Gynecol Cancer 1993;3:193–198. Available at: https://www.ncbi.nlm.nih.gov/pubmed/11578344.

251. Kim JS, Kim JS, Kim SY, et al. Hyperfractionated radiotherapy with concurrent chemotherapy for para-aortic lymph node recurrence in carcinoma of the cervix. Int J Radiat Oncol Biol Phys 2003;55:1247–1253. Available at: https://www.ncbi.nlm.nih.gov/pubmed/12654434.

252. Chung YL, Jian JJ, Cheng SH, et al. Extended-field radiotherapy and high-dose-rate brachytherapy with concurrent and adjuvant cisplatin-based chemotherapy for locally advanced cervical cancer: a phase I/II study. Gynecol Oncol 2005;97:126–135. Available at: https://www.ncbi.nlm.nih.gov/pubmed/15790448.

253. Marnitz S, Dowdy S, Lanowska M, et al. Exenterations 60 years after first description: results of a survey among US and German Gynecologic Oncology Centers. Int J Gynecol Cancer 2009;19:974–977. Available at: https://www.ncbi.nlm.nih.gov/pubmed/19574795.

254. Berek JS, Howe C, Lagasse LD, Hacker NF. Pelvic exenteration for recurrent gynecologic malignancy: survival and morbidity analysis of the 45-year experience at UCLA. Gynecol Oncol 2005;99:153–159. Available at: https://www.ncbi.nlm.nih.gov/pubmed/16054678.

255. Goldberg GL, Sukumvanich P, Einstein MH, et al. Total pelvic exenteration: the Albert Einstein College of Medicine/Montefiore Medical Center Experience (1987 to 2003). Gynecol Oncol 2006;101:261–268. Available at: https://www.ncbi.nlm.nih.gov/pubmed/16426668.

256. Morley GW, Hopkins MP, Lindenauer SM, Roberts JA. Pelvic exenteration, University of Michigan: 100 patients at 5 years. Obstet Gynecol 1989;74:934–943. Available at: https://www.ncbi.nlm.nih.gov/pubmed/2586960.

257. Fleisch MC, Pantke P, Beckmann MW, et al. Predictors for long-term survival after interdisciplinary salvage surgery for advanced or recurrent gynecologic cancers. J Surg Oncol 2007;95:476–484. Available at: https://www.ncbi.nlm.nih.gov/pubmed/17192947.

Version 2.2026 © 2025 National Comprehensive Cancer Network® (NCCN®), All rights reserved. NCCN Guidelines®, and this illustration may not be reproduced in any form without the express written permission of NCCN.

PLEASE NOTE that use of this NCCN Content is governed by the End-User License Agreement, and you MAY NOT distribute this Content or use it with any artificial intelligence model or tool.
Printed by Galya Basol Kochav on 12/29/2025 12:47:39 PM. Copyright © 2025 National Comprehensive Cancer Network, Inc. All Rights Reserved.

258. Tran PT, Su Z, Hara W, et al. Long-term survivors using intraoperative radiotherapy for recurrent gynecologic malignancies. Int J Radiat Oncol Biol Phys 2007;69:504–511. Available at: https://www.ncbi.nlm.nih.gov/pubmed/17560736.

259. Rutledge FN, Smith JP, Wharton JT, O'Quinn AG. Pelvic exenteration: analysis of 296 patients. Am J Obstet Gynecol 1977;129:881–892. Available at: https://www.ncbi.nlm.nih.gov/pubmed/930972.

260. Symmonds RE, Pratt JH, Webb MJ. Exenterative operations: experience with 198 patients. Am J Obstet Gynecol 1975;121:907–918. Available at: https://www.ncbi.nlm.nih.gov/pubmed/1115180.

261. Soper JT, Secord AA, Havrilesky LJ, et al. Comparison of gracilis and rectus abdominis myocutaneous flap neovaginal reconstruction performed during radical pelvic surgery: flap-specific morbidity. Int J Gynecol Cancer 2007;17:298–303. Available at: https://www.ncbi.nlm.nih.gov/pubmed/17291272.

262. Mirhashemi R, Averette HE, Lambrou N, et al. Vaginal reconstruction at the time of pelvic exenteration: a surgical and psychosexual analysis of techniques. Gynecol Oncol 2002;87:39–45. Available at: https://www.ncbi.nlm.nih.gov/pubmed/12468340.

263. Turns D. Psychosocial issues: pelvic exenterative surgery. J Surg Oncol 2001;76:224–236. Available at: https://www.ncbi.nlm.nih.gov/pubmed/11276026.

264. Perkins V, Moore K, Vesely S, et al. Incorporation of whole pelvic radiation into treatment of stage IVB cervical cancer: A novel treatment strategy. Gynecol Oncol 2020;156:100–106. Available at: https://www.ncbi.nlm.nih.gov/pubmed/31810653.

265. Im JH, Yoon HI, Kim S, et al. Tailored radiotherapeutic strategies for disseminated uterine cervical cancer patients. Radiat Oncol 2015;10:77. Available at: https://www.ncbi.nlm.nih.gov/pubmed/25884833.

266. Kim JY, Kim JY, Kim JH, et al. Curative chemoradiotherapy in patients with stage IVB cervical cancer presenting with paraortic and left supraclavicular lymph node metastases. Int J Radiat Oncol Biol Phys 2012;84:741–747. Available at: https://www.ncbi.nlm.nih.gov/pubmed/22898382.

267. Hoppenot C, Littell RD, DeEulis T, Hartenbach EM. Top Ten Tips Palliative Care Clinicians Should Know About Caring for Patients with Cervical Cancer. J Palliat Med 2021;24:438–442. Available at: https://www.ncbi.nlm.nih.gov/pubmed/33513069.

268. Smith SC, Koh WJ. Palliative radiation therapy for gynaecological malignancies. Best Pract Res Clin Obstet Gynaecol 2001;15:265–278. Available at: https://www.ncbi.nlm.nih.gov/pubmed/11358401.

269. Spanos WJ, Jr., Perez CA, Marcus S, et al. Effect of rest interval on tumor and normal tissue response--a report of phase III study of accelerated split course palliative radiation for advanced pelvic malignancies (RTOG-8502). Int J Radiat Oncol Biol Phys 1993;25:399–403. Available at: https://www.ncbi.nlm.nih.gov/pubmed/7679668.

270. Moore DH, Blessing JA, McQuellon RP, et al. Phase III study of cisplatin with or without paclitaxel in stage IVB, recurrent, or persistent squamous cell carcinoma of the cervix: a gynecologic oncology group study. J Clin Oncol 2004;22:3113–3119. Available at: https://www.ncbi.nlm.nih.gov/pubmed/15284262.

271. Long HJ, 3rd, Bundy BN, Grendys EC, Jr., et al. Randomized phase III trial of cisplatin with or without topotecan in carcinoma of the uterine cervix: a Gynecologic Oncology Group Study. J Clin Oncol 2005;23:4626–4633. Available at: https://www.ncbi.nlm.nih.gov/pubmed/15911865.

272. Nam EJ, Lee M, Yim GW, et al. Comparison of carboplatin- and cisplatin-based concurrent chemoradiotherapy in locally advanced cervical cancer patients with morbidity risks. Oncologist 2013;18:843–849. Available at: https://www.ncbi.nlm.nih.gov/pubmed/23821328.

273. Christie DR, Bull CA, Gebski V, Langlands AO. Concurrent 5-fluorouracil, mitomycin C and irradiation in locally advanced cervix cancer. Radiother Oncol 1995;37:181–189. Available at: https://www.ncbi.nlm.nih.gov/pubmed/8746586.

Version 2.2026 © 2025 National Comprehensive Cancer Network® (NCCN®), All rights reserved. NCCN Guidelines®, and this illustration may not be reproduced in any form without the express written permission of NCCN.

PLEASE NOTE that use of this NCCN Content is governed by the End-User License Agreement, and you MAY NOT distribute this Content or use it with any artificial intelligence model or tool.
Printed by Galya Basol Kochav on 12/29/2025 12:47:39 PM. Copyright © 2025 National Comprehensive Cancer Network, Inc. All Rights Reserved.

274. Rakovitch E, Fyles AW, Pintilie M, Leung PM. Role of mitomycin C in the development of late bowel toxicity following chemoradiation for locally advanced carcinoma of the cervix. Int J Radiat Oncol Biol Phys 1997;38:979–987. Available at: https://www.ncbi.nlm.nih.gov/pubmed/9276362.

275. Verma AK, Arya AK, Kumar M, et al. Weekly cisplatin or gemcitabine concomitant with radiation in the management of locally advanced carcinoma cervix: results from an observational study. J Gynecol Oncol 2009;20:221–226. Available at: https://www.ncbi.nlm.nih.gov/pubmed/20041098.

276. King M, McConkey C, Latief TN, et al. Improved survival after concurrent weekly cisplatin and radiotherapy for cervical carcinoma with assessment of acute and late side-effects. Clin Oncol (R Coll Radiol) 2006;18:38–45. Available at: https://www.ncbi.nlm.nih.gov/pubmed/16477918.

277. Tan LT, Zahra M. Long-term survival and late toxicity after chemoradiotherapy for cervical cancer--the Addenbrooke's experience. Clin Oncol (R Coll Radiol) 2008;20:358–364. Available at: https://www.ncbi.nlm.nih.gov/pubmed/18395427.

278. Lorusso D, Xiang Y, Hasegawa K, et al. LBA38 Pembrolizumab plus chemoradiotherapy for high-risk locally advanced cervical cancer: A randomized, double-blind, phase III ENGOT-cx11/GOG-3047/KEYNOTE-A18 study. Annals of Oncology 2023;34:S1279–S1280. Available at:

279. Matsuo K, Machida H, Mandelbaum RS, et al. Validation of the 2018 FIGO cervical cancer staging system. Gynecol Oncol 2019;152:87–93. Available at: https://www.ncbi.nlm.nih.gov/pubmed/30389105.

280. Gaffney DK, Du Bois A, Narayan K, et al. Practice patterns of radiotherapy in cervical cancer among member groups of the Gynecologic Cancer Intergroup (GCIG). Int J Radiat Oncol Biol Phys 2007;68:485–490. Available at: https://www.ncbi.nlm.nih.gov/pubmed/17336465.

281. Cetina L, Garcia-Arias A, Uribe Mde J, et al. Concurrent chemoradiation with carboplatin for elderly, diabetic and hypertensive patients with locally advanced cervical cancer. Eur J Gynaecol Oncol 2008;29:608–612. Available at: https://www.ncbi.nlm.nih.gov/pubmed/19115688.

282. Dubay RA, Rose PG, O'Malley DM, et al. Evaluation of concurrent and adjuvant carboplatin with radiation therapy for locally advanced cervical cancer. Gynecol Oncol 2004;94:121–124. Available at: https://www.ncbi.nlm.nih.gov/pubmed/15262129.

283. Higgins RV, Naumann WR, Hall JB, Haake M. Concurrent carboplatin with pelvic radiation therapy in the primary treatment of cervix cancer. Gynecol Oncol 2003;89:499–503. Available at: https://www.ncbi.nlm.nih.gov/pubmed/12798718.

284. Wong LC, Ngan HY, Cheung AN, et al. Chemoradiation and adjuvant chemotherapy in cervical cancer. J Clin Oncol 1999;17:2055–2060. Available at: https://www.ncbi.nlm.nih.gov/pubmed/10561258.

285. Tharavichitkul E, Lorvidhaya V, Kamnerdsupaphon P, et al. Combined chemoradiation of cisplatin versus carboplatin in cervical carcinoma: a single institution experience from Thailand. BMC Cancer 2016;16:501. Available at: https://www.ncbi.nlm.nih.gov/pubmed/27435245.

286. Tabatabaei FS, Saeedian A, Azimi A, et al. Evaluation of Survival Rate and Associated Factors in Patients with Cervical Cancer: A Retrospective Cohort Study. J Res Health Sci 2022;22:e00552. Available at: https://www.ncbi.nlm.nih.gov/pubmed/36511264.

287. Monk BJ, Colombo N, Tewari KS, et al. First-Line Pembrolizumab + Chemotherapy Versus Placebo + Chemotherapy for Persistent, Recurrent, or Metastatic Cervical Cancer: Final Overall Survival Results of KEYNOTE-826. J Clin Oncol 2023;41:5505–5511. Available at: https://www.ncbi.nlm.nih.gov/pubmed/37910822.

288. Minion LE, Tewari KS. Cervical cancer - State of the science: From angiogenesis blockade to checkpoint inhibition. Gynecol Oncol 2018;148:609–621. Available at: https://www.ncbi.nlm.nih.gov/pubmed/29666026.

Version 2.2026 © 2025 National Comprehensive Cancer Network® (NCCN®), All rights reserved. NCCN Guidelines®, and this illustration may not be reproduced in any form without the express written permission of NCCN.

PLEASE NOTE that use of this NCCN Content is governed by the End-User License Agreement, and you MAY NOT distribute this Content or use it with any artificial intelligence model or tool.
Printed by Galya Basol Kochav on 12/29/2025 12:47:39 PM. Copyright © 2025 National Comprehensive Cancer Network, Inc. All Rights Reserved.

289. Tewari KS, Sill MW, Penson RT, et al. Bevacizumab for advanced cervical cancer: final overall survival and adverse event analysis of a randomised, controlled, open-label, phase 3 trial (Gynecologic Oncology Group 240). Lancet 2017;390:1654–1663. Available at: https://www.ncbi.nlm.nih.gov/pubmed/28756902.

290. Penson RT, Huang HQ, Wenzel LB, et al. Bevacizumab for advanced cervical cancer: patient-reported outcomes of a randomised, phase 3 trial (NRG Oncology-Gynecologic Oncology Group protocol 240). Lancet Oncol 2015;16:301–311. Available at: https://www.ncbi.nlm.nih.gov/pubmed/25638326.

291. Rosen VM, Guerra I, McCormack M, et al. Systematic Review and Network Meta-Analysis of Bevacizumab Plus First-Line Topotecan-Paclitaxel or Cisplatin-Paclitaxel Versus Non-Bevacizumab-Containing Therapies in Persistent, Recurrent, or Metastatic Cervical Cancer. Int J Gynecol Cancer 2017;27:1237–1246. Available at: https://www.ncbi.nlm.nih.gov/pubmed/28448304.

292. Kitagawa R, Katsumata N, Shibata T, et al. Paclitaxel Plus Carboplatin Versus Paclitaxel Plus Cisplatin in Metastatic or Recurrent Cervical Cancer: The Open-Label Randomized Phase III Trial JCOG0505. J Clin Oncol 2015;33:2129–2135. Available at: https://www.ncbi.nlm.nih.gov/pubmed/25732161.

293. Oaknin A, Gladieff L, Martinez-Garcia J, et al. Atezolizumab plus bevacizumab and chemotherapy for metastatic, persistent, or recurrent cervical cancer (BEATcc): a randomised, open-label, phase 3 trial. Lancet 2024;403:31–43. Available at: https://www.ncbi.nlm.nih.gov/pubmed/38048793.

294. De Giorgi U, Mansi L, Martinez-Garcia J, et al. 10O Efficacy according to PD-L1 status in the BEATcc (ENGOT-Cx10/GEICO 68-C/JGOG1084/GOG-3030) randomised phase III trial of first-line atezolizumab (atezo), chemotherapy (CT) and bevacizumab (bev) for metastatic, persistent or recurrent cervical cancer (R/M CC). ESMO Open 2025;10. Available at: https://doi.org/10.1016/j.esmoop.2025.105140.

295. Thigpen T, Shingleton H, Homesley H, et al. Cis-platinum in treatment of advanced or recurrent squamous cell carcinoma of the cervix: a phase II study of the Gynecologic Oncology Group. Cancer 1981;48:899–903. Available at: https://www.ncbi.nlm.nih.gov/pubmed/7196794.

296. Thigpen JT, Blessing JA, DiSaia PJ, et al. A randomized comparison of a rapid versus prolonged (24 hr) infusion of cisplatin in therapy of squamous cell carcinoma of the uterine cervix: a Gynecologic Oncology Group study. Gynecol Oncol 1989;32:198–202. Available at: https://www.ncbi.nlm.nih.gov/pubmed/2910782.

297. Pectasides D, Kamposioras K, Papaxoinis G, Pectasides E. Chemotherapy for recurrent cervical cancer. Cancer Treat Rev 2008;34:603–613. Available at: https://www.ncbi.nlm.nih.gov/pubmed/18657909.

298. McGuire WP, 3rd, Arseneau J, Blessing JA, et al. A randomized comparative trial of carboplatin and iproplatin in advanced squamous carcinoma of the uterine cervix: a Gynecologic Oncology Group study. J Clin Oncol 1989;7:1462–1468. Available at: https://www.ncbi.nlm.nih.gov/pubmed/2674333.

299. Weiss GR, Green S, Hannigan EV, et al. A phase II trial of carboplatin for recurrent or metastatic squamous carcinoma of the uterine cervix: a Southwest Oncology Group study. Gynecol Oncol 1990;39:332–336. Available at: https://www.ncbi.nlm.nih.gov/pubmed/2258080.

300. Kudelka AP, Winn R, Edwards CL, et al. An update of a phase II study of paclitaxel in advanced or recurrent squamous cell cancer of the cervix. Anticancer Drugs 1997;8:657–661. Available at: https://www.ncbi.nlm.nih.gov/pubmed/9311440.

301. McGuire WP, Blessing JA, Moore D, et al. Paclitaxel has moderate activity in squamous cervix cancer. A Gynecologic Oncology Group study. J Clin Oncol 1996;14:792–795. Available at: https://www.ncbi.nlm.nih.gov/pubmed/8622025.

302. Tinker AV, Bhagat K, Swenerton KD, Hoskins PJ. Carboplatin and paclitaxel for advanced and recurrent cervical carcinoma: the British

Version 2.2026 © 2025 National Comprehensive Cancer Network® (NCCN®), All rights reserved. NCCN Guidelines®, and this illustration may not be reproduced in any form without the express written permission of NCCN.

PLEASE NOTE that use of this NCCN Content is governed by the End-User License Agreement, and you MAY NOT distribute this Content or use it with any artificial intelligence model or tool.
Printed by Galya Basol Kochav on 12/29/2025 12:47:39 PM. Copyright © 2025 National Comprehensive Cancer Network, Inc. All Rights Reserved.

Columbia Cancer Agency experience. Gynecol Oncol 2005;98:54–58. Available at: https://www.ncbi.nlm.nih.gov/pubmed/15904950.

303. Moore KN, Herzog TJ, Lewin S, et al. A comparison of cisplatin/paclitaxel and carboplatin/paclitaxel in stage IVB, recurrent or persistent cervical cancer. Gynecol Oncol 2007;105:299–303. Available at: https://www.ncbi.nlm.nih.gov/pubmed/17303230.

304. Lorusso D, Petrelli F, Coinu A, et al. A systematic review comparing cisplatin and carboplatin plus paclitaxel-based chemotherapy for recurrent or metastatic cervical cancer. Gynecol Oncol 2014;133:117–123. Available at: https://www.ncbi.nlm.nih.gov/pubmed/24486604.

305. Moore DH. Chemotherapy for advanced, recurrent, and metastatic cervical cancer. J Natl Compr Canc Netw 2008;6:53–57. Available at: https://www.ncbi.nlm.nih.gov/pubmed/18267059.

306. Tao X, Hu W, Ramirez PT, Kavanagh JJ. Chemotherapy for recurrent and metastatic cervical cancer. Gynecol Oncol 2008;110:S67–71. Available at: https://www.ncbi.nlm.nih.gov/pubmed/18533239.

307. Monk BJ, Sill MW, McMeekin DS, et al. Phase III trial of four cisplatin-containing doublet combinations in stage IVB, recurrent, or persistent cervical carcinoma: a Gynecologic Oncology Group study. J Clin Oncol 2009;27:4649–4655. Available at: https://www.ncbi.nlm.nih.gov/pubmed/19720909.

308. Zighelboim I, Wright JD, Gao F, et al. Multicenter phase II trial of topotecan, cisplatin and bevacizumab for recurrent or persistent cervical cancer. Gynecol Oncol 2013;130:64–68. Available at: https://www.ncbi.nlm.nih.gov/pubmed/23591400.

309. Leath CA, 3rd, Straughn JM, Jr. Chemotherapy for advanced and recurrent cervical carcinoma: results from cooperative group trials. Gynecol Oncol 2013;129:251–257. Available at: https://www.ncbi.nlm.nih.gov/pubmed/23280089.

310. Porras GOR, Nogueda JC, Chacón AP. Chemotherapy and molecular therapy in cervical cancer. Reports of Practical Oncology and Radiotherapy 2018;23:533–539. Available at:

311. Boussios S, Seraj E, Zarkavelis G, et al. Management of patients with recurrent/advanced cervical cancer beyond first line platinum regimens: Where do we stand? A literature review. Crit Rev Oncol Hematol 2016;108:164–174. Available at: https://www.ncbi.nlm.nih.gov/pubmed/27931835.

312. Frenel JS, Le Tourneau C, O'Neil B, et al. Safety and Efficacy of Pembrolizumab in Advanced, Programmed Death Ligand 1-Positive Cervical Cancer: Results From the Phase Ib KEYNOTE-028 Trial. J Clin Oncol 2017;35:4035–4041. Available at: https://www.ncbi.nlm.nih.gov/pubmed/29095678.

313. Maio M, Ascierto PA, Manzyuk L, et al. Pembrolizumab in microsatellite instability high or mismatch repair deficient cancers: updated analysis from the phase II KEYNOTE-158 study. Ann Oncol 2022;33:929–938. Available at: https://www.ncbi.nlm.nih.gov/pubmed/35680043.

314. Cocco E, Varughese J, Buza N, et al. Expression of tissue factor in adenocarcinoma and squamous cell carcinoma of the uterine cervix: implications for immunotherapy with hI-con1, a factor VII-IgGFc chimeric protein targeting tissue factor. BMC Cancer 2011;11:263. Available at: https://www.ncbi.nlm.nih.gov/pubmed/21693061.

315. de Bono JS, Concin N, Hong DS, et al. Tisotumab vedotin in patients with advanced or metastatic solid tumours (InnovaTV 201): a first-in-human, multicentre, phase 1-2 trial. Lancet Oncol 2019;20:383–393. Available at: https://www.ncbi.nlm.nih.gov/pubmed/30745090.

316. Hong DS, Concin N, Vergote I, et al. Tisotumab Vedotin in Previously Treated Recurrent or Metastatic Cervical Cancer. Clin Cancer Res 2020;26:1220–1228. Available at: https://www.ncbi.nlm.nih.gov/pubmed/31796521.

317. Coleman RL, Lorusso D, Gennigens C, et al. Efficacy and safety of tisotumab vedotin in previously treated recurrent or metastatic cervical cancer (innovaTV 204/GOG-3023/ENGOT-cx6): a multicentre, open-label, single-arm, phase 2 study. Lancet Oncol 2021;22:609–619. Available at: https://www.ncbi.nlm.nih.gov/pubmed/33845034.

Version 2.2026 © 2025 National Comprehensive Cancer Network® (NCCN®), All rights reserved. NCCN Guidelines®, and this illustration may not be reproduced in any form without the express written permission of NCCN.

PLEASE NOTE that use of this NCCN Content is governed by the End-User License Agreement, and you MAY NOT distribute this Content or use it with any artificial intelligence model or tool.
Printed by Galya Basol Kochav on 12/29/2025 12:47:39 PM. Copyright © 2025 National Comprehensive Cancer Network, Inc. All Rights Reserved.

318. Markham A. Tisotumab Vedotin: First Approval. Drugs 2021;81:2141–2147. Available at: https://www.ncbi.nlm.nih.gov/pubmed/34748188.

319. Vergote I, Gonzalez-Martin A, Fujiwara K, et al. Tisotumab Vedotin as Second- or Third-Line Therapy for Recurrent Cervical Cancer. N Engl J Med 2024;391:44–55. Available at: https://www.ncbi.nlm.nih.gov/pubmed/38959480.

320. Monk BJ, Sill MW, Burger RA, et al. Phase II trial of bevacizumab in the treatment of persistent or recurrent squamous cell carcinoma of the cervix: a gynecologic oncology group study. J Clin Oncol 2009;27:1069–1074. Available at: https://www.ncbi.nlm.nih.gov/pubmed/19139430.

321. Alberts DS, Blessing JA, Landrum LM, et al. Phase II trial of nab-paclitaxel in the treatment of recurrent or persistent advanced cervix cancer: A gynecologic oncology group study. Gynecol Oncol 2012;127:451–455. Available at: https://www.ncbi.nlm.nih.gov/pubmed/22986144.

322. Garcia AA, Blessing JA, Vaccarello L, et al. Phase II clinical trial of docetaxel in refractory squamous cell carcinoma of the cervix: a Gynecologic Oncology Group Study. Am J Clin Oncol 2007;30:428–431. Available at: https://www.ncbi.nlm.nih.gov/pubmed/17762444.

323. Look KY, Blessing JA, Gallup DG, Lentz SS. A phase II trial of 5-fluorouracil and high-dose leucovorin in patients with recurrent squamous cell carcinoma of the cervix: a Gynecologic Oncology Group study. Am J Clin Oncol 1996;19:439–441. Available at: https://www.ncbi.nlm.nih.gov/pubmed/8823469.

324. Schilder RJ, Blessing J, Cohn DE. Evaluation of gemcitabine in previously treated patients with non-squamous cell carcinoma of the cervix: a phase II study of the Gynecologic Oncology Group. Gynecol Oncol 2005;96:103–107. Available at: https://www.ncbi.nlm.nih.gov/pubmed/15589587.

325. Coleman RE, Harper PG, Gallagher C, et al. A phase II study of ifosfamide in advanced and relapsed carcinoma of the cervix. Cancer Chemother Pharmacol 1986;18:280–283. Available at: https://www.ncbi.nlm.nih.gov/pubmed/3802384.

326. Sutton GP, Blessing JA, McGuire WP, et al. Phase II trial of ifosfamide and mesna in patients with advanced or recurrent squamous carcinoma of the cervix who had never received chemotherapy: a Gynecologic Oncology Group study. Am J Obstet Gynecol 1993;168:805–807. Available at: https://www.ncbi.nlm.nih.gov/pubmed/8456884.

327. Verschraegen CF, Levy T, Kudelka AP, et al. Phase II study of irinotecan in prior chemotherapy-treated squamous cell carcinoma of the cervix. J Clin Oncol 1997;15:625–631. Available at: https://www.ncbi.nlm.nih.gov/pubmed/9053486.

328. Wagenaar HC, Pecorelli S, Mangioni C, et al. Phase II study of mitomycin-C and cisplatin in disseminated, squamous cell carcinoma of the uterine cervix. A European Organization for Research and Treatment of Cancer (EORTC) Gynecological Cancer Group study. Eur J Cancer 2001;37:1624–1628. Available at: https://www.ncbi.nlm.nih.gov/pubmed/11527687.

329. Miller DS, Blessing JA, Bodurka DC, et al. Evaluation of pemetrexed (Alimta, LY231514) as second line chemotherapy in persistent or recurrent carcinoma of the cervix: a phase II study of the Gynecologic Oncology Group. Gynecol Oncol 2008;110:65–70. Available at: https://www.ncbi.nlm.nih.gov/pubmed/18455781.

330. Bookman MA, Blessing JA, Hanjani P, et al. Topotecan in squamous cell carcinoma of the cervix: A Phase II study of the Gynecologic Oncology Group. Gynecol Oncol 2000;77:446–449. Available at: https://www.ncbi.nlm.nih.gov/pubmed/10831357.

331. Muderspach LI, Blessing JA, Levenback C, Moore JL, Jr. A Phase II study of topotecan in patients with squamous cell carcinoma of the cervix: a gynecologic oncology group study. Gynecol Oncol 2001;81:213–215. Available at: https://www.ncbi.nlm.nih.gov/pubmed/11354055.

332. Muggia FM, Blessing JA, Method M, et al. Evaluation of vinorelbine in persistent or recurrent squamous cell carcinoma of the cervix: a

Version 2.2026 © 2025 National Comprehensive Cancer Network® (NCCN®), All rights reserved. NCCN Guidelines®, and this illustration may not be reproduced in any form without the express written permission of NCCN.

PLEASE NOTE that use of this NCCN Content is governed by the End-User License Agreement, and you MAY NOT distribute this Content or use it with any artificial intelligence model or tool.
Printed by Galya Basol Kochav on 12/29/2025 12:47:39 PM. Copyright © 2025 National Comprehensive Cancer Network, Inc. All Rights Reserved.

Gynecologic Oncology Group study. Gynecol Oncol 2004;92:639–643. Available at: https://www.ncbi.nlm.nih.gov/pubmed/14766259.

333. Tewari KS, Monk BJ, Vergote I, et al. Survival with Cemiplimab in Recurrent Cervical Cancer. N Engl J Med 2022;386:544–555. Available at: https://www.ncbi.nlm.nih.gov/pubmed/35139273.

334. Oaknin A, Monk BJ, de Melo AC, et al. Cemiplimab in recurrent cervical cancer: Final analysis of overall survival in the phase III EMPOWER-Cervical 1/GOG-3016/ENGOT-cx9 trial. Eur J Cancer 2025;216:115146. Available at: https://www.ncbi.nlm.nih.gov/pubmed/39798514.

335. Oaknin A, Moore K, Meyer T, et al. Nivolumab with or without ipilimumab in patients with recurrent or metastatic cervical cancer (CheckMate 358): a phase 1-2, open-label, multicohort trial. Lancet Oncol 2024;25:588–602. Available at: https://www.ncbi.nlm.nih.gov/pubmed/38608691.

336. Chino J, Annunziata CM, Beriwal S, et al. Radiation Therapy for Cervical Cancer: Executive Summary of an ASTRO Clinical Practice Guideline. Pract Radiat Oncol 2020;10:220–234. Available at: https://www.ncbi.nlm.nih.gov/pubmed/32473857.

337. Herrera FG, Prior JO. The role of PET/CT in cervical cancer. Front Oncol 2013;3:34. Available at: https://www.ncbi.nlm.nih.gov/pubmed/23549376.

338. Higginson DS, Morris DE, Jones EL, et al. Stereotactic body radiotherapy (SBRT): Technological innovation and application in gynecologic oncology. Gynecol Oncol 2011;120:404–412. Available at: https://www.ncbi.nlm.nih.gov/pubmed/21194733.

339. Jadon R, Pembroke CA, Hanna CL, et al. A systematic review of organ motion and image-guided strategies in external beam radiotherapy for cervical cancer. Clin Oncol (R Coll Radiol) 2014;26:185–196. Available at: https://www.ncbi.nlm.nih.gov/pubmed/24566332.

340. Eminowicz G, Hall-Craggs M, Diez P, McCormack M. Improving target volume delineation in intact cervical carcinoma: Literature review and step-by-step pictorial atlas to aid contouring. Pract Radiat Oncol 2016;6:e203–e213. Available at: https://www.ncbi.nlm.nih.gov/pubmed/27032573.

341. Klopp AH, Yeung AR, Deshmukh S, et al. A Phase III Randomized Trial Comparing Patient-Reported Toxicity and Quality of Life (QOL) During Pelvic Intensity Modulated Radiation Therapy as Compared to Conventional Radiation Therapy. International Journal of Radiation Oncology*Biology*Physics 2016;96:S3. Available at: https://www.ncbi.nlm.nih.gov/pubmed/27675895.

342. Hallock A, Surry K, Batchelar D, et al. An early report on outcomes from computed tomographic-based high-dose-rate brachytherapy for locally advanced cervix cancer: A single institution experience. Pract Radiat Oncol 2011;1:173–181. Available at: https://www.ncbi.nlm.nih.gov/pubmed/24673947.

343. Ferrigno R, Nishimoto IN, Novaes PE, et al. Comparison of low and high dose rate brachytherapy in the treatment of uterine cervix cancer. Retrospective analysis of two sequential series. Int J Radiat Oncol Biol Phys 2005;62:1108–1116. Available at: https://www.ncbi.nlm.nih.gov/pubmed/15990016.

344. Potter R, Tanderup K, Schmid MP, et al. MRI-guided adaptive brachytherapy in locally advanced cervical cancer (EMBRACE-I): a multicentre prospective cohort study. Lancet Oncol 2021;22:538–547. Available at: https://www.ncbi.nlm.nih.gov/pubmed/33794207.

345. Petric P, Lindegaard JC, Sturdza A, et al. Results of image guided brachytherapy for stage IB cervical cancer in the RetroEMBRACE study. Radiother Oncol 2021;157:24–31. Available at: https://www.ncbi.nlm.nih.gov/pubmed/33476724.

346. Potter R, Georg P, Dimopoulos JC, et al. Clinical outcome of protocol based image (MRI) guided adaptive brachytherapy combined with 3D conformal radiotherapy with or without chemotherapy in patients with locally advanced cervical cancer. Radiother Oncol 2011;100:116–123. Available at: https://www.ncbi.nlm.nih.gov/pubmed/21821305.

Version 2.2026 © 2025 National Comprehensive Cancer Network® (NCCN®), All rights reserved. NCCN Guidelines®, and this illustration may not be reproduced in any form without the express written permission of NCCN.

PLEASE NOTE that use of this NCCN Content is governed by the End-User License Agreement, and you MAY NOT distribute this Content or use it with any artificial intelligence model or tool.
Printed by Galya Basol Kochav on 12/29/2025 12:47:39 PM. Copyright © 2025 National Comprehensive Cancer Network, Inc. All Rights Reserved.

347. Haie-Meder C, Potter R, Van Limbergen E, et al. Recommendations from Gynaecological (GYN) GEC-ESTRO Working Group (I): concepts and terms in 3D image based 3D treatment planning in cervix cancer brachytherapy with emphasis on MRI assessment of GTV and CTV. Radiother Oncol 2005;74:235–245. Available at: https://www.ncbi.nlm.nih.gov/pubmed/15763303.

348. Yoshida K, Jastaniyah N, Sturdza A, et al. Assessment of Parametrial Response by Growth Pattern in Patients With International Federation of Gynecology and Obstetrics Stage IIB and IIIB Cervical Cancer: Analysis of Patients From a Prospective, Multicenter Trial (EMBRACE). Int J Radiat Oncol Biol Phys 2015;93:788–796. Available at: https://www.ncbi.nlm.nih.gov/pubmed/26530747.

349. Viswanathan AN, Erickson BA. Three-dimensional imaging in gynecologic brachytherapy: a survey of the American Brachytherapy Society. Int J Radiat Oncol Biol Phys 2010;76:104–109. Available at: https://www.ncbi.nlm.nih.gov/pubmed/19619956.

350. Erickson B, Eifel P, Moughan J, et al. Patterns of brachytherapy practice for patients with carcinoma of the cervix (1996-1999): a patterns of care study. Int J Radiat Oncol Biol Phys 2005;63:1083–1092. Available at: https://www.ncbi.nlm.nih.gov/pubmed/16099599.

351. Potter R, Tanderup K, Kirisits C, et al. The EMBRACE II study: The outcome and prospect of two decades of evolution within the GEC-ESTRO GYN working group and the EMBRACE studies. Clin Transl Radiat Oncol 2018;9:48–60. Available at: https://www.ncbi.nlm.nih.gov/pubmed/29594251.

352. Berger T, Seppenwoolde Y, Potter R, et al. Importance of Technique, Target Selection, Contouring, Dose Prescription, and Dose-Planning in External Beam Radiation Therapy for Cervical Cancer: Evolution of Practice From EMBRACE-I to II. Int J Radiat Oncol Biol Phys 2019;104:885–894. Available at: https://www.ncbi.nlm.nih.gov/pubmed/30904706.

353. Erickson-Whitmann B, Rownd J, Khater K. Biologic and physical aspects of radiation oncology. In: Barakat R, Markman M, Randall M, eds. Principles and Practice of Gynecology Oncology, 5th ed. Philadelphia: Lippincott Williams & Wilkins; 2009:325–380.

354. Lim K, Small W, Jr., Portelance L, et al. Consensus guidelines for delineation of clinical target volume for intensity-modulated pelvic radiotherapy for the definitive treatment of cervix cancer. Int J Radiat Oncol Biol Phys 2011;79:348–355. Available at: https://www.ncbi.nlm.nih.gov/pubmed/20472347.

355. Loiselle C, Koh WJ. The emerging use of IMRT for treatment of cervical cancer. J Natl Compr Canc Netw 2010;8:1425–1434. Available at: https://www.ncbi.nlm.nih.gov/pubmed/21147905.

356. Beriwal S, Gan GN, Heron DE, et al. Early clinical outcome with concurrent chemotherapy and extended-field, intensity-modulated radiotherapy for cervical cancer. Int J Radiat Oncol Biol Phys 2007;68:166–171. Available at: https://www.ncbi.nlm.nih.gov/pubmed/17321070.

357. Chen MF, Tseng CJ, Tseng CC, et al. Clinical outcome in posthysterectomy cervical cancer patients treated with concurrent Cisplatin and intensity-modulated pelvic radiotherapy: comparison with conventional radiotherapy. Int J Radiat Oncol Biol Phys 2007;67:1438–1444. Available at: https://www.ncbi.nlm.nih.gov/pubmed/17394944.

358. Chen MF, Tseng CJ, Tseng CC, et al. Adjuvant concurrent chemoradiotherapy with intensity-modulated pelvic radiotherapy after surgery for high-risk, early stage cervical cancer patients. Cancer J 2008;14:200–206. Available at: https://www.ncbi.nlm.nih.gov/pubmed/18536561.

359. Salama JK, Mundt AJ, Roeske J, Mehta N. Preliminary outcome and toxicity report of extended-field, intensity-modulated radiation therapy for gynecologic malignancies. Int J Radiat Oncol Biol Phys 2006;65:1170–1176. Available at: https://www.ncbi.nlm.nih.gov/pubmed/16730136.

360. Small W, Jr., Mell LK, Anderson P, et al. Consensus guidelines for delineation of clinical target volume for intensity-modulated pelvic radiotherapy in postoperative treatment of endometrial and cervical

Version 2.2026 © 2025 National Comprehensive Cancer Network® (NCCN®), All rights reserved. NCCN Guidelines®, and this illustration may not be reproduced in any form without the express written permission of NCCN.

PLEASE NOTE that use of this NCCN Content is governed by the End-User License Agreement, and you MAY NOT distribute this Content or use it with any artificial intelligence model or tool.
Printed by Galya Basol Kochav on 12/29/2025 12:47:39 PM. Copyright © 2025 National Comprehensive Cancer Network, Inc. All Rights Reserved.

cancer. Int J Radiat Oncol Biol Phys 2008;71:428–434. Available at: https://www.ncbi.nlm.nih.gov/pubmed/18037584.

361. Erpolat OP, Alco G, Caglar HB, et al. Comparison of hematologic toxicity between 3DCRT and IMRT planning in cervical cancer patients after concurrent chemoradiotherapy: a national multi-center study. Eur J Gynaecol Oncol 2014;35:62–66. Available at: https://www.ncbi.nlm.nih.gov/pubmed/24654465.

362. Klopp AH, Moughan J, Portelance L, et al. Hematologic toxicity in RTOG 0418: a phase 2 study of postoperative IMRT for gynecologic cancer. Int J Radiat Oncol Biol Phys 2013;86:83–90. Available at: https://www.ncbi.nlm.nih.gov/pubmed/23582248.

363. Klopp AH, Yeung AR, Deshmukh S, et al. Patient-Reported Toxicity During Pelvic Intensity-Modulated Radiation Therapy: NRG Oncology-RTOG 1203. J Clin Oncol 2018;36:2538–2544. Available at: https://www.ncbi.nlm.nih.gov/pubmed/29989857.

364. Verma J, Sulman EP, Jhingran A, et al. Dosimetric predictors of duodenal toxicity after intensity modulated radiation therapy for treatment of the para-aortic nodes in gynecologic cancer. Int J Radiat Oncol Biol Phys 2014;88:357–362. Available at: https://www.ncbi.nlm.nih.gov/pubmed/24411609.

365. Mell LK, Sirak I, Wei L, et al. Bone Marrow-sparing Intensity Modulated Radiation Therapy With Concurrent Cisplatin For Stage IB-IVA Cervical Cancer: An International Multicenter Phase II Clinical Trial (INTERTECC-2). Int J Radiat Oncol Biol Phys 2017;97:536–545. Available at: https://www.ncbi.nlm.nih.gov/pubmed/28126303.

366. Fyles A, Keane TJ, Barton M, Simm J. The effect of treatment duration in the local control of cervix cancer. Radiother Oncol 1992;25:273–279. Available at: https://www.ncbi.nlm.nih.gov/pubmed/1480773.

367. Girinsky T, Rey A, Roche B, et al. Overall treatment time in advanced cervical carcinomas: a critical parameter in treatment outcome. Int J Radiat Oncol Biol Phys 1993;27:1051–1056. Available at: https://www.ncbi.nlm.nih.gov/pubmed/8262826.

368. Lanciano RM, Pajak TF, Martz K, Hanks GE. The influence of treatment time on outcome for squamous cell cancer of the uterine cervix treated with radiation: a patterns-of-care study. Int J Radiat Oncol Biol Phys 1993;25:391–397. Available at: https://www.ncbi.nlm.nih.gov/pubmed/8436516.

369. Perez CA, Grigsby PW, Castro-Vita H, Lockett MA. Carcinoma of the uterine cervix. I. Impact of prolongation of overall treatment time and timing of brachytherapy on outcome of radiation therapy. Int J Radiat Oncol Biol Phys 1995;32:1275–1288. Available at: https://www.ncbi.nlm.nih.gov/pubmed/7635767.

370. Petereit DG, Sarkaria JN, Chappell R, et al. The adverse effect of treatment prolongation in cervical carcinoma. Int J Radiat Oncol Biol Phys 1995;32:1301–1307. Available at: https://www.ncbi.nlm.nih.gov/pubmed/7635769.

371. Ren X, Fu Y, Liu Z, et al. Image-guided interstitial brachytherapy for recurrent cervical cancer after radiotherapy: A single institution experience. Front Oncol 2022;12:943703. Available at: https://www.ncbi.nlm.nih.gov/pubmed/35928866.

372. Macchia G, Pezzulla D, Cilla S, et al. Stereotactic Body Reirradiation in Gynaecological Cancer: Outcomes and Toxicities from a Single Institution Experience. Clin Oncol (R Coll Radiol) 2023;35:682–693. Available at: https://www.ncbi.nlm.nih.gov/pubmed/37558548.

373. Kim HJ, Chang JS, Koom WS, et al. Radiotherapy is a safe and effective salvage treatment for recurrent cervical cancer. Gynecol Oncol 2018;151:208–214. Available at: https://www.ncbi.nlm.nih.gov/pubmed/30195468.

374. Eifel PJ, Levenback C, Wharton JT, Oswald MJ. Time course and incidence of late complications in patients treated with radiation therapy for FIGO stage IB carcinoma of the uterine cervix. Int J Radiat Oncol Biol Phys 1995;32:1289–1300. Available at: https://www.ncbi.nlm.nih.gov/pubmed/7635768.

375. Forrest JL, Ackerman I, Barbera L, et al. Patient outcome study of concurrent chemoradiation, external beam radiotherapy, and high-dose

Version 2.2026 © 2025 National Comprehensive Cancer Network® (NCCN®), All rights reserved. NCCN Guidelines®, and this illustration may not be reproduced in any form without the express written permission of NCCN.

PLEASE NOTE that use of this NCCN Content is governed by the End-User License Agreement, and you MAY NOT distribute this Content or use it with any artificial intelligence model or tool.
Printed by Galya Basol Kochav on 12/29/2025 12:47:39 PM. Copyright © 2025 National Comprehensive Cancer Network, Inc. All Rights Reserved.

rate brachytherapy in locally advanced carcinoma of the cervix. Int J Gynecol Cancer 2010;20:1074–1078. Available at: https://www.ncbi.nlm.nih.gov/pubmed/20683420.

376. Perez CA, Grigsby PW, Lockett MA, et al. Radiation therapy morbidity in carcinoma of the uterine cervix: dosimetric and clinical correlation. Int J Radiat Oncol Biol Phys 1999;44:855–866. Available at: https://www.ncbi.nlm.nih.gov/pubmed/10386643.

377. Kloppel G. Neuroendocrine Neoplasms: Dichotomy, Origin and Classifications. Visc Med 2017;33:324–330. Available at: https://www.ncbi.nlm.nih.gov/pubmed/29177160.

378. Rindi G, Klimstra DS, Abedi-Ardekani B, et al. A common classification framework for neuroendocrine neoplasms: an International Agency for Research on Cancer (IARC) and World Health Organization (WHO) expert consensus proposal. Mod Pathol 2018;31:1770–1786. Available at: https://www.ncbi.nlm.nih.gov/pubmed/30140036.

379. Tempfer CB, Tischoff I, Dogan A, et al. Neuroendocrine carcinoma of the cervix: a systematic review of the literature. BMC Cancer 2018;18:530. Available at: https://www.ncbi.nlm.nih.gov/pubmed/29728073.

380. Abu-Rustum NR. Management of Recurrent or Metastatic Cervical Cancer. Journal of the National Comprehensive Cancer Network 2023;21:576–578. Available at: https://jnccn.org/view/journals/jnccn/21/5.5/article-p576.xml.

381. Gordhandas S, Schlappe BA, Zhou Q, et al. Small cell neuroendocrine carcinoma of the cervix: Analysis of prognostic factors and patterns of metastasis. Gynecol Oncol Rep 2022;43:101058. Available at: https://www.ncbi.nlm.nih.gov/pubmed/35967833.

382. Stoler MH, Mills SE, Gersell DJ, Walker AN. Small-cell neuroendocrine carcinoma of the cervix. A human papillomavirus type 18-associated cancer. Am J Surg Pathol 1991;15:28–32. Available at: https://www.ncbi.nlm.nih.gov/pubmed/1845923.

383. Wang HL, Lu DW. Detection of human papillomavirus DNA and expression of p16, Rb, and p53 proteins in small cell carcinomas of the uterine cervix. Am J Surg Pathol 2004;28:901–908. Available at: https://www.ncbi.nlm.nih.gov/pubmed/15223960.

384. Masumoto N, Fujii T, Ishikawa M, et al. P16 overexpression and human papillomavirus infection in small cell carcinoma of the uterine cervix. Hum Pathol 2003;34:778–783. Available at: https://www.ncbi.nlm.nih.gov/pubmed/14506638.

385. Miyoshi AI, Ueda Y, Kurita T, et al. Recent Advances in the Management of Small Cell Carcinoma of the Uterine Cervix. Anticancer Res 2023;43:1397–1405. Available at: https://www.ncbi.nlm.nih.gov/pubmed/36974776.

386. Horn L, Mansfield AS, Szczesna A, et al. First-Line Atezolizumab plus Chemotherapy in Extensive-Stage Small-Cell Lung Cancer. N Engl J Med 2018;379:2220–2229. Available at: https://www.ncbi.nlm.nih.gov/pubmed/30280641.

387. Paz-Ares L, Dvorkin M, Chen Y, et al. Durvalumab plus platinum-etoposide versus platinum-etoposide in first-line treatment of extensive-stage small-cell lung cancer (CASPIAN): a randomised, controlled, open-label, phase 3 trial. Lancet 2019;394:1929–1939. Available at: https://www.ncbi.nlm.nih.gov/pubmed/31590988.

388. Burotto M, Zvirbule Z, Mochalova A, et al. IMscin001 Part 2: a randomised phase III, open-label, multicentre study examining the pharmacokinetics, efficacy, immunogenicity, and safety of atezolizumab subcutaneous versus intravenous administration in previously treated locally advanced or metastatic non-small-cell lung cancer and pharmacokinetics comparison with other approved indications. Ann Oncol 2023;34:693–702. Available at: https://www.ncbi.nlm.nih.gov/pubmed/37268157.

389. Frumovitz M, Munsell MF, Burzawa JK, et al. Combination therapy with topotecan, paclitaxel, and bevacizumab improves progression-free survival in recurrent small cell neuroendocrine carcinoma of the cervix. Gynecol Oncol 2017;144:46–50. Available at: https://www.ncbi.nlm.nih.gov/pubmed/27823771.

Version 2.2026 © 2025 National Comprehensive Cancer Network® (NCCN®), All rights reserved. NCCN Guidelines®, and this illustration may not be reproduced in any form without the express written permission of NCCN.

PLEASE NOTE that use of this NCCN Content is governed by the End-User License Agreement, and you MAY NOT distribute this Content or use it with any artificial intelligence model or tool.
Printed by Galya Basol Kochav on 12/29/2025 12:47:39 PM. Copyright © 2025 National Comprehensive Cancer Network, Inc. All Rights Reserved.

390. Towner M, Novak K, Chae YK, Matei D. Ipilimumab and nivolumab for recurrent neuroendocrine cervical carcinoma. Gynecol Oncol Rep 2022;42:101039. Available at: https://www.ncbi.nlm.nih.gov/pubmed/35846558.

391. Van Calsteren K, Heyns L, De Smet F, et al. Cancer during pregnancy: an analysis of 215 patients emphasizing the obstetrical and the neonatal outcomes. J Clin Oncol 2010;28:683–689. Available at: https://www.ncbi.nlm.nih.gov/pubmed/19841323.

392. Fukushima K, Ogawa S, Tsukimori K, et al. Can we diagnose invasive cervical cancer during pregnancy as precise as in nonpregnant women?: maternal and perinatal outcome in pregnancies complicated with cervical cancers. Int J Gynecol Cancer 2009;19:1439–1445. Available at: https://www.ncbi.nlm.nih.gov/pubmed/20009904.

393. Smith LH, Danielsen B, Allen ME, Cress R. Cancer associated with obstetric delivery: results of linkage with the California cancer registry. Am J Obstet Gynecol 2003;189:1128–1135. Available at: https://www.ncbi.nlm.nih.gov/pubmed/14586366.

394. Swenson RE, Goff BA, Koh W-J, et al. Cancer in the pregnant patient. In: Hoskins WJ, Perez CA, Young RC, eds. Principles and Practice of Gynecologic Oncology, 4th ed. Philadelphia: Lippincott Williams & Wilkins; 2004 1279–1311.

395. Sadler L, Sykes P. How little is known about cervical cancer in pregnancy? Ann Oncol 2005;16:341–343. Available at: https://www.ncbi.nlm.nih.gov/pubmed/15722461.

396. Morice P, Narducci F, Mathevet P, et al. French recommendations on the management of invasive cervical cancer during pregnancy. Int J Gynecol Cancer 2009;19:1638–1641. Available at: https://www.ncbi.nlm.nih.gov/pubmed/19955951.

397. Sood AK, Sorosky JI. Invasive cervical cancer complicating pregnancy. How to manage the dilemma. Obstet Gynecol Clin North Am 1998;25:343–352. Available at: https://www.ncbi.nlm.nih.gov/pubmed/9629575.

398. van de Nieuwenhof HP, van Ham MA, Lotgering FK, Massuger LF. First case of vaginal radical trachelectomy in a pregnant patient. Int J Gynecol Cancer 2008;18:1381–1385. Available at: https://www.ncbi.nlm.nih.gov/pubmed/18298565.

399. Ben-Arie A, Levy R, Lavie O, et al. Conservative treatment of stage IA2 squamous cell carcinoma of the cervix during pregnancy. Obstet Gynecol 2004;104:1129–1131. Available at: https://www.ncbi.nlm.nih.gov/pubmed/15516424.

400. Gurney EP, Blank SV. Postpartum radical trachelectomy for IB1 squamous cell carcinoma of the cervix diagnosed in pregnancy. Am J Obstet Gynecol 2009;201:e8–e10. Available at: https://www.ncbi.nlm.nih.gov/pubmed/19695559.

401. Castells MC, Tennant NM, Sloane DE, et al. Hypersensitivity reactions to chemotherapy: outcomes and safety of rapid desensitization in 413 cases. J Allergy Clin Immunol 2008;122:574–580. Available at: https://www.ncbi.nlm.nih.gov/pubmed/18502492.

402. Sampson HA, Munoz-Furlong A, Campbell RL, et al. Second symposium on the definition and management of anaphylaxis: summary report--second National Institute of Allergy and Infectious Disease/Food Allergy and Anaphylaxis Network symposium. Ann Emerg Med 2006;47:373–380. Available at: https://www.ncbi.nlm.nih.gov/pubmed/16546624.

403. Manivannan V, Decker WW, Stead LG, et al. Visual representation of National Institute of Allergy and Infectious Disease and Food Allergy and Anaphylaxis Network criteria for anaphylaxis. Int J Emerg Med 2009;2:3–5. Available at: https://www.ncbi.nlm.nih.gov/pubmed/19390910.

404. Lenz HJ. Management and preparedness for infusion and hypersensitivity reactions. Oncologist 2007;12:601–609. Available at: https://www.ncbi.nlm.nih.gov/pubmed/17522249.

405. Markman M, Zanotti K, Peterson G, et al. Expanded experience with an intradermal skin test to predict for the presence or absence of carboplatin hypersensitivity. J Clin Oncol 2003;21:4611–4614. Available at: https://www.ncbi.nlm.nih.gov/pubmed/14673050.

Version 2.2026 © 2025 National Comprehensive Cancer Network® (NCCN®), All rights reserved. NCCN Guidelines®, and this illustration may not be reproduced in any form without the express written permission of NCCN.

PLEASE NOTE that use of this NCCN Content is governed by the End-User License Agreement, and you MAY NOT distribute this Content or use it with any artificial intelligence model or tool.
Printed by Galya Basol Kochav on 12/29/2025 12:47:39 PM. Copyright © 2025 National Comprehensive Cancer Network, Inc. All Rights Reserved.

406. Lee CW, Matulonis UA, Castells MC. Rapid inpatient/outpatient desensitization for chemotherapy hypersensitivity: standard protocol effective in 57 patients for 255 courses. Gynecol Oncol 2005;99:393–399. Available at: https://www.ncbi.nlm.nih.gov/pubmed/16054201.

407. Lee CW, Matulonis UA, Castells MC. Carboplatin hypersensitivity: a 6-h 12-step protocol effective in 35 desensitizations in patients with gynecological malignancies and mast cell/IgE-mediated reactions. Gynecol Oncol 2004;95:370–376. Available at: https://www.ncbi.nlm.nih.gov/pubmed/15491759.

408. Chan JK, Berek JS. Impact of the human papilloma vaccine on cervical cancer. J Clin Oncol 2007;25:2975–2982. Available at: https://www.ncbi.nlm.nih.gov/pubmed/17617529.

Version 2.2026 © 2025 National Comprehensive Cancer Network® (NCCN®), All rights reserved. NCCN Guidelines®, and this illustration may not be reproduced in any form without the express written permission of NCCN.